

Ankle Arthroscopy versus Conservative Modalities in Management of Ankle Impingement Syndrome: A Systematic Review of Literature

Ahmed Ruby AbdelHamid, Atef Mohamed Fathy El-beltagy,

Ahmed Salem Eid*

Orthopedic Department, Faculty of Medicine, Ain Shams University-Egypt.

*Corresponding author: Ahmed Ruby AbdelHamid. Phone: 00201025156155.Email: ahmad.a.amer101@gmail.com

ABSTRACT

Background: it has been well established that chronic ankle pain negatively affects the lives of patients. Surgical techniques for ankle pain have evolved dramatically over the past decade, as arthroscopic equipment has improved to allow excellent exposure to the ankle joint and surrounding anatomic areas. Soft-tissue and osseous impingement syndromes are now increasingly recognized as a significant cause of chronic ankle pain, The exact cause of this condition is debated but seems to involve osteophyte formation due to either repetitive microtrauma or macrotrauma associated with major injuries. Careful analyses of patient history and signs and symptoms at physical examination can suggest a specific diagnosis in most patients.

Aim of the work: this systematic review aimed to assess the outcome of ankle arthroscopy versus conservative modalities in management of ankle impingement syndrome.

Methods: a systematic literature search of the PubMed, Embase (classic), and Chochrane library databases, for articles that published from January 1990 to June 2017 was performed using the following inclusion criteria English language publications, human clinical trials, studies that reported on at least one of the chosen outcome measures which are patient satisfaction, time to return to full activity, AOFAS score, visual analog scale (VAS) score for pain, and complications, we found 9 studies met our inclusion criteria, data extraction was done which is consisted of population characteristics, in addition to the outcome measures.

Results: nine articles were included in this systematic review. Overall, good results were found for arthroscopic treatment in patients with ankle impingement syndrome, patient satisfaction rates was reported in 5 studies, we reported high percentages of good to excellent satisfaction rates, ranging 74% to 94%, especially in patients treated with arthroscopy, Complication rates were 14.1%, as regard to patients treated with arthroscopy the rate was 13.2%, on the other hand the rate was 17.6% in those patients treated with injection therapy technique, conventional conservative modalities reported to be ineffective in treating ankle impingement except injection therapy technique in case of ankle soft tissue impingement.

Conclusion: our systematic review showed that Patients may respond to conservative treatment modalities, especially ultra-sound guided injection mainly in soft tissue impingement type, arthroscopic debridement is the treatment of choice for patients of ankle impingement syndrome of both osseous and soft tissue nature with least morbidity and early return to function, and also it is noted to be superior to conservative modalities.

Keywords: ankle arthroscopy; Ankle impingement; Bony, Soft tissue impingement; Chronic ankle pain; Sport injury; Os trigonum, Osteophytes; Treatment, Conservative.

INTRODUCTION

Chronic ankle pain is a common clinical problem with a wide differential diagnosis. Soft-tissue and osseous impingement syndromes are now increasingly recognized as a significant cause of chronic ankle pain⁽¹⁾.

The ankle impingement syndromes are defined as pathologic conditions causing painful restriction of movement at the tibiotalar joint caused by osseous or soft tissue overgrowth or by the presence of accessory ossification centers. First described by Morris⁽²⁾ in 1943 and then by McMurray⁽³⁾ in 1950, who termed the condition "footballer's ankle," ankle impingement is now an established cause of ongoing ankle dysfunction, often following seemingly trivial trauma⁽⁴⁾.

Impingement syndromes have been well described in the anterolateral, anterior, and posterior ankle, with more recent orthopedic and radiologic studies describing the less well-recognized entities of anteromedial and posteromedial impingement⁽⁵⁾.

Ankle impingement is a common cause of ankle pain in athletic patients and is frequently associated with sporting activities involving repetitive forced dorsiflexion or plantar flexion of the ankle. The exact cause of this condition is debated but seems to involve osteophyte formation due to either repetitive microtrauma or macrotrauma associated with major injuries⁽⁶⁾.

Posterior impingement is typically a chronic problem of insidious onset affecting athletes who regularly undergo forced plantarflexion especially ballet dancers, jumping athletes, squash and football players. Football players are particularly affected because plantarflexion occurs not only on push off during sprinting and changing direction but also occurs during kicking⁽⁷⁾.

Posterior ankle impingement syndrome is often accompanied by tenosynovitis or degeneration of the flexor hallucis longus (FHL), especially in ballet dancers⁽⁸⁾.

Typically, anterior impingement syndrome presents with anterior ankle pain exacerbated by dorsiflexion. Clinical examination may reveal soft tissue swelling over the anterior aspect of the ankle joint with reduced range of dorsiflexion. Movement limitation can sometimes be overcome by excessive ankle pronation, but this additional abnormality in ankle biomechanics may have further consequences. In some instances the anterior bony spurs may be palpable⁽⁹⁾.

Anterior impingement of the ankle most commonly is caused by osteophyte formation at the anterior rim of the tibia and talar neck. Anterior tibiotalar osteophytes are caused by recurrent microtrauma to the joint capsule and anterior chondral margin of the tibiotalar joint, such as from kicking a soccer ball or forcible dorsiflexion⁽⁶⁾.

Careful analyses of patient history and signs and symptoms at physical examination can suggest a specific diagnosis in most patients. MR imaging and MR arthrography are the most useful imaging methods for detecting the osseous and soft-tissue abnormalities present in these syndromes and for ruling out other potential causes of chronic ankle pain⁽¹⁰⁾.

The radiological assessment includes anteromedial oblique and lateral weight bearing skiagram views. MRI scan can precisely locate the osteophytes, delineate synovial hypertrophy and can additionally detect cartilage erosion and osteochondral defects of talus. Despite a lot of advances, diagnostic arthroscopy still remains the gold standard for assessment of the disease⁽¹¹⁾.

Conservative treatment, consisting of rest, physical therapy, ankle bracing, shoe modification, and/or local injection, is recommended as the primary treatment strategy for symptoms of ankle impingement syndrome⁽¹²⁾.

Arthroscopic debridement has gained popularity and is considered gold standard treatment for virtually all causes of impingement syndrome as it is minimally invasive and

associated with low morbidity and faster recovery times⁽¹³⁾.

MATERIALS AND METHODS

We performed a comprehensive electronic search in PubMed, Embase (classic), and Chochrane library databases, for articles that published between 1990 and 2017 using the following keywords:

Ankle arthroscopy; Ankle impingement; Bony, Soft tissue impingement; Chronic ankle pain; Os trigonum; Treatment, Conservative.

We reviewed all titles, abstracts and the full text of articles that were potentially eligible based on abstract review, then studies selected according to the following inclusion and exclusion criteria.

Inclusion criteria

- Journal articles published in English language.
- In vivo studies.
- Date from 1990 to 2017.
- Clinical trials.
- Studies that reported on at least one of the chosen outcome measures.

Exclusion criteria

- Case report studies.
- Cadaveric or nonhuman studies.
- Non-English language studies.
- Articles describing other joint impingement diseases rather than the ankle joint.
- Studies with no data on outcome measures.
- Presence of any systemic joint disease.

Data extraction

The data extracted included the following items:

Study characteristic; name of the first author, year of publication.

Participant characteristics; number of patients, mean age and gender.

Preoperative diagnosis, detail of intervention.

Follow up.

The resulting outcomes of comparison (outcome measures).

Points of comparison (outcome measures):

- Patient satisfaction.
- The mean time to return to full activity after the procedure.
- American Orthopedic Foot and Ankle Society (AOFAS) score.
- Visual analog scale (VAS) score for pain.
- Complications.

After electronic search on PubMed, Embase (classic) and Cochrane library databases we found 9 studies met our inclusion criteria.

RESULTS

From electronic search, a total of 1324 studies were identified, 743 studies remained after duplicates were removed. Based on titles and abstracts 727 studies were removed. Full text of 16

studies were reviewed, seven of them were excluded because either, other joint impingement, not human study or non-English language.

The total number of patients in nine studies was 325, the combined mean age was 30 years, while that of follow up was 49.6 months, males number was 202 (62%), while that of females was 123 (38%), with male to female ratio 1.6:1.

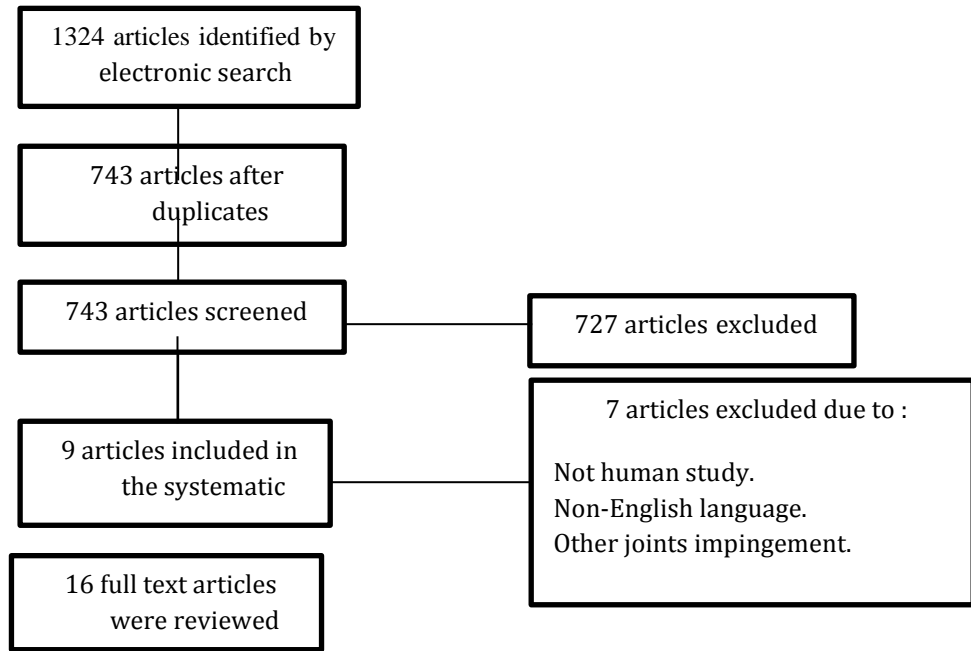


Figure (1): Flow chart of the study selection process.

AOFAS score was reported in 5 studies, the mean preoperative scores ranged between 50.9 and 75 points. Postoperatively, the mean scores ranged from 78 to 94.9 points, all was in the arthroscopic group.

VAS Score, three studies reported VAS scores for pain, two studies of arthroscopic group and one study of injection therapy group, the mean score decreased from 7.5 and 5.4 to 0.8 and 0.9 respectively in patients treated by arthroscopic technique, and from 6.76 to 2.73 in patients treated with injection therapy.

Return to full activity, six studies reported time to return to full activity, 4 studies of arthro-endoscopic group and 2 studies of ultrasound -guided injection group, mean time in the arthroscopic group was 7 weeks, while that of injection therapy was 3 weeks.

Complications were recorded in all studies, resulting in a summed complication rate of 14.1%, the rate was 13.2% in patients treated with arthroscopy, on the other hand the rate was 17.6% in those patients treated with injection therapy technique.

Table (1): The characteristics of included studies

1st author, Publication year	Number of patients	Preoperative diagnosis	Mean age (year)	The mean follow-up time(months)	Sex (M/F)	Method of diagnosis	Intervention
Ürgüden et al. 2005 (14)	41	anterior ankle impingement	33.2	83.7	25/16	Phys exam, Xlat, MRI	Anterior ankle arthroscopy
Christina Messiou et al. 2005 (15)	9	Posteromedial ankle impingement	29	18	8/1	Phys exam, Xap, Xlat,US, MRI	Ultrasound guided injection
Robinson et al. 2006 (16)	10	posterior ankle impingement	25	26	10/0	Phys exam, Xap, Xlat,US, MRI	Ultrasound guided injection
Scholten et al. 2008 (17)	55	posterior ankle impingement	26.4	36	30/25	Phys exam, Xap, Xlat, CT	Hindfoot endoscopy
Christopher and Kennedy 2010 (18)	41	Anteromedial ankle impingement	31.12	34.41	26/15	Phys exam, Xlat, Xobl, MRI	Anterior ankle arthroscopy
Alessandro et al. 2014 (19)	80	anterior ankle impingement	37.3	104.6	55/25	Phys exam, Xap, Xlat, Xobl,MRI	Anterior ankle arthroscopy
Víctor López et al. 2015 (20)	20	posterior ankle impingement	24.8	78.6	19/1	Phys exam, Xap, Xlat, MRI	Hindfoot endoscopy
Dominic et al. 2015 (21)	20	posterior ankle impingement	21	38.2	6/14	Phys exam, Xap, Xlat, MRI	Hindfoot endoscopy
Levon et al. 2017 (22)	49	anterior ankle impingement	42.7	27	23/26	Phys exam, Xap, Xlat,US, MRI	Ultrasound guided injection

CT: computed tomography; F: female; M: male ; MRI: magnetic resonance imaging Phys exam: physical examination; Xap: radiograph in AP direction; Xlat: radiograph in lateral direction.

Xobl: oblique radiograph; US: ultrasonography.

Table (2): The outcome measures of included studies

1 st author	Time to return to full activity(wks)	patient satisfaction (%)	(VAS) score		(AOFAS) score		complications
			Pre	Post	pre	post	
<i>Ürgüden et al. (14)</i>	–	90%	–	–	58.2	89.6	One case with permanent superficial peroneal nerve injury. (2.4%)
<i>Christina et al. (15)</i>	3	–	–	–	–	–	One patient with reoperation. (11.1%)
<i>(16 Robinson et al.</i>	3	–	–	–	–	–	One patient underwent hindfoot endoscopy(one patient with reoperation (10%)
<i>Scholten et al. (17)</i>	8	74%	–	–	75	90	One patient with, a temporary loss of sensation of the posteromedial aspect of the heel. (1.8%)
<i>Christopher et al. (18)</i>	7	93%	–	–	62.8	91.2	A case with a neurapraxia of the superficial peroneal nerve, a case of arthrofibrosis, and a case developed CRPS. (7%)
<i>Alessandro et al. (19)</i>	–	–	–	–	50.9	78	Five cases had a superficial infection of the arthroscopic wounds. Two patients had numbness on the dorsal foot.Reoperation needed in 15 patients. (27.5%)
<i>Víctor López et al. (20)</i>	6.7	–	7.5	0.8	–	–	sural nerve sensory loss, superficial wound infection, reflex sympathetic dystrophy,and reoperation in one patient.(24%)
<i>Dominic et al. (21)</i>	6	94%	5.4	0.9	75	94.9	one case experienced plantar neuritis and another with Achilles tightness. (10%)
<i>Levon et al. (22)</i>	–	79%	6.8	2.73	–	–	Ten patients went into surgical treatment after relapse of symptoms(10 patients with reoperation). 20.4%

–, not reported; AOFAS: American Orthopaedic Foot and Ankle Society score; VAS: visual analog scale.
CRPS : chronic regional pain syndrome; wks : weeks; pre : preoperative; post : postoperative.

Ankle Arthroscopy versus Conservative Modalities...

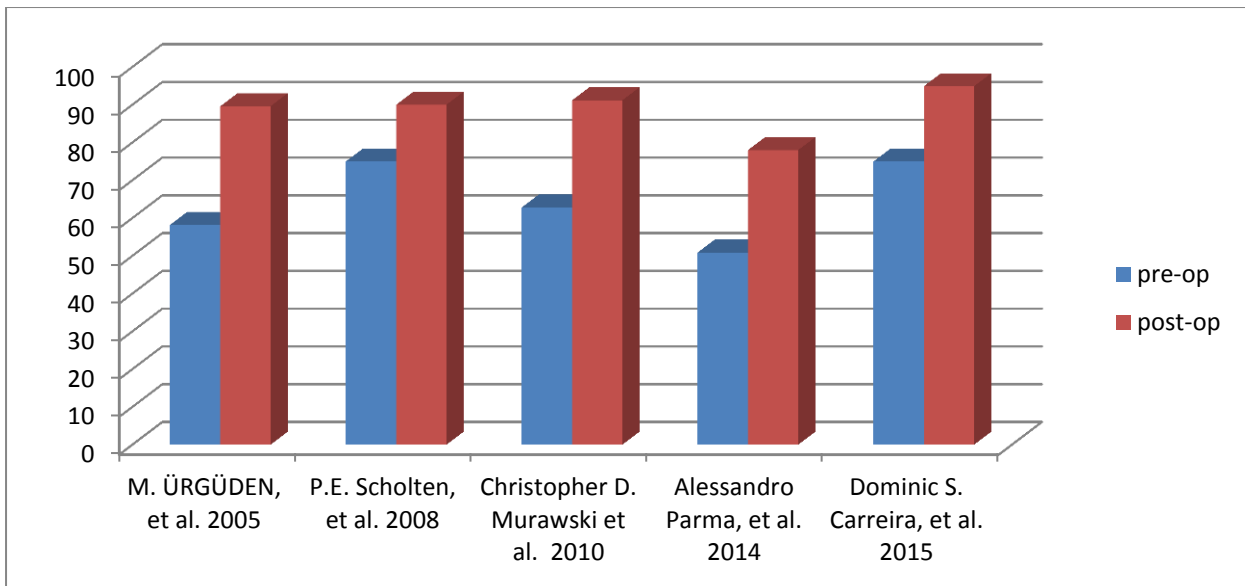


Figure (2): American Orthopedic Foot and Ankle Society (AOFAS) Score pre- and postoperative.

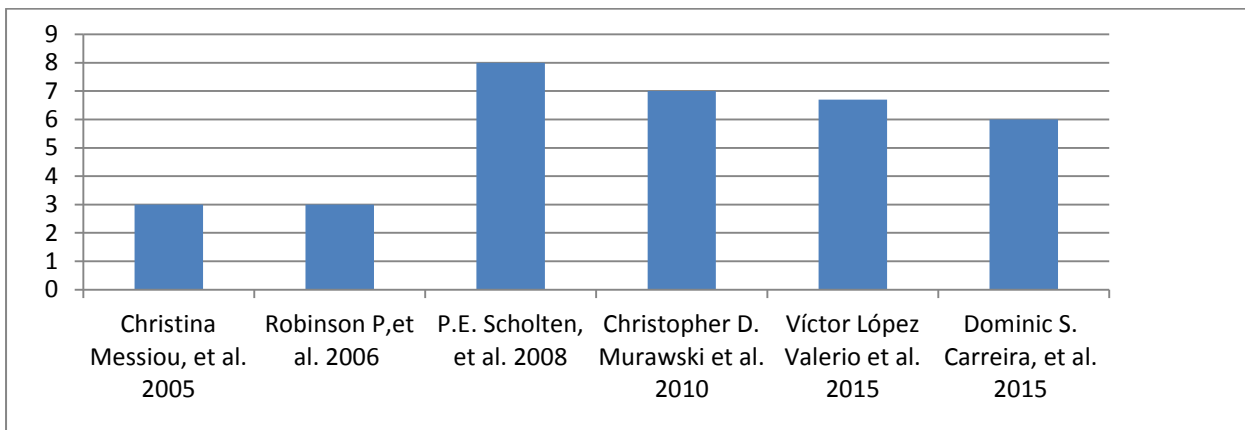


Figure (3): Time to return to full activity reported in weeks.

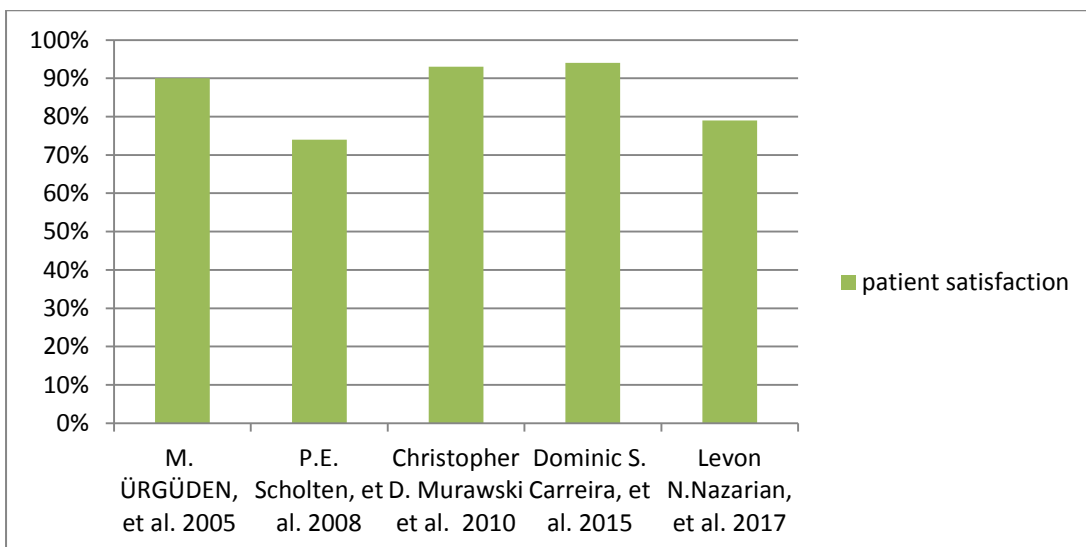


Figure (4): Percent of patient satisfaction in studies reporting it.

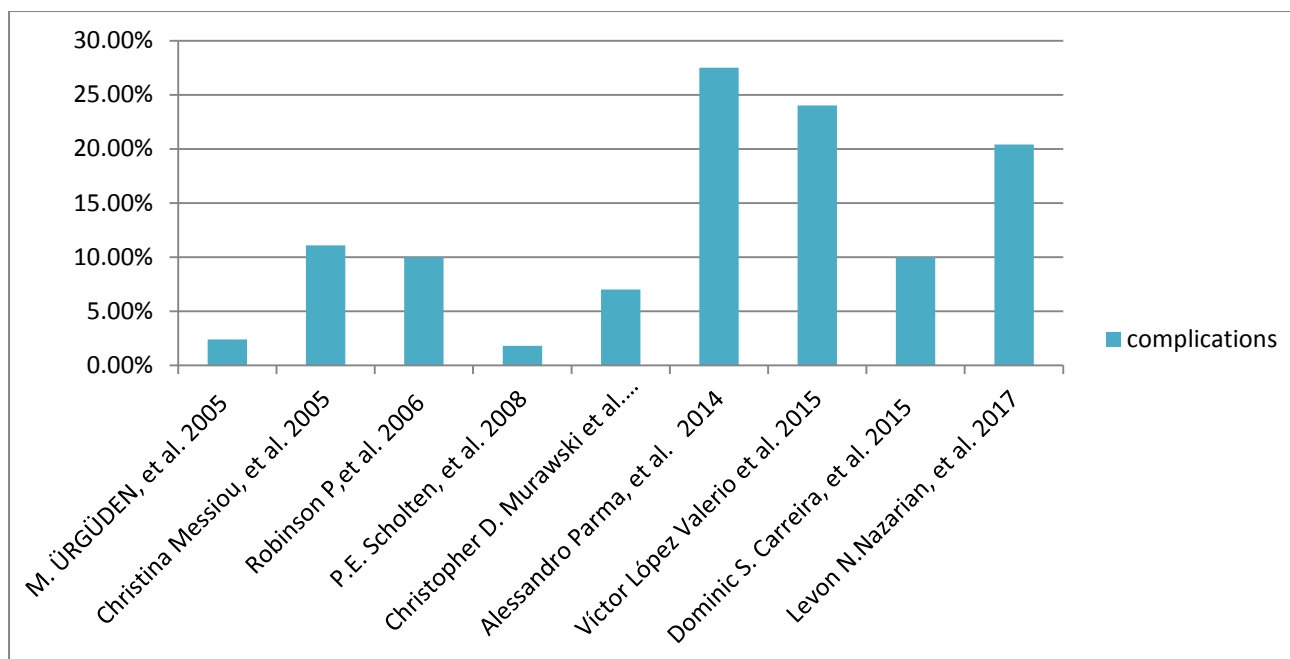


Figure (5): Percent of complications in each included study.

DISCUSSION

The ankle impingement syndromes are defined as pathologic conditions causing painful restriction of movement at the tibiotalar joint caused by osseous or soft tissue overgrowth or by the presence of accessory ossification centers⁽⁴⁾. Conservative treatment, consisting of rest, physical therapy, ankle bracing, shoe modification, and/or local injection, is recommended as the primary treatment strategy for symptoms of ankle impingement syndrome⁽¹²⁾.

Arthroscopic debridement has gained popularity and is considered gold standard treatment for virtually all causes of impingement syndrome as it is minimally invasive and associated with low morbidity and faster recovery times⁽¹³⁾.

In our systematic review, 9 studies with 325 patients were evaluated based on patient satisfaction rates, complication rates, return to full activity, AOFAS score, and visual analogue scale score outcome measures to provide an overview of the current literature. Overall, good results were found for arthroscopic treatment in patients with ankle impingement.

In this study a selection of outcome measures was made based on relevant outcome measures and those most commonly used in the literature.

Patient satisfaction was reported in 5 studies, to compare categorical percentages of satisfied patients in different primary studies, we reported high percentages of good to excellent satisfaction

rates, ranging 74% to 94%, especially in patients treated with arthroscopy^(14, 17,18,21,22).

In a study by Ahn *et al.* using an endoscopic approach for excision of a symptomatic os trigonum, all 28 patients said they were satisfied with the result of the surgery and would elect to have the procedure again if needed⁽²³⁾.

As regard return to full activity, 6 studies reported the time to return to full activity, 4 studies of arthro-endoscopic group and 2 studies of ultrasound -guided injection group, the mean time in the arthroscopic group was 7 weeks, while that of injection therapy was 3 weeks^(15,16,17,18,20,21).

Return to full activity appears quicker on average with ultrasound-guided injection group than arthro-endoscopic techniques, but injection therapy needs a long term follow up to confirm that it is not a temporary effect, and also injection therapy is used mainly in case of soft tissue impingement type.

AOFAS score was reported in 5 studies, with preoperative and postoperative scores. The mean preoperative scores ranged between 50.9 and 75 points. Postoperatively, the mean scores ranged from 78 to 94.9 points, all was in the arthroscopic group^(14,17,18,19,21).

As regard the American Orthopedic Foot and Ankle Society (AOFAS) hindfoot score, the maximum possible AOFAS score is 100 points, and it consists of three components: pain (50 points), function (40 points), and alignment (10 points)⁽¹⁷⁾.

Three studies reported VAS score for pain. Two studies of arthroscopic group and one study of injection therapy group, the mean score decreased from 7.5 and 5.4 to 0.8 and 0.9 respectively in patients treated by arthroscopic technique, and from 6.76 to 2.73 in patients treated with injection therapy, so it is clear that the decrease in pain level is more in patients treated with ankle arthroscopy than that patients treated with injection therapy^(20,21,22).

In the case of AOFAS scores, which have a maximum score (higher values means favorable outcome), or the time to return to activity and VAS score for pain, which has a minimum outcome (lower scores means favorable outcome) the mean outcomes may be an underestimate of the real outcomes of the study.

Complications were recorded in all studies, resulting in a summed complication rate of 14.1%, but as regard to patients treated with arthroscopy the rate was 13.2%, on the other hand the rate was 17.6% in those patients treated with injection therapy technique. The most commonly reported complications were nerve symptoms, reoperation, and superficial infection^(14,22).

In this study the variation in complication rates among studies using the same technique is remarkable. This finding suggests that the experience of the surgeon is expected to have a significant effect on the outcomes of the procedure.

Zwiers *et al.* conducted a recent systematic review, examining the results of the arthroscopic treatment of anterior ankle impingement syndrome. The review included 905 patients, with a mean age of 32.7 years. The combined mean follow-up was 35.3 months, 74–100 % of patients were satisfied with the results of their procedure. AOFAS hindfoot scores improved consistently, ranging from 34–75 preoperatively and increasing to 83.5–92 postoperatively. There was a 5.1 % overall complication rate⁽²⁴⁾.

In a case series by Edmonds *et al.* reported on 13 patients with a mean age of 15.6 years, diagnosed with anterolateral impingement syndrome. The mean duration of nonoperative management (nonsteroidal anti-inflammatory drugs, physical therapy, and activity modifications) was 6.9 months (range, 2-12 months). The mean AOFAS score ratings at initial presentation, was 68.4 (range, 40-84) with no significant change after nonoperative management, 68.2 (range, 63-76)⁽²⁵⁾.

Ferkel *et al.* and van Dijk *et al.* reported impingement symptoms as unresponsive to nonoperative therapy^(26, 27).

A previous systematic review showed that there is fair evidence-based literature to support a recommendation for the use of ankle arthroscopy for the treatment of ankle impingement. Despite, no inclusion or exclusion criteria were reported. Good to excellent outcome rates were shown⁽²⁸⁾.

In our review we could not made correlation between associated chondral lesions and instability on the outcome of patients with ankle impingement syndrome. Some authors stated that these diseases did not affect the results, whereas others observed that they affected outcomes negatively^(29,30).

In the study by Murawski and Kennedy, no difference was seen in patients with osteochondral defects treated with microfracture⁽¹⁸⁾.

In the study by Ürgüden *et al.* cartilage damage ranging from grade I to III to the anterolateral aspect of the dome of the talus or at the distal tibia was seen in 19 patients. At follow-up, patients with cartilage damage showed statistically lower AOFAS scores than patients without it⁽¹⁴⁾.

Although conservative management is the first line of treatment, there is a lack of studies looking at conservative management for ankle impingement syndrome in the literature.

Despite these findings, the high heterogeneity of the included studies made it very difficult to compare the results of the studies, including between different types of ankle impingement syndrome. Given that these different types have different clinical presentations and etiologies, a difference in prognosis may be expected.

CONCLUSION

Our systematic review showed that Patients may respond to conservative treatment modalities, especially ultra-sound guided injection mainly in soft tissue impingement type, arthroscopic debridement is the treatment of choice for patients of ankle impingement syndrome of both osseous and soft tissue nature with least morbidity and early return to function, and also it is noted to be superior to conservative modalities.

REFERENCES

1. Ferkel RD, Karzel RP, Del Pizzo W *et al.* (1991): Arthroscopic treatment of anterolateral impingement of the ankle. *Am J Sports Med.*, 19:440–446.
2. Morris LH (1943): Athlete's ankle. *J Bone Joint Surg.*, 25:220.

3. **McMurray TP (1950):** Footballer's ankle. *J Bone Joint Surg Br.*, 32B:68–9.
4. **Ogilvie-Harris DJ, Gilbert MK, Chorney K (1997):** Chronic pain following ankle sprains in athletes: the role of arthroscopic surgery. *Arthroscopy*, 13: 564–74.
5. **Paterson RS, Brown JN, Roberts SNJ (2001):** The posteromedial impingement lesion of the ankle. *Am J Sports Med.*, 29:550–557.
6. **Tol JL, Slim E, van Soest AJ *et al.* (2002):** The relationship of the kicking action in soccer and anterior ankle impingement syndrome: a biomechanical analysis. *Am J Sports Med.*, 30(1):45–50.
7. **Meislin RJ, Rose DJ, Parisien JS *et al.* (1993):** Arthroscopic treatment of synovial impingement of the ankle. *Am J Sports Med.*, 21:186–189.
8. **Solomon R, Brown T, Gerbino PG *et al.* (2000):** The young dancer. *Clin Sports Med.*, 19(4):717–39.
9. **O'Kane JW, Kadel N (2008):** Anterior impingement syndrome in dancers. *Journal of Current Reviews in Musculoskeletal Medicine*, 1:12–6.
10. **Robinson P, White LM, Salonen DC *et al.* (2001):** Anterolateral ankle impingement: MR arthrographic assessment of the anterolateral recess. *Radiology*, 221:186–190.
11. **Van Dijk CN, Wessel RN, Tol JL *et al.* (2002):** Oblique radiograph for the detection of bone spurs in anterior ankle impingement. *Skeletal Radiol.*, 31(4):214–221.
12. **Coull R, Raffiq T, James LE *et al.* (2003):** Open treatment of anterior impingement of the ankle. *J Bone Joint Surg Br.*, 85:550–553.
13. **Ogilvie-Harris DJ, Mahomed N, Demaziere A (1993):** Anterior impingement of the ankle treated by arthroscopic removal of bony spurs. *J Bone Joint Surg Br.*, 75:437–440.
14. **Ürgüden M, Soyuncu Y, Ozdemir H *et al.* (2005):** Arthroscopic treatment of anterolateral soft tissue impingement of the ankle: evaluation of factors affecting outcome. *Arthroscopy*, 21:317–322.
15. **Messiou C, Robinson P, O'Connor PJ *et al.* (2006):** Subacute posteromedial impingement of the ankle in athletes: MR imaging evaluation and ultrasound-guided therapy. *Skeletal Radiol.*, 35: 88–94.
16. **Robinson P, Bollen SR (2006):** Posterior ankle impingement in professional soccer players: effectiveness of sonographically guided therapy. *AJR Am J Roentgenol.*, 187:W53–W58.
17. **Scholten PE, Sierevelt IN, van Dijk CN (2008):** Hindfoot endoscopy for posterior ankle impingement. *J Bone Joint Surg Am.*, 90:2665–2672.
18. **Murawski CD, Kennedy JG (2010):** Anteromedial impingement in the ankle joint: Outcomes following arthroscopy. *Am J Sports Med.*, 38:2017–2024.
19. **Alessandro P, Roberto B, Francesca V *et al.* (2014):** Arthroscopic treatment of ankle anterior bony impingement: The long-term clinical outcome. *Foot Ankle Int.*, 35(2):148–155.
20. **López V, Seijas R, Alvarez P *et al.* (2015):** Endoscopic repair of posterior ankle impingement syndrome due to os trigonum in soccer players. *Foot Ankle Int.*, 36:70–74.
21. **Carreira DS, Vora AM, Hearne K *et al.* (2016):** Outcome of arthroscopic treatment of posterior impingement of the ankle. *Foot Ankle Int.*, 37(4):394–400.
22. **Levon N, Nar V, Erik M *et al.* (2018):** Ultrasound-guided percutaneous needle fenestration and corticosteroid injection for anterior and anterolateral ankle impingement. *Foot Ankle Spec.*, 11(1):61–66.
23. **Ahn JH, Kim YC, Kim HY (2013):** Arthroscopic versus posterior endoscopic excision of a symptomatic os trigonum: a retrospective cohort study. *Am J Sports Med.*, 41(5):1082–1089.
24. **Zwiers R, Johannes I, Christopher D *et al.* (2015):** Arthroscopic treatment for anterior ankle impingement: a systematic review of the current literature. *Arthroscopy*, 31(8):1585–96.
25. **Eric W, Reid C, Elizabeth K *et al.* (2010):** Anterolateral Ankle Impingement in Adolescents: Outcomes of Nonoperative and Operative Treatment. *J Pediatr Orthop.*, 30:186–191.
26. **Ferkel RD, Karzel RP, Del Pizzo W *et al.* (1991):** Arthroscopic treatment of anterolateral impingement of the ankle. *Am J Sports Med.*, 19(5):440–446.
27. **van Dijk CN, Tol JL, Verheyen CC (1997):** A prospective study of prognostic factors concerning the outcome of arthroscopic surgery for anterior ankle impingement. *Am J Sports Med.*, 25:737–745.
28. **Glazebrook MA, Ganapathy V, Bridge MA *et al.* (2009):** Evidence-based indications for ankle arthroscopy. *Arthroscopy*, 25:1478–1490.
29. **Hassan A (2007):** Treatment of anterolateral impingements of the ankle joint by arthroscopy. *Knee Surg Sports Traumatol Arthrosc.*, 15:1150–1154.
30. **DeBerardino TM, Arciero RA, Taylor DC (1997):** Arthroscopic treatment of soft-tissue impingement of the ankle in athletes. *Arthroscopy*, 13:492–498.