

## Correlation of Average Retinal Nerve Fiber Layer Thickness Using OCT with The Perimetric Staging in Primary Open Angle Glaucoma

Hosny Hassan Mohammad, Abd Elghany Ibrahim Abd Elghany,  
Ibrahim Mohamed Ibrahim El Karmout

Department Ophthalmology Faculty of Medicine - Al Azhar University

\*Corresponding author: Ibrahim Mohamed Ibrahim El Karmout, Email:ibramo1990@gmail.com ,Tel no: 01000901850

### ABSTRACT

**Background:** Primary open angle glaucoma (POAG) is the most common type of glaucoma which is considered chronic progressive optic neuropathy, accompanied by a characteristic cupping and atrophy of the optic disc, visual field loss, open angle and no obvious systemic or ocular cause.

**Subjects and Methods:** In this study all cases were examined in the period extending from December, 2016 to august, 2017, including 46 eyes of 30 subjects, the eyes were classified according to disease severity into 22 cases with early glaucoma, 16 cases with moderate glaucoma and 8 cases with severe glaucoma according to Hodapp, Parrish, and Anderson classification.

**Objectives: Inclusion criteria included:** All cases have primary open angle glaucoma, presence of at least one reliable visual field, controlled IOP within range 12-21 mm/Hg. **Exclusion criteria included:** Cases with closed angles or any angle abnormality on gonioscopy, any other retinal or choroidal insult, including other causes of optic atrophy, patients with affected visual field due to any cause rather than POAG, secondary glaucomas. **Results:** This study included 46 eyes of 30 subjects which were classified according to disease severity into: **Early glaucoma:** included 22 eyes. **Moderate glaucoma:** included 16 eyes. **Severe glaucoma:** included 8 eyes. **Conclusion:** There is significant direct correlation between average retinal nerve fibre layer thinning and visual field mean deviation.

**Keywords:** EMGT, Early manifest glaucoma trial; GPA, Guided progression index; IOP, Intraocular pressure

### INTRODUCTION

As glaucoma is the second leading cause of blindness in the world, the main goal of glaucoma management is to diagnose the disease when it is asymptomatic. Visual field (VF) testing is essential in the diagnosis and monitoring of glaucoma. However, it is known that standard perimetry cannot detect visual field defects until 20% - 40% of ganglion cells have been lost. Retinal nerve fiber defects have been objectively demonstrated earlier than VF defects with new investigative technologies. Measuring retinal nerve fiber layer (RNFL) thickness by Optical coherence tomography (OCT) enables an objective and quantitative assessment of glaucomatous structural loss<sup>(3)</sup>. (OCT) is an innovative medical diagnostic imaging technology which can perform micron resolution cross-sectional or tomographic imaging in biological tissues. OCT is especially suited for diagnostic applications in ophthalmology because of the ease of optical access to the anterior and posterior segments of the eye<sup>(2)</sup>. Spectral domain or Fourier domain OCT (SD-OCT) uses a spectrometer as a detector of OCT signal. Which has benefits over time domain OCT (TD-OCT) such as higher axial resolution, faster scanning speed and better reproducibility<sup>(2)</sup>.

### SUBJECTS AND METHODS

In this study all cases were examined in the period extending from December, 2016 to august, 2017,

including 46 eyes of 30 subjects, the eyes were classified according to disease severity into 22 cases with early glaucoma, 16 cases with moderate glaucoma and 8 cases with severe glaucoma according to Hodapp, Parrish, and Anderson classification.

### RESULTS

This study included 46 eyes of 30 subjects that were classified according to disease severity into:

**Early glaucoma:** included 22 eyes.

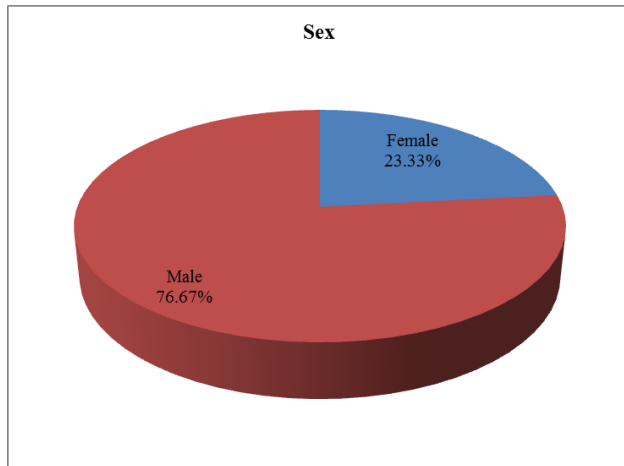
**Moderate glaucoma:** included 16 eyes.

**Severe glaucoma:** included 8 eyes.

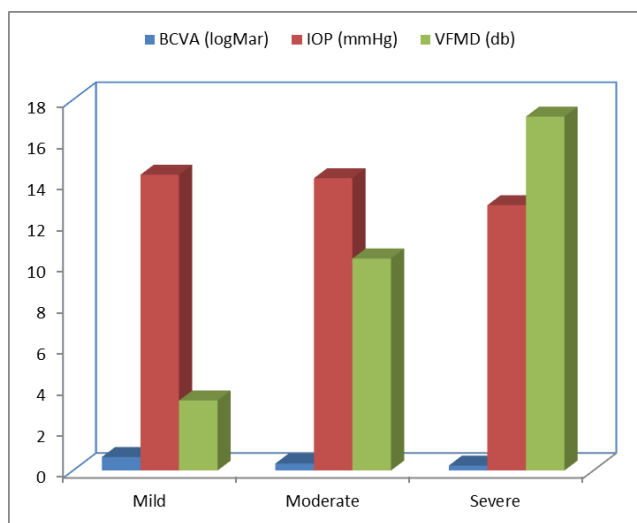
**Demographic data:** The thirty subjects of this study were distributed as follow, the female (23.33%) and male (76.67%)(fig 1) , family history positive (23.33%) and negative (76.67%), while age ranged from 43 to 76 years old with mean 62.4±8.51.(table 1)

**Table (1):** Demographic data distribution of the study group

	Demographic Data	Total (N=30)
<b>Sex</b>	Female	7 (23.33%)
	Male	23 (76.67%)
<b>Age (years)</b>	Range	43-76
	Mean ± SD	62.4 ± 8.51
<b>Family history</b>	Positive	7 (23.33%)
	Negative	23 (76.67%)



**Fig. (1):** Sex distribution of the study group.

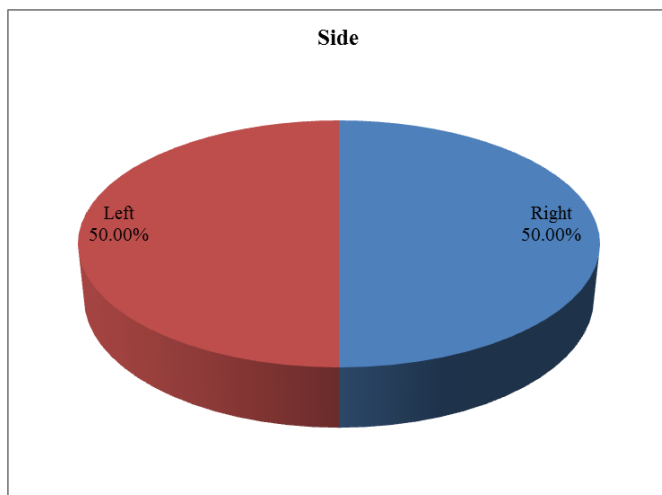


**Fig. (2):** Side distribution of the study group

**Table (2):** Side distribution of the study group.

Side	Total (N=46)
Right	23 (50%)
Left	23 (50%)

This table shows that the right (50%) and left (50%) of side.



**Fig. (3):** Bar chart between glaucoma subgroups regarding basic data.

**Table (3):** Comparison between glaucoma subgroups regarding basic data

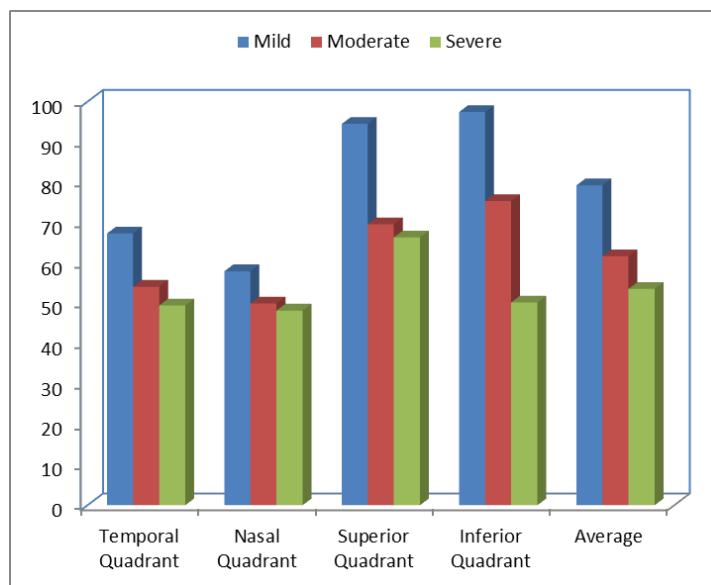
Basic data	Mild	Moderate	Severe	ANOVA	p-value
<b>BCVA (logMar)</b>					
Mean±SD	0.66±0.14	0.34±0.18	0.24±0.09	34.191	<0.001
Range	0.3-1	0.1-0.8	0.1-0.4		
<b>IOP (mmHg)</b>					
Mean±SD	14.36±1.99	14.19±1.76	12.88±0.83	2.161	0.128
Range	11-18	11-17	11-14		
<b>VFMD (db)</b>					
Mean±SD	3.40±2.02	10.29±1.72	17.18±3.57	119.876	<0.001
Range	0.2-6.9	6.9-14.3	12-21.5		

**Comparison between glaucoma subgroups regarding retinal nerve fiber layer measurements**

The present study showed that RNFL is markedly thinner in severe than in moderate and mild stages of glaucoma respectively and this is most evident in inferior and superior quadrants (table 4) (fig 4).

**Table (4):** Comparison between glaucoma subgroups regarding retinal nerve fiber layer measurements

Retinal nerve fiber layer of quadrants measurements	Mild	Moderate	Severe	AONVA	p-value
<b>Temporal Quadrant</b>					
Mean±SD	67.36±13.87	54.13±10.07	49.50±11.80	6.344	0.004
Range	47-90	30-66	30-95		
<b>Nasal Quadrant</b>					
Mean±SD	58.00±10.62	50.00±15.18	48.25±12.23	0.744	0.481
Range	42-83	30-88	5-172		
<b>Superior Quadrant</b>					
Mean±SD	94.50±15.37	69.63±12.25	66.38±12.31	4.861	0.012
Range	61-128	39-122	25-191		
<b>Inferior Quadrant</b>					
Mean±SD	97.45±16.30	75.38±14.99	50.25±12.21	18.838	<0.001
Range	62-125	44-122	31-65		
<b>Average</b>					
Mean±SD	79.27±11.11	61.69±14.29	53.63±12.00	8.492	<0.001
Range	57-98	45-99	34-131		



**Fig. (4):** Bar chart between glaucoma subgroups regarding retinal nerve fiber layer measurements

## DISCUSSION

This study that included 46 eyes of 30 subjects compared the degree of thinning in various stages of glaucoma and studied the relation between the degree of thinning of average retinal nerve fiber layer and the degree of visual field changes.

Regarding the comparison between average retinal nerve fiber measurements in patients with different stages of glaucoma and controls, the present study found that patients with early disease had significantly thicker average RNFL thickness measurements when compared with patients with moderate and severe disease ( $79.2 \pm 12 \mu\text{m}$ ,  $61.7 \pm 14 \mu\text{m}$  and  $53.6 \pm 12 \mu\text{m}$  respectively). Also, patients with moderate disease had significantly thicker RNFL thickness measurements when compared with patients with severe disease. In addition, normal controls had significantly thicker RNFL thickness measurements when compared to all degrees of glaucoma.

This is in harmony with the study of **Mansoori et al.**<sup>(3)</sup> who assessed the utility of SD-OCT to distinguish normal eyes from those with early glaucoma in Asian Indian eyes. The study included 178 eyes (83 glaucoma patients and 95 age matched healthy subjects). The mean RNFL thickness in healthy subjects and patients with early glaucoma were  $105.7 \pm 5.1 \mu\text{m}$  and  $90.7 \pm 7.5 \mu\text{m}$ , respectively ( $p=0.001$ ).

In addition, **Kaw et al.**<sup>(4)</sup> in their study aimed to compare SD- OCT evaluation of RNFL thickness in normal controls and POA glaucoma of various stages and found that normal patients had the thickest RNFL thickness when compared with patients with the severe glaucoma that was associated with thinner RNFL.

Moreover, the study of **Firat et al.**<sup>(5)</sup> measured RNFL thickness in POAG, normal tension glaucoma (NTG) and normal subjects using SD-OCT. RNFL thickness parameters were significantly greater in normal subjects, followed in order by the NTG, and POAG ( $p < 0.05$ ).

Moreover, this present study data are in accordance with another study in which they noted that normal controls had significantly higher RNFL thickness when compared with glaucoma patients and those with more severe disease had significantly thinner RNFL<sup>(6)</sup>.

Also, the present study is in agreement with another study who assessed RNFL thickness in patients with glaucoma and healthy controls. In their study, patients with glaucoma had significantly lower RNFL thickness when compared with controls ( $87 \pm 26 \mu\text{m}$  vs  $111 \pm 15 \mu\text{m}$ ,  $p < 0.0001$ )<sup>(7)</sup>.

However, in the study of **Nakatani et al.**<sup>(8)</sup> who evaluated the diagnostic ability of peripapillary RNFL parameters for early glaucoma using spectral domain optical coherence tomography (SD-OCT). They reported that a significant differences between early glaucoma and normal participants were found for all parameters except fovea in macular scans and in the superior and inferior quadrants, at 12, 3, 6, 7, 11 o'clock, and average RNFL thickness in RNFL scans.

In the present study, there was a significant correlation between visual field loss and RNFL thickness. Also, Nerve thinning was more significant in cases with severe glaucoma when compared with patients with mild and moderate glaucoma.

This is in accordance with the study of **Sehi et al.**<sup>(9)</sup> who compared prospectively detection of progressive RNFL atrophy identified using time-domain optical coherence tomography with visual field progression using standard automated perimetry in glaucoma suspect and preperimetric glaucoma patients or perimetric glaucoma patients. They found that structural progression is associated with functional progression in glaucoma suspect and glaucomatous eyes. Average and superior RNFL thickness may predict subsequent standard automated perimetry loss.

This is in agreement with the study of **Alasil et al.**<sup>(10)</sup> who studied 108 glaucoma patients in addition to 78 healthy controls they were subjected to visual field analysis and spectral-domain optical coherence tomography RNFL scans aiming to detect the RNFL thickness threshold at which VF loss begins to be clinically detectable. The study revealed a statistically significant correlation between RNFL thickness and corresponding VF loss. In addition, the study of **Miki et al.**<sup>(11)</sup> used RNFL thickness measurements by OCT to predict visual field loss in patients with glaucoma. In their study, 454 eyes from 294 glaucoma suspects were included. The study found that the rate of global RNFL loss was more than twice as fast in eyes that developed VFD compared with eyes that did not develop VFD. The authors concluded that measuring the rate of SD-OCT RNFL loss may be a useful tool to help to identify patients who are at a high risk of developing visual field loss.

In the current study, comparison between different groups showed that patients with moderate glaucoma had 22.18 % thinning and patients with severe glaucoma had 32.35 % thinning in relation to mild group. This agrees with the former study of **Kaw et al.**<sup>(4)</sup>. They found that in comparison to healthy controls, patients with mild glaucoma had

12.2 % thinning while patients with moderate glaucoma had 22.1% thinning and patients with severe glaucoma had 42.7 % thinning.

Finally, the present study found that RNFL thickness has a good diagnostic value for diagnosis of glaucoma and for differentiating moderate from mild glaucoma and severe from moderate glaucoma. This is in agreement with the study of **Elbendary and Helal** <sup>(6)</sup> and with a recent metaanalysis performed by **Michelessi *et al.*** <sup>(12)</sup>. The authors included prospective and retrospective cohort studies and case-control studies that evaluated the accuracy of OCT for diagnosing glaucoma. They reported that RNFL had a high accuracy for diagnosing glaucoma.

## CONCLUSION

There is significant direct correlation between average retinal nerve fibre layer thinning and visual field mean deviation.

## REFERENCES

- Sung KR, Sun JH, Na JH et al. (2012):** Progression detection capability of macular thickness in advanced glaucomatous eyes. *Ophthalmology*, 119: 308-313.
- Fujimoto JG (2003):** Optical coherence tomography for ultrahigh resolution in vivo imaging. *Nat Biotechnol.*, 21(11): 1361-7.
- Mansoori T, Viswanath K, Balakrishna N (2011):** Ability of spectral domain optical coherence tomography peripapillary retinal nerve fiber layer thickness measurements to identify early glaucoma. *Indian J Ophthalmol.*, 59(6): 455-9.
- Kaw SMG, Martinez JM, Tumbocon JA, Atienza NJ (2012):** Correlation of Average RNFL Thickness Using the STRATUS OCT with the Perimetric Staging of Glaucoma. *Philipp J Ophthalmol*, 152(4): 112-127.
- Firat PG, Doganay S, Demirel EE, Colak C (2013):** Comparison of ganglion cell and retinal nerve fiber layer thickness in primary open-angle glaucoma and normal tension glaucoma with spectral-domain OCT. *Graefes Arch Clin Exp Ophthalmol.*, 251(3): 831-8.
- Elbendary AM, Helal MR (2013):** Discriminating ability of spectral domain optical coherence tomography in different stages of glaucoma. *Saudi J Ophthalmol.*, 27(1): 19-24.
- Golzan SM, Morgan WH, Georgevsky D, Graham SL (2015):** Correlation of retinal nerve fibre layer thickness and spontaneous retinal venous pulsations in glaucoma and normal controls. *PLoS One*, 10(6): e0128433.
- Nakatani Y, Higashide T, Ohkubo S, Takeda H, Sugiyama K (2011):** Evaluation of macular thickness and peripapillary retinal nerve fiber layer thickness for detection of early glaucoma using spectral domain optical coherence tomography. *J Glaucoma*, 20(4): 252-9.
- Sehi M, Zhang X, Greenfield DS, Chung Y, Wollstein G, Francis BA, Schuman JS, Varma R, Huang D (2013):** Advanced Imaging for Glaucoma Study Group. Retinal nerve fiber layer atrophy is associated with visual field loss over time in glaucoma suspect and glaucomatous eyes. *Am J Ophthalmol.*, 155(1): 73-82.e1.
- Alasil T, Wang K, Yu F, Field MG, Lee H, Baniasadi N, de Boer JF, Coleman AL, Chen TC (2014):** Correlation of retinal nerve fiber layer thickness and visual fields in glaucoma: a broken stick model. *Am J Ophthalmol.*, 157(5): 953-59.
- Miki A, Medeiros FA, Weinreb RN, Jain S, He F, Sharpsten L, Khachatryan N, Hammel N, Liebmann JM, Girkin CA, Sample PA, Zangwill LM. (2014):** Rates of retinal nerve fiber layer thinning in glaucoma suspect eyes. *Ophthalmology*, 121(7):1350-8.
- Michelessi M, Lucenteforte E, Oddone F, Brazzelli M, Parravano M, Franchi S, Ng SM, Virgili G (2015):** Optic nerve head and Fibre layer imaging for diagnosing glaucoma. *Cochrane Database Syst Rev.*, 11: CD008803.