

A comparative study between transplantation of conjunctival limbal autograft with mitomycin C and amniotic membrane transplantation with mitomycin C in recurrent pterygium

Mohammed O. AbdElKhalek, Waleed M. Mahran, Safaa A Aboud

Ophthalmology Department, Faculty of Medicine, Beni-Suef University, Egypt ,
nabi_mar@yahoo.com , 01117663009

Abstract

Introduction: Pterygium, a wing-shaped encroachment of the cornea by the conjunctiva, Conjunctival limbal autograft with stem cell (CLAU) or amniotic membrane transplantation (AMT) has been widely adopted in the management of pterygium.

Purpose: To compare the efficacy and the complications of conjunctival limbal autograft (CLAU) with mitomycin C 0.2 % and amniotic membrane transplantation (AMT) with mitomycin C 0.2 % for treatment of recurrent pterygium

Subject and methods: 80 eyes of 60 patients clinically diagnosed with recurrent pterygium were divided into two groups , group A included 40 eyes underwent pterygium excision and MMC 0.2% with CLAU , group B included 40 eyes underwent pterygium excision and MMC 0.2% with AMT . Recurrence was defined as fibrovascular tissue extension of more than one mm onto the cornea in the area of previously excised pterygium. Mean follow up period 8±1 month. Recurrence was compared in each group by using χ^2 test.

Results:No major postoperative complications occurred during 6-9 months of follow-up. In CLAU group (A) only 5 eyes of recurrence occur (12.5%) after 7 months of follow up. Recurrence occur in 12 eyes (30%) in AMT group (B) after 6 months (P value =0.043, χ^2 test).The operated site was look like the normal adjacent site in 77%of the non-recurrence group A versus 10% in group B
Conclusion: CLAU with MMC is more effective than AMT with MMC for treatment of recurrent pterygium and the final cosmetic appearance is more acceptable in CLAU group than AMT group B.

Keywords: Pterygium, autograft, mitomycin C, amniotic membrane transplantation

Introduction

Pterygium is a common ocular surface disease that is characterized by the proliferation of bulbar conjunctiva and subconjunctival fibrovascular tissue in the palpebral fissure, which invades the clear cornea. Pterygium can cause corneal refractive disorders and visual impairment. The histopathological characteristics of pterygium are abnormal cell proliferation, inflammatory cell infiltration, fibrosis, angiogenesis, tissue degeneration, and excessive deposition of extracellular matrix. The development of pterygia is

multifactorial, including environmental irritants, for example long-term ultraviolet-B damage, wind, dust, chemicals, air pollution and hereditary factors.[1].

A healthy corneal surface is maintained by self-renewing , lineage stem cells that reside in the limbus (LSC) at a narrow annular transition zone that circumscribes the cornea The importance of an intact limbus and its stem cells was recognized by Kurpakus-Wheater who proposed that pterygia represent a specific zone of LSC deficiency [2].

A new hypothesis for pterygium development takes into account peripheral light focusing at the nasal limbus which activates and / or mutates LSCs , resulting in clonal expansion , local cell proliferation , and invasion of the cornea . Focal UV radiation may destroy the LSC repository, which act as a barrier that segregates cornea from conjunctiva thereby opening the flood gates for conjunctival ingress and pterygium formation [3].

According to the new hypothesis, restore the integrity of limbal stem cell is the mainstay to prevent the recurrence of pterygium. Conjunctival limbal autograft with stem cell or amniotic membrane transplantation which act as scaffold to encourage healthy limbal stem cell to migrate towered operated pterygium site has been widely adopted in the management of pterygium. The possible mechanisms of preventing pterygium recurrence include promotion of conjunctival epithelium, inhibition of inflammation by inhibiting chemokine expression by fibroblasts and interleukin-1 expression by epithelial cells, and inhibition of neovascularisation by inhibiting vascular endothelial cell growth [4].

As there has been no randomized study comparing the recurrence rate between conjunctival auto grafts and amniotic membrane grafts in recurrent pterygium, especially in tropical areas, we conducted a randomized controlled study to address this question.

Methods:

This study was designed as comparative single-blind randomized interventional study. Eighty eyes of 60 patients were clinically diagnosed

as recurrent pterygium and divided into two groups , group A included 40 eyes whom underwent pterygium excision and application of MMC 0.02% for 2 minutes to bare sclera and conjunctival limbal autograft , group B included 40 eyes whom underwent pterygium excision and application of MMC 0.02% for 2 minutes to bare sclera and amniotic membrane transplantation There were 20 patients (40 eyes) had one procedure in one eye and the other procedure in the second eye. The two procedures were carried out by the same surgeon to ensure that similar amounts of pterygial and surrounding fibrovascular tissue were removed. The results were assessed at 6 weeks, 6, 9 months by the surgeon in a blind assessment to grade the final appearance based on the criteria given by Prabhasawat, et al: [5]

Grade 1: The appearance of the operated site was not different from the normal appearance.

Grade 2: There were some fine episcleral vessels on the excised area extending up to, but not beyond the limbus without any fibrous tissue.

Grade 3: There was additional fibrous tissue in the excised area that did not invade the cornea.

Grade 4: True recurrence, with fibrovascular tissue invade the cornea.

The inclusion criteria :

1. Patients were diagnosed with recurrent pterygium and met the indication for surgical treatment.
2. Patients with pterygium whom signed the informed consent to enroll into the study.

The exclusion criteria :

1. Patients who have glaucoma or will undergo glaucoma surgery .
2. Patients who have a history of allergy or increase IOP in response to steroid eye drops.
3. Patients who had rheumatoid arthritis or autoimmune disease .

4. Patients who had scleral thinning or high myopia

Surgical Technique:

All Patients received peribulbar anesthesia with blunt 23 gauge needle . The head of the pterygium was excised by lamellar keratotomy using super blade and crescent knife (**figure 1A**) , the neck and the body removed from

the underling limbus and episclera using Wescott's scissors . Subconjunctival fibrous tissue was removed completely in an area much greater than the pterygium body itself. The target plane was reached when exposing all the tortuous episcleral blood vessels(**figure 1B**) , Any abnormal scars on the corneal surface were removed with crescent knife, application of MMC 0.02% for 2 minutes to bare sclera area

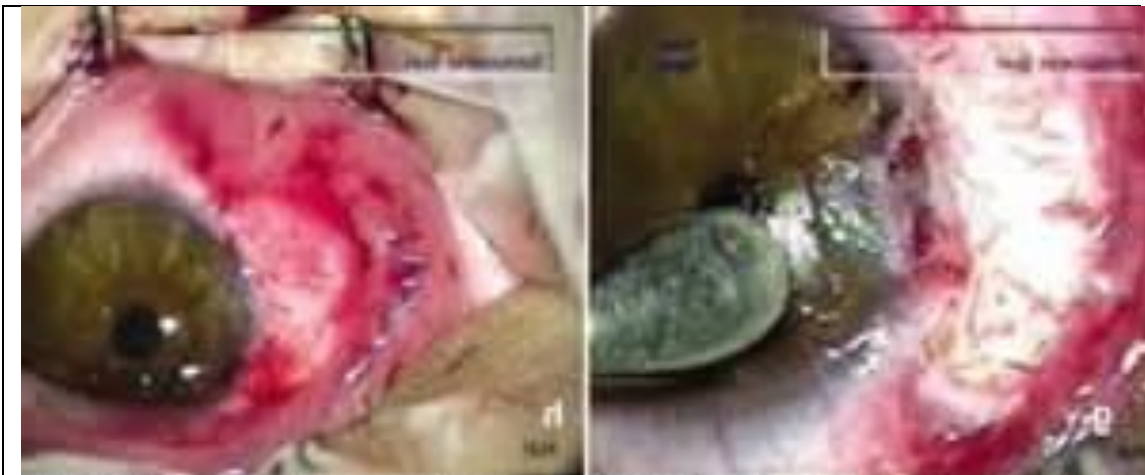

Figure 1 B : The target plane exposing all the tortuous episcleral blood vessels.

Figure 1A: Lamellar keratotomy for the head of the pterygium .

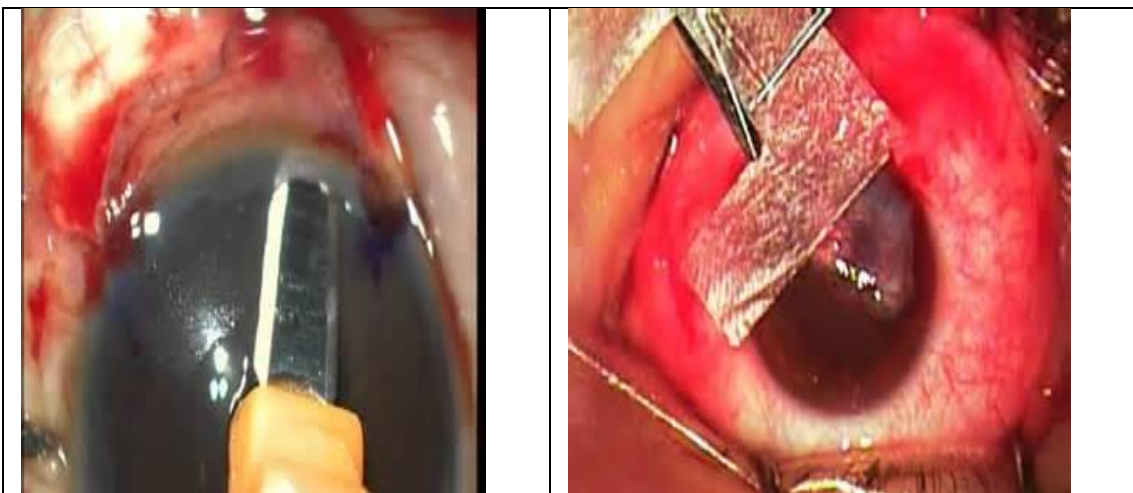


Figure 2 A : Conjunctival limbal autograft from the superior limbus.

Figure 2 b : Amniotic membrane ransplantation dried type

For conjunctival limbal autograft (group A), a free graft of size similar to the defect area was obtained from the superotemporal bulbar conjunctiva including 1mm of clear cornea to

ensure presence of limbal stem cells (**figure 2 A**).

For amniotic membrane graft (group B), the preserved amniotic membrane (freeze dried type) was removed and

cut into the same size as the defect (figure 2 B). Both types of graft were secured, flattened and approximated to the recipient episcleral tissue edge by interrupted 8-0 virgin sutures.

After surgery all patients received combination of tobramycin and dexamethasone phosphate 0.1% eye drops four time per day and tapered off within one month .

Statistical analysis

All demographic data including age, sex, occupation and diagnosis were compared between two groups using χ^2 test . The recurrence rate between two groups at 9 months were also analyzed using χ^2 test.

Results:

Eighty eyes of 60 patients were included in this study , that means there were 20 patients had one eye with amniotic membrane transplantaion and the other with conjunctival limbal autograft with mean follow up period 6 ± 2.1 months . The ratio right and left eyes, male to female, the age range and size of pterygia, in both groups mentioned in table (1)

Table 1 : Demographic data

Patients	Group A	Group B	P value
No of eyes 80	40	40	
OD 45	22	23	
OS 35	19	16	
No of patients 60	32	28	
Male 40	20	20	
Female 20	12	8	
Age range (years)	18-73	18-81	0.178
Mean Size (mm)	3.58	3.67	0.837

Postoperative complications were: increase intraocular pressure occurred in 10 eyes all of them returned to normal level after cessation of steroid drops (6 eyes in group A , other 4 in group B).Pyogenic granuloma occurred in 4 eyes (2 eyes in group A ,

other 2 in group B). No symblepharon was found in both groups. Dellen was found in 5 eyes (2 eyes in group A , other 3 in group B) and was treated by lubricants drops and gel for 4-6 weeks .Poor epithelial healing and superficial punctuate keratitis occur in 15 eyes ,7 in group A and 8 in group B , all of them treated with lubricants drops and gel , for 4 weeks , 2 of them needs contact lens wear for 2 months, Scleral thinning occur in 3 eyes, 1 in group A , 2 in group B . All these data showed no statistical difference between both groups

The recurrence rate in group A ,after 8 weeks was 3 eyes out of 40 (7.5 %), after 7 months another 2 eyes showed recurrence with total number of true recurrence(Grade 4) 5 eyes (12.5%), on the other hand the recurrence rate after 8 weeks in group B was 8 eyes out of 40 (20%) but after 6 months another 4 eyes showed recurrence so the total true recurrence rate (Grade 4) became 12 eyes out of 40 (30%) in group B (p value 0.045) (Table 2) (figure 3)

Table (2) Recurrence rate between two groups

Recurrence	Group A	Group B	P value
After 2 months	3	8	0.371
Between 2-9 months	2	4	0.179
Total	5	12	0.045**

Table (3): Total True recurrence rate after 9 months between the two groups

	Group A	Group B
Total No	40	40
True recurrence	5	12
Non recurrence	35	28

Table 4: The final appearance of the operated area after pterygium excision in both groups

	Group A	Group B
Total No	35	28
Grade 1	27(77%)	3(1%)
Grade 2	6(17%)	4(14%)
Grade 3	2(6%)	21(76%)

In group A, 5 eyes out of 40 showed complete recurrence (Grade 4) ,the rest 35 eyes showed no recurrence ,27 eyes showed grade 1(77%) , 6 eyes showed grade 2(17%) , 2 eyes showed grade 3(6%).

In group B 12 eyes out of 40 eyes showed complete recurrence (Grade 4) ,the rest 28 eyes showed no recurrence ,3 eyes showed grade 1(10%) , 4 eyes showed grade 2(14%) , 21 eyes showed grade 3(76%).(figure 4)

So in conjunctival autograft group (A) the operated area after pterygium removal was not different from the normal appearance in (77%)of non-recurrent cases .In comparison to amniotic membrane group (B) ,there were additional fibrovascular tissue in the excised area that not invade the cornea (grade 3)in (71%) of non-recurrent cases .

Regards to the 20 patients who underwent pterygium excision and MMC with conjunctival limbal autograft in one eye , and pterygium excision and MMC with amniotic membrane transplantation in the other eye, the recurrence rate in eyes with conjunctival limbal autograft was 2 eyes out of 20 (10%) , on the other hand the recurrence rate in eyes with amniotic membrane transplantation was 7 eyes out of 20 (35%), so this add to reproducibility of the research .

So the net results shows higher recurrence rate in amniotic membrane transplantation

than the conjunctival limbal autograft, even in the patients with no recurrence in amniotic membrane transplantation group the operated site showed residual of fibrovascular tissue not invaded the limbus (Grade 3) in (71 %) in comparison to conjunctival limbal autograft group the eyes with non-recurrence most of the eyes shows normal operated site appearance (Grade 1) in 70%.

Discussion

In our study the recurrence rate in group A was(12.5%) while in group B was (30%) , P value was 0.045 .Also in this study ,in group A, the operated area after pterygium removal was not different from the normal appearance (Grade 1) in (77%)of non recurrence cases while this percent was only (10%) in group B .

Our results were comparable to the result of the study done by Masters JS, Harris DJ Jr.; confirms that conjunctival autografts achieve the best result, with a recurrence rate of 13.3% at 6 months in a total of 120 eyes of both primary and recurrent pteriga [6].

Tananuvat N et al on 2004 did a study to compare the efficacy and safety of amniotic membrane transplantation as an adjunctive therapy after surgical excision of recurrent pterygium and to compare the clinical outcome with that of conjunctival autograft. Eighty-six eyes of 78 patients with primary pterygium were operated on by a single surgeon (N.T.). All patients were randomized to undergo amniotic membrane or conjunctival autograft transplantation as an adjuvant therapy after pterygium excision. Forty-four eyes in 39 patients were treated with amniotic membrane transplantation and 42 eyes of 41 patients were treated with conjunctival limbal autograft. Patients were followed up at 1 week, 1, 3, 6, and 12 months post operation.

The main outcome measurement was a recurrence rate after surgery. The mean follow-up was 14.40 +/- 5.4 months in the amniotic membrane transplantation group and 12.35 +/- 3.13 months in the conjunctival autograft group. There were 18 recurrences (40.9%) in the amniotic membrane group and two (4.76%) in the conjunctival autograft group, which was significantly different among both groups ($P < 0.007$). This results is comparable to our results [7].

The recurrence rates in our study were different from those found in a previous study in Japan done by Shimazaki et al ; 4.76% and 40.9% in conjunctival autograft and amniotic membrane graft groups, respectively, this is possibly due to the study sample difference in race[8].

In a study done by P Luanratanakorn et al done on 2006 included 287 eyes with either primary or recurrent. All eyes were randomised to undergo conjunctival limbal autograft or amniotic membrane transplantation after pterygium excision by a single surgeon. 106 eyes in primary pterygium and 14 eyes in the recurrent group were treated with conjunctival limbal autograft, and 148 eyes in primary pterygium and 19 eyes in the recurrent group were treated with amniotic membrane transplantation. Patients were followed up at 6 weeks and 6 months after operation. The total recurrence rate in the conjunctival group at 6 months was 13.3% (primary pterygium 12.3%, recurrent pterygium 21.4%), and that in the amniotic membrane group was 28.1% (primary pterygia 25.0%, recurrent pterygia 52.6%). Thus, at 6 months, amniotic membrane graft had significantly higher recurrence rate than conjunctival autograft ($p=0.003$;). The recurrence rate in the conjunctival

group in this study is higher than our study due to small number of patients with recurrent pterygium [9].

In 2007 Küçükerdönmez C et al performed a prospective, randomized clinical study of 78 eyes (78 patients) to compare the clinical results of conjunctival autograft and amniotic membrane transplantation for primary and recurrent pterygium excision. The patients were divided into 2 groups; forty eyes (28 with primary and 12 with recurrent pterygia) received conjunctival limbal autograft (group 1), and 38 eyes (27 with primary and 11 with recurrent pterygia) received AMT (group 2) after extensive removal of pterygium. Mean follow-up time was 16.6 +/- 3.52 months in group 1 and 13.4 +/- 2.08 months in group 2. The results were evaluated by clinical examination and photographing and final appearances were graded from 1 to 4. Recurrence rates of primary, recurrent, and all pterygia in group 1 and group 2 were 3.6%, 16.7%, and 7.5% and 3.7%, 18.2%, and 7.9%, respectively. There was no significant difference in recurrence rates between the 2 groups ($P = 1.00$ for all). The rates of final appearance as grade 3 were 10.0% in group 1 and 21.1% in group 2, and the difference was statistically significant ($P = 0.048$). No major complications occurred during the follow-up period .Although there is no difference in the recurrence rate between the two groups , the final appearance of the operated site was not different from the normal appearance was achieved using conjunctival autografting than with amniotic membrane transplantation. The difference in the recurrence rate between this study and our study may explained by the longer follow up period in this study up to 13 months and the study sample is mixed of primary and recurrent pterygia [10] .

In Conclusion :

In the present study, the conjunctival limbal autograft with intraoperative 0.02 %MMC appeared to be significantly more effective in terms of recurrence rate and final cosmetic appearance of the operated site than amniotic membrane transplantation with intraoperative 0.02 %MMC in recurrent pterygium. Therefore, we recommend the transplantation of conjunctival limbal autograft with MMC 0.02% as the preferred technique for surgery for recurrent pterygia.

References:

1. Wu B. Advances in pathogenesis of pterygium. *International Journal of Ophthalmology*. 2014;14(6):1058–1060.
2. Kurpakus-Wheater M, Kernacki KA, Hazlett LD. Maintaining corneal integrity how the "window" stays clear. *Prog Histochem Cytochem*. 2001;36(3):185-259.
- 3 Li X., Dai Y., Xu W., Xu J. Essential role of ultraviolet radiation in the decrease of corneal endothelial cell density caused by pterygium. *Eye*. 2018;32(12):1886–1892. doi: 10.1038/s41433-018-0188-y.
4. Sousa H. C. C., Silva L. N. P., Tzelikis P. F. Corneal endothelial cell density and pterygium: a cross-sectional study. *Arquivos Brasileiros de Oftalmologia*. 2017;80(5):317–320. doi: 10.5935/0004-2749.20170077
5. Prabhasawat P, Barton K, Burkett G, Tseng SC. Comparison of conjunctival autografts, amniotic membrane grafts, and primary closure for pterygium excision. *Ophthalmology*. 1997;104:974–85.
6. Masters JS, Harris DJ Jr. Low recurrence rate of pterygium after excision with conjunctival limbal autograft: A Retrospective Study With Long-Term Follow-Up. *Cornea*. 2015 Dec;34(12):1569-72.
7. Tananuvat N, Martin T. The results of amniotic membrane transplantation for primary pterygium compared with conjunctival autograft. *Cornea*. 2004 Jul;23(5):458-63.
8. Shimazaki J, Kosaka K, Shimmura S, Tsubota K. Amniotic membrane transplantation with conjunctival autograft for recurrent pterygium . *Ophthalmology* 2003;40: 119-124.
9. Luanratanakorn P, Ratanapakorn T, Suwan-Apichon O, Chuck RS. Randomised controlled study of conjunctival autograft versus amniotic membrane graft in pterygium excision *Br J Ophthalmol*. 2006 Dec; 90(12): 1476–1480.
10. Küçükerdönmez C, Akova YA, Altinörs DD. Comparison of conjunctival autograft with amniotic membrane transplantation for pterygium surgery: surgical and cosmetic outcome. *Cornea*. 2007 May; 26(4):407-13.
11. Saif ATS, Saif PS , El Deeb A. Role of amniotic membrane transplantation in symblepharon. *Guoji Yanke Zazhi(Int Eye Sci)* 2017;17(5):819-824