

The Effectiveness of Fractional CO₂ LASER in Treatment of *Striae Rubra* and *Striae Alba*: A Comparative Study

Delbent I Mabrouk, Azza E Mostafa, Islam R Hamed

Department of Dermatology, Venerology and Andrology, Faculty of Medicine, Ain Shams University

Corresponding author: Islam R Hamed, Mobile: 01142978441; Email: dr.islamrashad@gmail.com

ABSTRACT

Background: Striae distensae are a well-recognized, common skin condition that rarely causes any significant medical problems but are often a significant source of distress to those affected. The natural evolution of striae is from red or purple, raised wavy lesions (*striae rubra*) to white atrophic lesions with wrinkly surface (*striae alba*). **Aim of the Work:** was to compare the efficacy of the fractional CO₂ laser in the treatment of *striae rubra* versus *striae alba*. **Patients and Methods:** The present study included 20 patients above the age of 18 of both sexes; 10 patients had *striae rubra* and 10 patients had *striae alba*. They were recruited from Dermatology outpatient clinic in Ain Shams University Hospital from June 2017 to January 2018. 4 sessions of Fractional CO₂ Laser for each patient were performed one month apart. The treated striae were randomly selected from each patient (*Striae rubra* and *alba*) and were assessed before starting treatment, at the beginning of every session and one month after the last session as regards length, width, texture, color of striae and any complications encountered. **Results:** No significant difference was found on comparing the clinical response (improvement of color $P= 0.653$), (improvement of atrophy $P= 0.606$), side effects (Hyperpigmentation $P= 0.531$), (Pain $P=0.606$), (Hypopigmentation $P=0.305$), (Erythema $P= 0.060$), of both *striae alba* and *rubra* to the laser treatment. **Conclusion:** The present study showed significant clinical improvement in both types of striae distensae treated by Fractional CO₂ Laser with non-significant difference between the 2 groups except the development of erythema in *striae rubra* group. Furthermore, the histological improvement was significant for both groups with low incidence of the side effects. **Recommendations:** Larger scale studies with longer follow up period are recommended to further clarify the role of fractional CO₂ laser in treatment of striae distensae.

Keywords: fractional CO₂ Laser, treatment, *striae rubra*, *striae alba*.

INTRODUCTION

Striae distensae (SD) are frequent undesirable skin lesions that result in considerable aesthetic concern⁽¹⁾. SD are usually of a cosmetic concern; however if extensive, they may rupture in an accident. Recent or immature stria defined as linear bands of smooth skin which are erythematous or violaceous and may be itchy and slightly elevated. Such striae maintain their characteristics for a short period, usually approximately 6 to 10 months. In their later stage, they become white, flat, or depressed, and are more difficult to treat⁽²⁾.

The precise etiology and pathogenesis of striae have not yet been clearly explained⁽³⁾. They are commonly found during pregnancy, after a sudden gain or loss of weight, in Cushing's disease, in association with prolonged use of strong systemic or topical corticosteroids and due to rapid growth in adolescence with its consequent skin distention⁽⁴⁾. They are two and a half times more frequent in women and affecting up to 90% during pregnancy⁽⁵⁾.

The histopathologic findings vary according to the duration of these lesions. Recent striae show a deep and superficial perivascular

lymphocytic infiltrate and sometimes eosinophils, as well as dilated venules and edema in the upper part of the dermis. Whereas, fully developed mature lesions present a scanty lymphocytic infiltrate around the venules and reduced collagen bands in the upper third of the reticular dermis which are aligned parallel to the surface of the skin. Elastic fibers seem to be increased in number and grouped in sets as a consequence of the loss of collagen bands. In later stages, there is a thinning of the epidermis due to flattening of the rete ridges⁽⁴⁾.

In current practice, even with significant dermatologic advance in topical medications and light-based devices, total resolution of these lesions remains an unattainable goal. Al-Himadani et al.⁽⁶⁾ identified that no high-quality treatments for SD exist. Among the main options are topical tretinoin alone⁽⁷⁾, glycolic acid in conjunction with L-ascorbic acid or tretinoin⁽⁸⁾, pulsed dye laser, CO₂ laser, intense pulsed light (IPL) and the excimer laser^(1,4,9,10). It is also known that several lasers (585 nm collagen remodeling pulsed dye laser and 1,540 nm Er: Glass laser) have proven efficacy in the induction of new collagen formation^(11,12).

It has always been suggested that effective treatment of striae distensae should be instituted during the active stage, well before the scarring process is complete but the effect of fractional CO₂ laser has not been well studied as a treatment for both types of SD. So we aimed in our study to examine the effect of fractional CO₂ laser on the various types of SD to further specify its role in treatment of the various types.

The aim of this work was to compare the efficacy of the fractional CO₂ laser in the treatment of striae rubra versus striae alba.

PATIENTS AND METHODS

The present study included 20 patients above the age of 18 of both sexes; 10 patients had striae rubra and 10 patients had striae alba. They were recruited from Dermatology outpatient clinic in Ain Shams University Hospital from June 2017 to January 2018. An informed consent was taken from all subjects, and Dermatology Research Ethical Committee approval was taken.

Exclusion criteria:

- Pregnancy and lactation
- Diabetes
- Skin infection (viral, bacterial or parasitic)
- Patients with contraindications to CO₂ laser: Herpes simplex, lupus diseases, xeroderma pigmentosa, photosensitive epilepsy and hemophilia.
- Immunosuppressed patients or with history of malignancy or radiation therapy
- History of any previous surgical or cosmetic treatment

Patients included in this study were subjected to:

- A detailed medical history including Personal, present, past, medical, family, drug history and history of the disease (Personal history including name, age, sex, occupation, and residence. History of present illness included the onset, course, duration of the disease, predisposing factors and previous treatments. Past history of similar conditions and of other skin or systemic diseases, as well as family history of skin diseases was also checked for.
- General physical examination
- Dermatological examination was done to detect the type of striae, site and extent of the lesion. It includes lymph node and target lesions (Striae) for ulceration, scarring, scaling, erythema, pigmentation, inflammation and telangiectasia.
- Digital photography before treatment and after one month from the last session of treatment

- Skin biopsy was taken from the lesion before the start and after one month from the last Laser session
- 4 sessions of Fractional CO₂ Laser for each patient were performed one month apart
- The treated striae were randomly selected from each patient (Striae rubra and alba) and were assessed before starting treatment, at the beginning of every session and one month after the last session as regards length, width, texture, color of striae and any complications encountered.

Photography

All photographs were taken with a Canon Power Shot A495 digital camera (10 mega pixel resolution) using identical lighting situation and patient positioning. The photos were taken before starting treatment, at the beginning of every session and one month after the last session.

Histological Evaluation

- 3 mm punch biopsy was taken from the stria to be treated after local injection with 2% lidocaine. Each patient was instructed to use topical and/or systemic antibiotic after the biopsy taking. The lesion healed with secondary intention scar.
- Skin biopsies were collected in 10 % formal saline, processed into paraffin blocks and cut into 5 µm paraffin sections that were subjected to the following stains⁽¹³⁾:
 - Hematoxylin and eosin for histological evaluation.
 - Masson's Trichrome stain for collagen fibers.
 - Orcein stain for elastic fibers.

Laser Therapy

- We used the FIRE-XEL dynamic 3-way mode (Fractional CO₂ laser + CO₂ Laser + Skin analyzer), premium quality, various selectivity over 3000 scanning modes, human friendly design Laser from BISON medical equipment manufacturer in our study (fig. 1).
- Each patient had 4 sessions with 4 weeks intervals.
- The selected stria was treated along its entire length, avoiding overlapping pulses.
- Aiming to cool and protect the epidermis as well as to decrease the discomfort during laser treatment, an ice pack was applied immediately post treatment followed by topical antibiotic.
- The parameters of laser used in both groups were (power:1000, overlape:2, and distance:0.8).



Fig. (1): Fractional CO₂ laser equipment, Dermatology Laser Unit in Ain Shams University Hospital

Data management and statistical analysis

The data were statistically described in terms of mean ± standard deviation (±SD), median and range, or frequencies (number of cases) and percentages when appropriate.

Results:

I- Clinical and demographic data of the patients (Tables 1, 2):

The present study was designed to be an evaluative study of fractional CO₂ laser on treatment of striae rubra and striae alba using histological and clinical assessment. The present study included 20 patients above 18 of both sexes complaining of striae distensae.

There were classified into 2 groups:

Group I: include 10 patients with striae alba

Group II: include 10 patients with striae rubra.

Group I: The age in striae alba group ranged from 19-36 years with a mean ±SD of (28.900 ±4.581) years. Seven patients (70%) were females and 3 patients (30%) were males. The duration of striae varied from 1-8 years with a mean of (2.500 ±2.173) years. According to skin type, 7 patients were skin type IV (70%) and 3 patients were skin type III (30%). As for the treated site, 2 patients received treatment to the arm (20%), 2 patients received treatment to the abdomen (20%), 3 patients received treatment to the thigh (30%), 2 patients had treatment to the flank (20%), and 1 patient had treatment to the breast. Regarding to the possible cause, 5 patients attributed their striae to pregnancy (50%), 2 patients attributed their striae to use of systemic steroid (20%), 2 patients attributed it to weight gain (20%) and 1 patient attributed it to puberty growth (10%). **Table (1).**

Group II:

The age in striae rubra group ranged from 18-25 years with a mean of (20.000 ±2.108) years.

Seven patients (70%) were males and 3 patients (30%) were females. The duration of striae varied from 1-6 months, with a mean ±SD of (0.334±0.143) months. Regarding to skin type, 4 patients were skin type IV (40%), 5 patients were skin type III (50%) and 1 patient were skin type V (10%). According to the treated site, 5 patients received treatment to the arm (50%), 2 patients received treatment to the abdomen (20%), 2 patients received treatment to the leg (20%), and 1 patient received treatment to the chest (10%). Whereas, the possible cause was weight increase in 3 patients (30%), use of steroid both topical and/ or systemic was the cause in 4 patients (40%), pregnancy was the cause in 2 patients (20%) and 1 patient (10%) attribute his striae to body building.

Table (1).

Table (1): Clinical data in the studied groups.

	Group I		Group II	
	N	%	N	%
Skin type				
III	3	30%	5	50%
IV	7	70%	4	40%
V	0	0%	1	10%
Treated site				
Abdomen	2	20%	2	20%
Arm	2	20%	5	50%
Flank	2	20%	0	0%
Thigh	2	20%	0	0%
Leg	1	10%	2	20%
Breast	1	10%	0	0%
Shoulder	0	0%	1	10%
Possible cause				
Pregnancy				
Steroid	5	50%	2	20%
Puberty (growth)	2	20%	4	40%
Weight increase	1	10%	0	0%
	2	20%	3	30%
	0	0%	1	10%
Body building				

Final evaluation was done both clinically and histologically one month from the last session.

A) Clinical evaluation of striae (Figs. 2,3):

The treated striae were assessed as regards improvement of atrophy and the color.

Group I:

A significant improvement was reported as regards the color and atrophy of striae, 8 patients (80%) reported that their striae became tighter after the treatment, 5 patients (50%) reported that the color was improved after the treatment. **Figures 5 (A, B) and 6 (A, B)**

Group II:

Similarly a significant improvement was reported as regards the color and atrophy of striae, 7 patients (70%) reported that their striae became tighter after the treatment , 4 patients(40%) reported that the color was improved after the treatment . **Figures 7 (A, B) and 8 (A, B)**

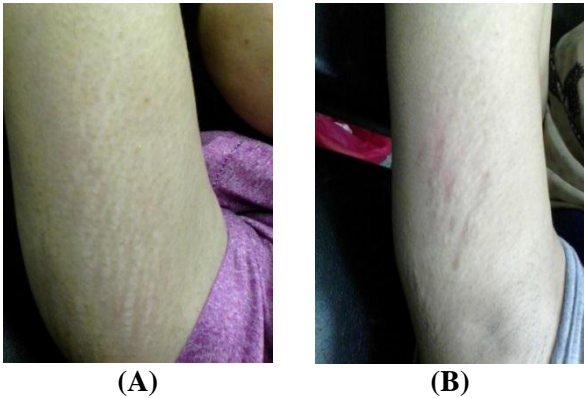


Fig. (2): A clinical photo for 26 year old female with stria alba in the arms (A) before start laser treatment (B) one month after the last session, reported an improvement in atrophy of the stria.

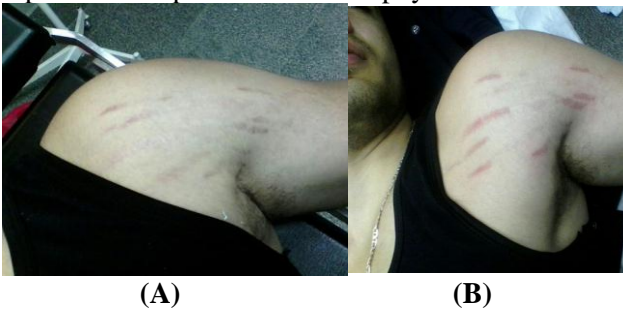


Fig. (3): A clinical photo for 18 year old male with stria alba in the chest (A) before start laser treatment (B) one month after the last session, reported an improvement in atrophy of the stria.

If we wait and see the patients of our study after several months from the last session, the result will be better as the final response is always latent and improvement continues over months.

B) Side effect of the laser during the treatment (Table 2):

The side effects observed in the present study were pain during the laser session, post inflammatory erythema, hyperpigmentation and hypopigmentation.

Group I

Two patients (20%) developed hyperpigmentation and one patient (10%) complained from pain during the session.

Group II

One patient (10%) developed hyperpigmentation, one (10%) developed hypopigmentation, three patients (30%) developed erythema and three patients (30%) complained from pain during the session.

Table (2): Side effects of the laser during the treatment

	Group I		Group II	
	N	%	N	%
Side effects				
Hyperpigmentation	2	20%	1	10%
Pain	2	20%	3	30%
Hypopigmentation	0	0%	1	10%
Erythema	0	0%	3	30%

C) Histological results

Histological evaluation using H&E stain, trichrome stain for collagen fiber and orcién stain for elastic fibers was performed to measure the quantity of collagen and elastic fibers.

Stria alba showed less collagen bundles mainly in the upper part of the reticular dermis with scanty cellular infiltrate around blood vessels, while elastic fibers were increased and grouped into sets. On the other hand, stria rubra showed deep and superficial perivascular lymphocytic infiltrate and dilated venules with loosely packed collagen bundles and thin branched elastic fibers.

Group I

Regarding stria alba, skin sections obtained from patients after treatment showed variable histological response. The elastic fibers were thin, branched and scattered all over the dermis in all patients.

Skin sections obtained from stria alba patients who showed clinical improvement revealed increase in dense closely packed collagen bundles in the upper reticular dermis that were running parallel to the skin surface in addition to the presence of small congested blood vessels (Figs 4,5).

Group II

Following laser treatment, the patients with striae rubra showed different histological changes that were relevant to their clinical response. In all patients, thin branched elastic fibers were detected in the dermis, and increase in dense *closely* packed collagen bundles in the upper reticular dermis with the presence of some cellular infiltrate around congested blood vessels (Figs 6,7).

Striae alba
H&E stain

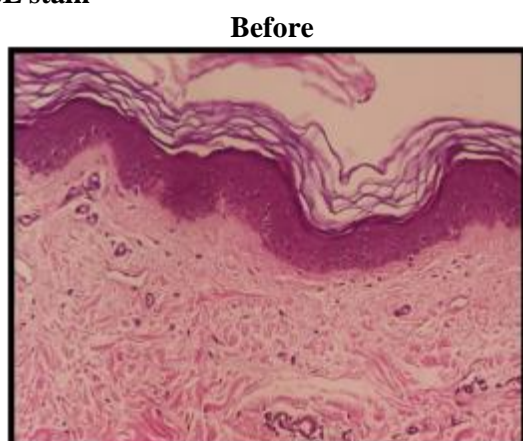


Fig. (4): Stria alba (before treatment) showing effaced epidermis with rete ridges pattern, reduced collagen bundles mainly in the upper part of the reticular dermis.

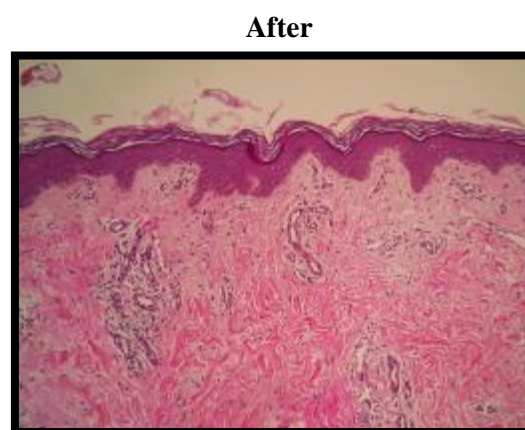


Fig. (5): Stria alba after treatment, showing normal epidermis with rete ridges pattern, dense closely packed collagen bundles in the dermis that run perpendicular to the skin surface. Note the presence of small congested blood vessels.

Striae Rubra
H & E

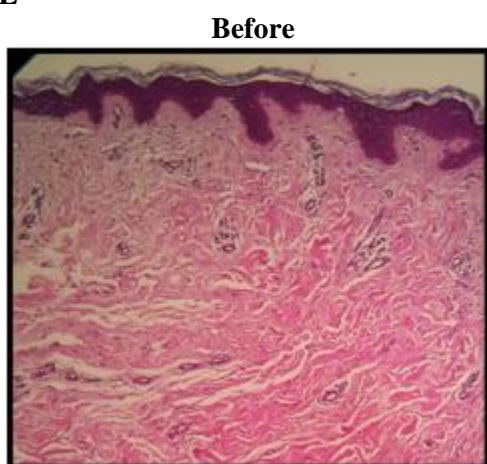


Fig. (6): Stria rubra (before treatment) showing showing effaced epidermis with rete ridges pattern, perivascular cellular infiltrate (arrow) around congested blood vessels in the upper part of dermis.

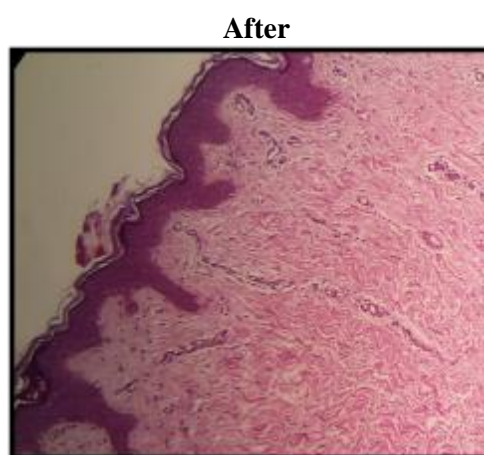


Fig. (7): Stria rubra after treatment, showing dense closely packed collagen bundles in the dermis and lower perivascular cellular infiltrate around congested blood vessels (arrow) in the dermis.

Comparison between striae groups

No significant difference was found on comparing the clinical response (improvement of color $P= 0.653$), (improvement of atrophy $P= 0.606$), side effects (Hyperpigmentation $P= 0.531$), (Pain $P=0.606$), (Hypopigmentation $P=0.305$), (Erythema $P= 0.060$), of both striae alba and rubra to the laser treatment.

DISCUSSION

Striae distensae are a well-recognized, common skin condition that rarely causes

significant medical problem but are often a significant source of distress to those affected⁽¹⁴⁾. Treatment of striae has always been challenging, although several treatments have been proposed, yet no consistent modality is curable. It has been suggested that effective treatment of striae distensae is instituted well during the active stage, before the scarring process is complete⁽¹⁵⁾.

Laser has become a popular therapeutic modality used to ameliorate striae, this includes pulsed dye, copper bromide, diode, long pulsed 1064-nm Nd-YAG, excimer, ablative and non-

ablative fractional (Co₂ and Er-YAG) laser. These modalities are available for treatment, yet none of them is consistently effective, and no single therapy is considered to be pivotal for this problem. With a high incidence and unsatisfactory treatments, striae remain an important target of research for an optimum consensus of treatment⁽¹⁶⁾.

Several studies tried to explain the mechanism by which the fractional CO₂ laser stimulate the collagen deposition. Prieto and colleagues⁽¹⁷⁾ showed that the laser induces expression of heat-shock protein 70 and type I procollagen by dermal dendritic cells. Weng and colleagues⁽¹⁸⁾ provided that the improvement of the antioxidant capacity {increase level of antioxidant enzymes, superoxide dismutase and glutathione peroxidase} after the laser treatment could stimulate new collagen production. Lee and colleagues⁽¹⁹⁾ provided that the laser increase the expression of transforming growth factor-beta with subsequent activation of fibroblast and deposition of new collagen. Yee and colleagues⁽²⁰⁾ found significant increase in expression of tissue inhibitors of metalloproteinases and decrease in expression of matrix metalloproteinases after the laser treatment.

The present study was designed to evaluate the fractional CO₂ laser in the treatment of both striae alba and rubra using histological and image analysis studies.

Twenty adult patients of both sexes were enrolled in our study classified into 2 groups; 10 patients had striae alba and 10 had striae rubra. Patients were subjected to 4 sessions with 4 weeks interval and a follow up period of one month after the last session. A 3-mm punch biopsy was taken from stria to be treated before treatment and one month after the last session, all biopsies were subjected to histological examination.

The present study showed significant clinical improvement in striae appearance for both striae alba and striae rubra. Three patients of striae rubra patients showed decrease erythema. Also 8 patients with striae alba and 7 with striae rubra expressed increase tightness of the their skin at the end of study. There was change in the length and width of striae in both groups.

Several studies were in agreement with the present study regarding the clinical improvement using different types of laser^(21, 22, 23, 24,25).

Jimenez and colleagues⁽²¹⁾ studied the effect of PDL on 20 female patients with skin type II-VI who had striae alba and rubra. They found that the laser had a moderate beneficial effect in reducing the degree of erythema in striae rubra with no apparent clinical change in striae alba.

Longo and colleagues⁽²²⁾ studied the effect of copper-bromide 577-nm laser on 15 female patients with skin type I-III who had striae alba and rubra. They found that the laser was effective in decreasing the size of the striae, a finding which we also report.

Goldman and colleagues⁽²³⁾ studied the effect of long pulsed 1064-nm Nd-YAG laser on 20 female patients with skin type II-IV who had striae rubra. They concluded that the clinical improvement of striae could obtain with the laser and the full clearance of the lesion was very rare. And agreement with De Angelis and colleagues⁽²⁴⁾ studied the effect of fractional non-ablative 1540-nm Er: glass laser on 51 female patients with skin type II-IV who had striae alba and rubra. They found that 50% or greater improvement in all patients could be obtained at six months or longer after the last session.

Lee and colleagues⁽²⁵⁾ studied the effect of fractional CO₂ laser on 27 female patients with skin type IV who had striae alba. They concluded that the laser had a positive therapeutic effect. In contrast, Tay and colleagues⁽²⁶⁾ studied the effect of the 1,450-nm diode laser on 11 Asian female patients with skin types IV-VI who had striae alba and striae rubra. They concluded that the laser had no therapeutic effect.

In our study, treatment was tolerated well by all patients where side effects were minimal, mostly pain during the session in 5 patients (2 alba and 3 rubra), post inflammatory hyper-pigmentation in 3 patients (2 alba and 1 rubra) and post inflammatory hypo-pigmentation in one patient with striae rubra. These side effects were statistically non-significant for striae both groups. The laser was safe in patients included in the present study, similar results were found by Goldman and colleagues⁽²³⁾ who used the long pulsed 1064-nm Nd-YAG, De Angelis and colleagues⁽²⁴⁾ who used the fractional Er: glass and Lee and colleagues⁽²⁵⁾ who used the fractional CO₂ laser, they concluded the safety of their laser. On the other hand Jimenez and colleagues⁽²¹⁾ and Tay and colleagues⁽²⁶⁾ did not recommend their laser (PDL, diode laser respectively) in patients with dark skin for fear of post inflammatory hyper-pigmentation.

The histological findings in the present study support our explanation of the clinical improvement; the collagen fibers were increased and closely packed in the upper reticular dermis in patients who achieved improvement in the texture and loosely packed in non-improved patients with striae alba. In striae rubra patients persistent congested blood vessels were detected which explained clinically =y persistence of erythema.

The histological findings in the present study are in agreement with Jimenez and colleague⁽²¹⁾ (who used PDL) and De Angelis and colleagues⁽²⁴⁾ (who used fractional 1540-nm Er:glass). They found increase in collagen fibers (by hydroxyprolin assay, H&E and orcién stain respectively) after treatment with their laser and they concluded that the histological changes could precede the significant clinical improvement.

Moreover, Dayan and colleagues⁽²⁷⁾ studied the histological changes in pig skin by H&E, Verhoeff-van Gieson stain after weekly irradiation with the long pulsed Nd:YAG for 4 weeks. They found a significant increase in the reticular dermal collagen and non-significant decrease in elastic fibers in irradiated biopsies.

Conclusion and Recommendations

The present study showed significant clinical improvement in both types of striae distensae treated by Fractional CO₂ Laser with non-significant difference between the 2 groups except the development of erythema in striae rubra group. Furthermore, the histological improvement was significant for both groups with low incidence of the side effects.

Larger scale studies with longer follow up period are recommended to further clarify the role of fractional CO₂ laser in treatment of striae distensae.

REFERENCES

1. **McDaniel DH (2002):** Laser therapy of stretch marks. *Dermatol Clin.*, 20:67–76.
2. **Tsuji T, Sawabe M (1988):** Elastic fibres in striae distensae. *J. Cutan. Pathol.*, 15:2150–7.
3. **Sheu HM, Yu HS, Chang CH (1991):** Mast cell degranulation and elastolysis in the early stage of striae distensae. *J Cutan Pathol.*, 18:410–30.
4. **Hernandez-Perez E, Charrier EC, Valencia-Ibiert E (2002):** Intense pulsed light in the treatment of striae distensae. *Dermatol Surg.*, 28:1124–30.
5. **Chang AL, Agredano YZ, Kimball AB (2004):** Risk factors associated with striae gravidarum. *JAAD.*, 51:881–5.
7. **Elson ML (1990):** Treatment of striae distensae with topical tretinoin. *J Dermatol Surg Oncol.*, 16:267–70.
8. **Ash K, Lord J, Zukowski M et al. (1998):** Comparison of topical therapy for striae alba (20% glycolic acid/0.05% tretinoin versus 20% glycolic acid/10%l-ascorbic acid). *Dermatol Surg.*, 24: 849-56.
9. **Alster TS (1997):** Laser treatment of hypertrophic scars, keloids and striae rubra. *Dermatol Clin.*, 15:419-29.
10. **Goldberg DJ, Marmur ES, Hussain M (2003):** 308 nm excimer laser treatment of mature hypopigmented striae. *Dermatol Surg.*, 29:596–9.
11. **Fournier N, Dahan S, Barneon G et al. (2001):** Nonablative remodeling: clinical, histologic, ultrasound, imaging, and profilometric evaluation of a 1,540 nm Er:Glass laser. *Dermatol Surg.*, 27:799–806.
12. **Michel JL (2003):** 585 nm collagen remodelling pulsed dye laser. *J Cosmet Laser Ther.*, 5:201–3.
13. **Kiernan JA (2008):** *Histological and Histochemical Methods: Theory and Practice.* Kiernan JA ed. Bloxham, UK: Scion, 4th edition,
14. **Osman H, Rubeiz N, Tamim H et al. (2007):** Risk factors for the development of striae gravidarum. *Am J Obstet Gynecol.*, 196:62–85.
15. **Elsaie ML, Baumann LS, Elsaie LT (2009):** Striae distensae (stretch marks) and different modalities of therapy: an update. *Dermatol Surg.*, 35:563-73.
16. **Yang YJ, Lee GY (2011):** Treatment of Striae Distensae with Nonablative Fractional Laser versus Ablative CO₂ Fractional Laser: A Randomized Controlled Trial. *Ann Dermatol.*, 23:481-489.
17. **Prieto VG, Diwan AH, Shea CR et al. (2005):** Effects of intense pulsed light and the 1,064 nm Nd:YAG laser on sun-damaged human skin. *Histologic and immunohistochemical analysis.* *Dermatol Surg.*, 31:522-5.
18. **Weng Y, Dang Y, Ye X et al. (2011):** Investigation of irradiation by different nonablative lasers on primary cultured skin fibroblasts. *Clin Exp Dermatol.*, 36: 655-60.
19. **Lee YB, Kang NH, Eun YS et al. (2012):** Effects of long-pulsed 1,064-nm neodymium-doped yttrium aluminum garnet laser on dermal collagen remodeling in hairless mice. *Dermatol Surg.*, 38:985-92.
20. **Yee X, Wang L, Dang Y et al. (2012):** Investigation of the 1064 nm Q-switched Nd:YAG laser on collagen expression in an animal model. *Photomed Laser Surg.*, 30:604-9.
21. **Jimenez GP, Flores F, Berman B et al. (2003):** Treatment of striae rubra and stria alba with the 585-nm pulsed-dye laser. *Dermatol Surg.*, 29:362–4.
22. **Longo M, Postiglione MG, Marangoni O et al. (2003):** Two-year follow-up results of copper bromide laser treatment of striae. *J Clin Laser Med Surg.*, 21:157-60.
23. **Goldman A, Rossato F, Prati C (2008):** Stretch marks: treatment using the 1,064-nm Nd:YAG Laser. *Dermatol Surg.*, 34:686-91.
24. **De-Angelis F, Kolesnikova L, Renato F et al. (2011):** Fractional nonablative 1540-nm laser treatment of striae distensae in Fitzpatrick skin types II to IV: Clinical and histological results. *Aesthet Surg J.*, 31:411-9.
25. **Lee SE, Kim JH, Lee SJ et al. (2010):** Treatment of striae distensae using an ablative 10,600-nm carbon dioxide fractional laser: A retrospective review of 27 participants. *Dermatol Surg.*, 36:1683-90.
26. **Tay YK, Kwok C, Tan E (2006):** Non-ablative 1,450-nm diode laser treatment of striae distensae. *Lasers Surg Med.*, 38:196–9.
27. **Dayan S, Damrose JF, Bhattacharyya TK et al. (2003):** Histological evaluations following 1,064-nm Nd:YAG laser resurfacing. *Lasers Surg Med.*, 33:126-31.