

Ewing's Sarcoma of Temporal Bone: Case Report

⁽¹⁾ Alakeel, Abdurahman Mansour, ⁽²⁾ Aldajani N, ⁽²⁾ Shami I M, ⁽³⁾ Orz Y

1. College of Medicine, King Saud University, 2. King Fahad Medical City (KFMC), Riyadh,

3. Alexandria University and King Fahad Medical City (KFMC), Riyadh

Corresponding author: Abdurahman Alakeel, E-mail: abdurahman.alakeel@gmail.com

ABSTRACT

Primary Ewing's Sarcoma (ES) is a small round tumor, more likely to present in long bones and rarely in skull bones. ES commonly present in the second decade of life, and it is usually treated by multi-modality including surgery, chemotherapy, and radiotherapy. In this case, a 13 years old boy presented with left facial palsy and hearing loss for two weeks, treated with steroid but no improvement. MRI was done and showed left jugular foramen and cerebellopontine mass measuring 4.8*4.4* 3 cm. Debulking surgery of the tumor was done with multiple biopsies reported by histopathology as malignant small round cell tumor consistent with Ewing sarcoma.

Keywords: Ewing's Sarcoma, Temporal Bone, Case Report.

INTRODUCTION

Primary Ewing Sarcoma (ES) is small round cell tumor of neuroectodermal origin ^{1,2}. the second most common malignant bone tumor in young patients ^{3,4,5}. It is more likely to affect long bones, pelvic bones, ribs, and vertebrae ^{1,2,5,6,7,8} and present most commonly in the second decade of life ^{2,3,4,5,7}. Primary ES of the skull is rare ^{3,4,6,7,9} and appears in different bones, the most common site is temporal bone ^{2,3}, as in this present case.

CASE REPORT

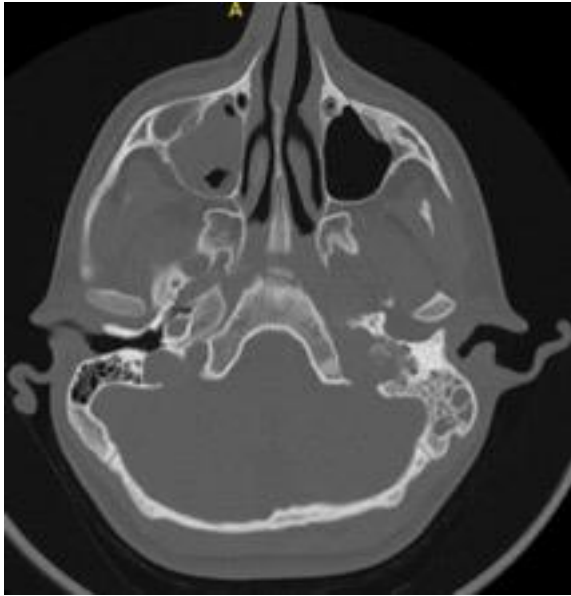
Our patient is 13 years old boy who was referred to our tertiary hospital with a history of left facial palsy and hearing loss for two weeks. He was treated in the referring hospital with systemic steroid with no improvement on follow up. There were no associated symptoms of dizziness, tinnitus, otalgia, headache, change of voice or chocking. On the examination of the left ear, there was a reddish intact tympanic membrane with a normal external auditory canal. Cranial nerve examination showed normal II-VI, IX, XI, and XII cranial nerves; VII cranial nerve showed left facial palsy grade 6 on House Brackmann grading system. X cranial nerve exam showed left vocal cord paralysis. His hearing assessment showed normal hearing in the right ear with a profound hearing loss in the left ear. Middle ear function using tympanogram showed type C in the diseased ear with normal type A on the non-affected side. Stapedial reflexes showed present right ipsilateral reflex and absent right contralateral, left ipsi- and contralateral reflexes.

CT scan showed left jugular foramen and cerebellopontine mass with bony erosion (Figure 1,2) and sunburst appearance in soft tissue window (Figure 3). MRI showed left jugular foramen and cerebellopontine mass measuring 4.8*4.4* 3 cm in maximum dimension. It was isointense on T1 and T2 weighted images with avid post contrast enhancement with evidence of restricted diffusion within the mass (Figure 4-7). The mass destroyed the petrous apex and medial portion of the jugular foramen with the extension into the petroclival junction and anteriorly along the dura with compression of the Meckel's cave.

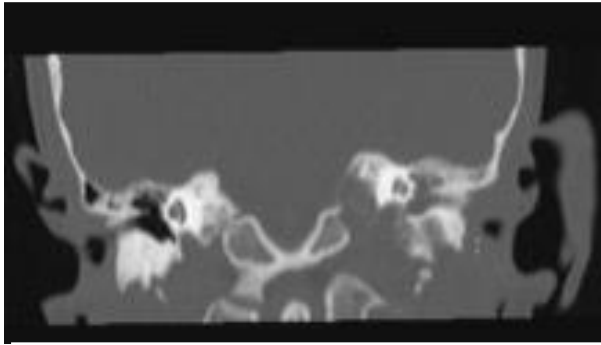
MR angiogram of the intracranial vasculature appears unremarkable with patent vessels and normal perfusion on MR perfusion scan. The radiological differential diagnosis was going with aggressive tumor such as hemangiopericytoma, round blue cell category tumor, and least likely glomus jugulare tumor. CT chest, abdomen and pelvis together with PET scan showed no metastasis.

We took the patient to the operating room together with our colleague from neurosurgery, and we perform left transcochlear approach type A and debulking of the tumor with intraoperative fresh-frozen biopsy which showed Ewing sarcoma. Intraoperatively the tumor was infiltrating the bone in the mastoid cavity, middle and inner ear.

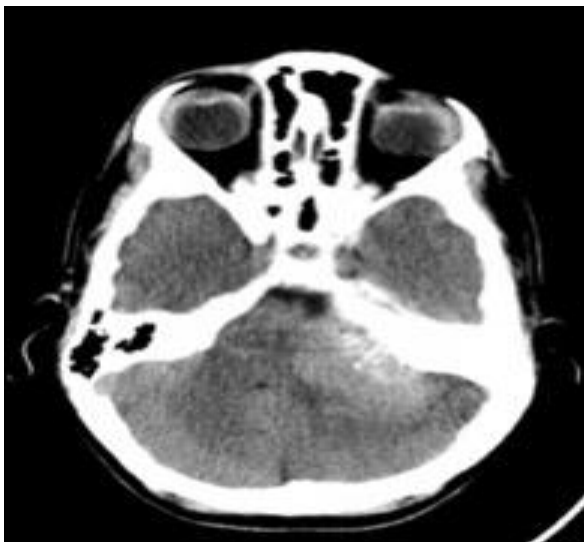We took multiple biopsies from the middle ear, jugular foramen, brain tumor and mastoid bone and the final histopathology came as malignant small round cell tumor consistent with Ewing sarcoma for all (Figure 8,9). Postoperatively patient received concurrent chemoradiotherapy.



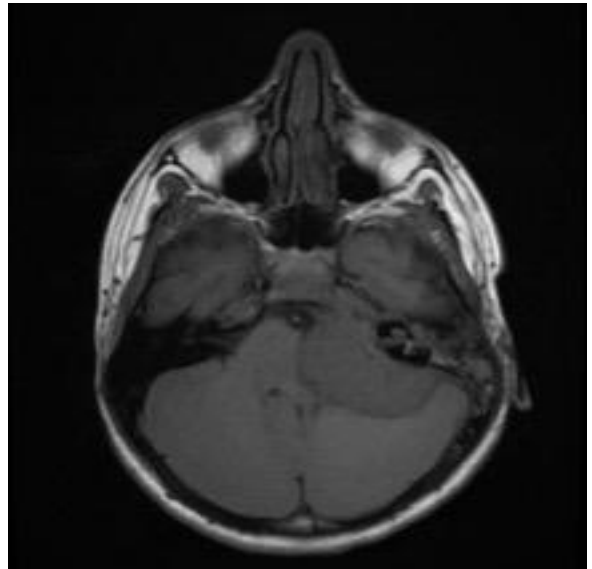
(Figure 1) Axial CT showing the extension of the tumor through left jugular foramen with bony



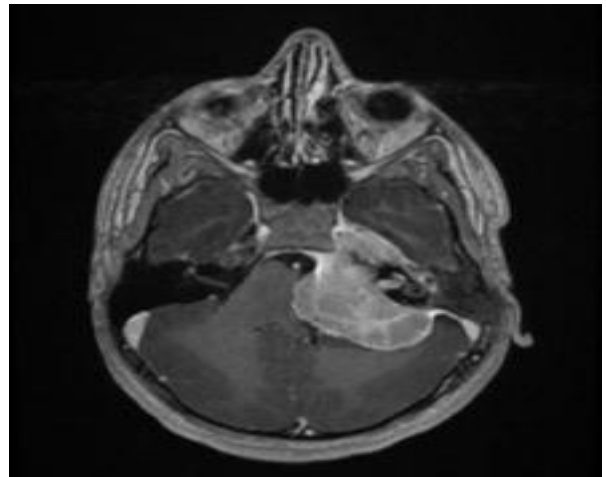
(Figure 2) Coronal CT showing the extension of the tumor through left jugular foramen with bony erosion.



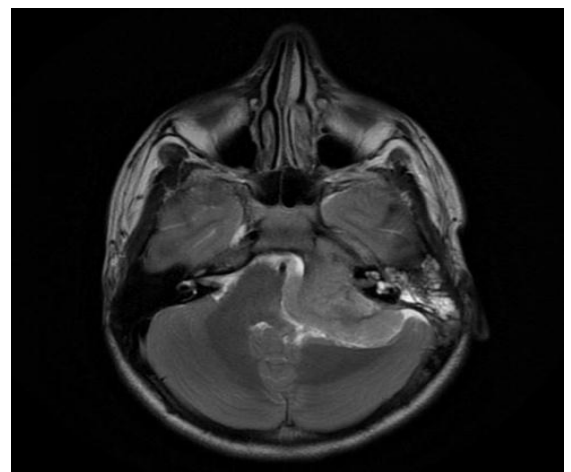
(Figure 3) Axial CT with soft tissue window showing the sunburst appearance.



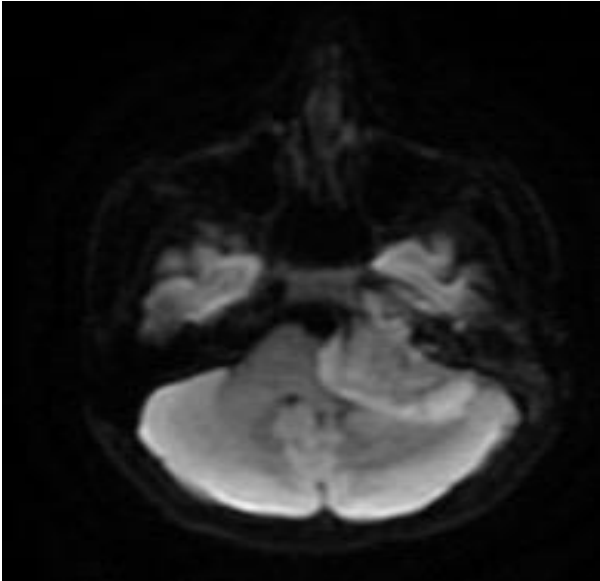
(Figure 4) T1 MRI with isointense mass occupying the left cerebellopontine angle



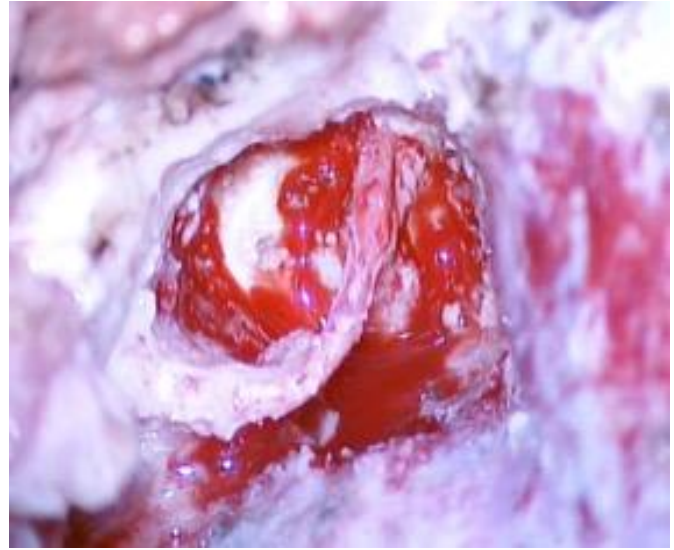
(Figure 5) T1 MRI with contrast showing post contrast enhancement of the left cerebellopontine angle tumor



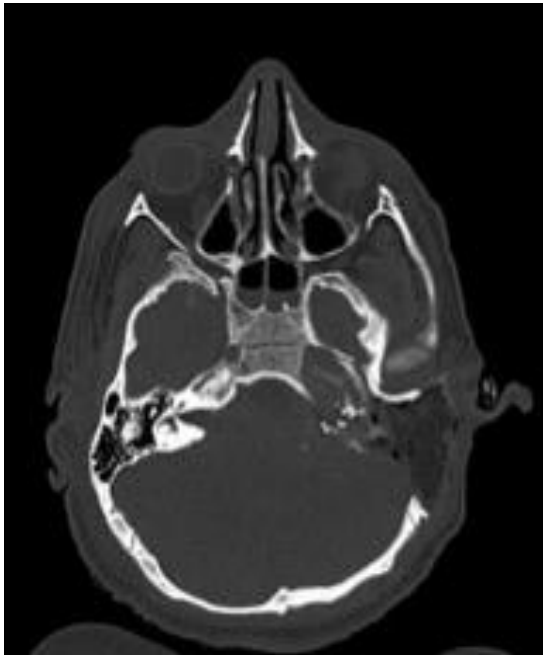
(Figure 6) T2 MRI with isointense mass occupying the left cerebellopontine angle



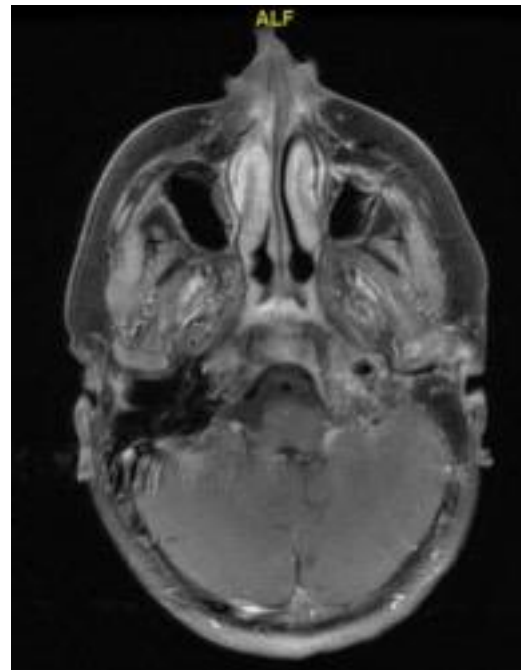
(Figure 7) Diffusion weighted images sequence showing restricted diffusion in the tumor.



(Figure 8) Intraoperative picture showing dissected facial nerve after completing the bone



(Figure 9) Post-operative Axial CT showing removal of the temporal bone with fat obliteration.



(Figure 10) One year Postoperative MRI T1 with contrast Fat suppression showing regression of the tumor size

DISCUSSION

Primary Ewing Sarcoma (ES) is small round cell tumor of neuroectodermal origin^{1,2} and should be differentiated from other round cell tumors like lymphoblastic lymphoma, desmoplastic small round cell tumor, rhabdomyosarcoma, neuroblastoma and small cell carcinoma^{1,7}.

ES is the second most common malignant bone tumor in young patients^{3,4,5} even though it accounts for only 1% of all childhood cancers⁸. Primary ES is more likely to affect long bones, pelvic bones, ribs, and vertebrae^{1,2,5,6,7,8} presented most commonly in the second decade of life^{2,3,4,5,7} with a male to female ratio of 1.6:1^{1,3,5,7}.

Primary ES of the skull is rare and account for 1–9% of all Ewing's sarcomas^{3,4,6,7,9} others like Krishnamani said it is even less than 1%¹⁰. Primary ES of the skull present in different bones, the most common site is temporal bone followed by frontal, occipital, parietal and less frequent ethmoid and sphenoid^{2,3}.

In the literature, headache, localized swelling, and signs of raised intracranial pressure were the most common symptoms of skull ES^{1,3,5,6,7,9}, this could be explained as they found that, the Intracranial extension was present in the majority of primary cases of the skull ES⁴. The main presentation of ES in the temporal bone was facial paralysis, hearing loss and ear discharge^{5,7}. Even though it may differ from case to case depending on the location and spread of the tumor, but some researchers did not find significant difference in the presentation of primary and metastatic tumors⁵.

Due to disease nature, as it displays a rapid growth, early diagnosis has favorable outcomes^{2,3,5}. Diagnosis of ES mainly relies on histopathology and immunohistochemistry⁵, histopathology is considered the gold standard¹. The main histological features include round cells arranged in the form of solid strata, scanty cytoplasm, protruding nuclei, mitoses, and the presence of bony structures^{1,5,8}.

ES is characterized by a sensitive and relatively specific antigen, CD99/MIC2, and chromosomal translocation t(11; 22)(q24; q12)^{1,3,7}. ES differs from neuroblastoma, rhabdomyosarcoma, lymphoma, etc. by the absence of expression of synaptophysin, desmin, leukocyte antigen, and other markers⁷. Radiology study is used to help in diagnosis and evaluation of the

tumor. The most common CT finding is isodense lesion with marked heterogenous enhancement². Pure lytic changes (58%) and honeycombing (21%) are more common among these patients than other primary Ewing sarcoma patients⁴. Also, the periosteal reaction is a rare radiographic appearance in primary ES cases that involve the bones of the head and neck⁴.

ES treatment goes through a multidisciplinary approach that includes surgery, chemotherapy, and radiotherapy^{2,3,5,8}. The main reason for surgery is reducing the tumor bulk⁵. Some suggest that Radical excision is a must and have paramount importance³. Chemotherapy has a massive effect in the treatment as ES responds to chemotherapeutic regimens, such as vincristine and cyclophosphamide. The introduction of actinomycin D and doxorubicin in the above regimen demonstrated improved survival^{3,7}. Multi-drug chemotherapy as per the round cell therapy (RCT) II includes three weekly cycles of ifosfamide, etoposide, vincristine, cyclophosphamide, doxorubicin and/or actinomycin D. Radiotherapy with a total body dose of 40-50 Gy is recommended^{5,7}. In children, conventional radiation therapy is usually reserved for partially excised tumors or patients with no response to chemotherapy due its long-term effect on them³.

In term of ES prognosis, even with treatment through a multidisciplinary approach, the outcome of ES remains complex, mainly due to its aggressive nature and the propensity for distant metastases⁵. In case of ES of the skull base primary tumors has a more favorable course as compared to the metastatic tumor^{5,7}.

Even, metastasis from primary skull Ewing's sarcoma very rare^{3,6,8}. There are some factors which worsen the prognosis such as the presence of metastasis at the time of diagnosis, also, if the age older than ten years and low efficiency of chemotherapy⁷.

Early diagnosis and treatment before metastasis are essential for long-term survival in a patient with Ewing sarcoma. This patient was kept for follow up and had no symptoms. In conclusion, primary cranial Ewing's sarcoma should be considered in the differential diagnosis in children with a tumor involving the skull with the destruction of bone and the presence of extra-axial soft tissue involvement.

CONCLUSION

Primary Ewing Sarcoma (ES) is a small round tumor. It is the second most common malignant bone tumor in young patients. It has characteristic CT and MRI appearance. Although the incidence is low but keeping a high index of suspicion is essential for early diagnosis and thus intervention for the best outcome.

REFERENCES

1. **Kaushik A, Sirswal S, Gupta K, Kolte S, Arora D(2015):** Primary Ewing sarcoma of scalp diagnosed on cytology: A rare case report . *Ann Appl Bio-Sciences*, 2(4):0-2.
2. **Mukherjee T, Rappai TJ, Chaudhary GS, Mukherjee D(2015):** Ewing's Sarcoma of Sphenotemporal Bone of skull: A Rare Presentation. *Int. Res. J. Basic Clin. Stud.*, 3(1):9-12.
3. **Moschovi M, Alexiou GA, Tourkantoni N, Balafouta M-E, Antypas C, Tsiotra M et al.(2011):** Cranial Ewing's sarcoma in children. *Neurol Sci.*,32(4):691-4.
4. **Kawano H, Nitta N, Ishida M, Fukami T, Nozaki K(2016):** Primary pericranial Ewing's sarcoma on the temporal bone: A case report. *Surg Neurol Int* ..,7(16):S444-8.
5. **Rana K(2015)** Ewing's Sarcoma Multifocal Metastases to Temporal and Occipital Bone: A Rare Presentation. *J Clin Diagnostic Res.*, 9(6):MD04-MD05.
6. **Nandi M, Bhattacharya J, Goswami S, Goswami C(2015)** Primary Ewing's sarcoma of the squamous part of temporal bone in a young girl treated with adjuvant volumetric arc therapy. *J Cancer Res Ther.*, 11(4):1015.
7. **Cherekaev VA, Kushel' Iu V, Shkarubo AN, Mukhametzhanov Dz, Stepanian MA, Rotin DL et al.(2013):** Primary and metastatic Ewing sarcoma of the skull base - case reports and comparative analysis. *Zh Vopr Neurokhir Im N N Burdenko* ,77(1):30-6.
8. **Goudarzipour K, Shamsian S, Alavi S, Nourbakhsh K, Aghakhani R(2015):** Primary Ewing ' s Sarcoma of the temporal bone in an infant. *Int J Hematol Oncol Stem Cell Res.*, 9(2):104-106.
9. **Jaiswal S, Jaiswal P, Ojha BK, Chandra A.(2016)** Primary Ewing sarcoma of squamous temporal bone with intracranial extension: a case report. *Rom Neurosurg* ,30(2):33-36.
10. **Krishnamani K, Kumar T, Gandhi L, Raghunadharao D, Sadashivudu G, Megha U(2014)** Primary Ewing's sarcoma of the cranium: Case series and review of literature. *J Cancer Res Ther* ..,10(2):377.