

Squamous Cell Carcinoma Presenting as Cutaneous Horn: A Case Report

Samaher Alauldeen¹, Khalid Al Hawsawi², Haneen Al Sufyani³, Lina Bugis⁴,
Ayat Al Dosari⁵, Taghreed Al Hetairshi⁶

1- Al-Noor Specialist Hospital, Makkah, Saudi Arabia, 2- Dermatology Department King Abdul Aziz Hospital Makkah, Saudi Arabia, 3- King Abdul Aziz Hospital Makkah, Saudi Arabia, 4- Umm Al Qura University Makkah, Saudi Arabia, 5- Makkah, Saudi Arabia, 6- Makkah, Saudi Arabia

ABSTRACT

Background: Cutaneous horn is a clinical term used to describe a hard, keratotic conical lesion. Its base may be a papule, plaque or nodule.

Objectives: An approach for how to diagnose and manage a cutaneous horn.

Materials and methods: Here-in we report an aged male 85-years old presented with a history of painful slowly progressive skin lesion over his right foot 7 months ago.

Results: The past medical history revealed that the lesion was preceded by presence of a cutaneous horn (CH) at the same site of the current skin lesion. That CH was persistent for a year before it spontaneously fell down. Skin biopsy from the base of the CH was taken at that time, it was consistent with underlying actinic keratosis. He did not receive any treatment for his CH. Currently skin examination revealed fungating ulcer measuring 6X6 cm on the dorsum of the right foot. There was no inguinal lymphadenopathy. Punch skin biopsy was taken from the edge of the ulcer for histo-pathological examination.

Conclusion: On the basis of the above clinicopathological findings, a diagnosis of well differentiated Squamous Cell Carcinoma was made. The patient was referred to Oncologist for appropriate management.

Keywords: Cutaneous horns, Cornu Cutaneum, Squamous Cell Carcinoma, Ulcer.

INTRODUCTION

Cutaneous horn is a clinical term for a hard, keratotic conical lesion. It occurs commonly in sun exposed sites such as face, eyelid, ear, neck and dorsal aspects of hands^[1]. The histopathology of horn is unique in its vertically oriented column of massive hyperkeratosis, parakeratosis and variable acanthosis usually in association with atypical keratinocytes of an actinic keratosis^[2]. Other lesions that are associated with cutaneous horns include such seborrheic keratosis, histocytoma, viral warts, molluscum contagiosum, epithelial neoplasms especially tricholemmomas, Bowen's disease, squamous cell carcinoma (SCC), Basal cell carcinoma, granular cell tumor, metastatic renal carcinoma, sebaceous carcinoma or Kaposi sarcoma^[1-5].

The study was done after approval of ethical board of King Abdulaziz Hospital.

CASE REPORT

An aged male 85-years old presented with a history of painful slowly progressive skin lesion over his right foot 7 months ago.

The past history revealed that the lesion was preceded by presence of a cutaneous horn (CH) at

the same site of the current skin lesion. That horn was persistent for a year before it spontaneously fell down. Skin biopsy from the base of the CH was taken at that time. It was consistent with the underlying actinic keratosis. He did not receive any treatment for his CH. Review of systems was unremarkable. Family history revealed no history of malignancy in the family. Skin examination revealed fungating ulcer measuring 6X6 cm on the dorsum of the right foot (figure 1). No inguinal lymphadenopathy was detected.

Punch skin biopsy was taken from the edge of the ulcer. The epidermis revealed full-thickness atypical keratinocytes with downward proliferation of lobules of atypical keratinocytes deep into the dermis. The nuclei of these keratinocytes showed some degree of pleomorphism and mitoses. Also, there were keratin pearls and moderately dense lymphohistiocytic cellular infiltrates in-between the epithelial lobules in the dermis (figure 2).

On the basis of the above clinicopathological findings, a diagnosis of well differentiated squamous cell carcinoma was made. The patient was referred to Oncologist for appropriate management.

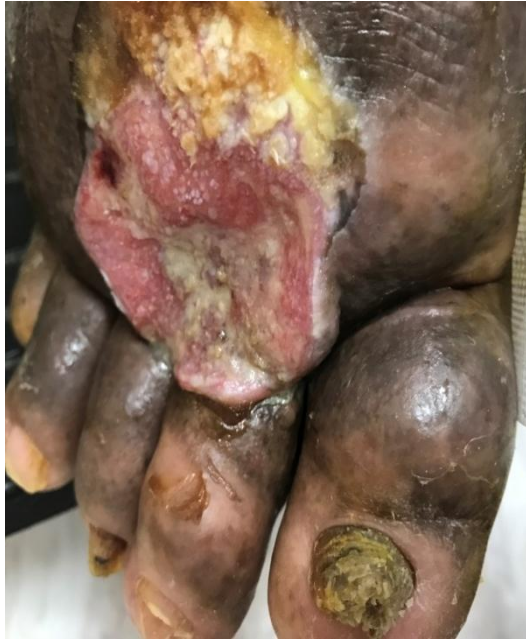

Figure 1. Fungating ulcer measuring 6X6 cm on the dorsum of the right foot.

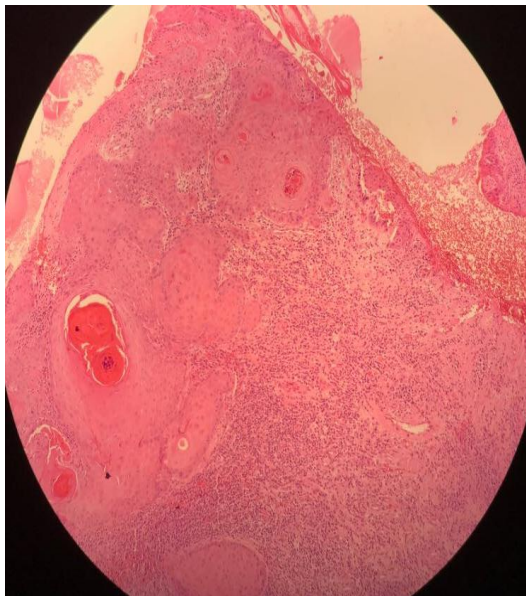


Figure 2. The epidermis revealed full-thickness atypical keratinocytes with downward proliferation of lobules of atypical keratinocytes deep into the dermis. The nuclei of these keratinocytes show some degree of pleomorphism and mitoses. There were also keratin pearls and moderately dense lymphohistiocytic cellular infiltrates in-between the epithelial lobules in the dermis.

DISCUSSION

Cutaneous horn (CH), known by the Latin name (Cornu Cutaneum), is a rare and uncommon skin lesions. It was first described by Kaposi^[4]. The term horn is a morphologic designation referring to well-defined, cone-shaped, hyperkeratotic nodule that project above the surface of the skin, ranging in size from a few millimeters to many centimeters that resembles a miniature horn^[1-5]. The underlying cause of the CH is usually benign. However, ruling out the

underlying malignant and premalignant causes is crucial.

The presence of full-thickness atypical keratinocytes of the epidermis overlying the invasive SCC in our patient indicates that the SCC in our patient was secondary to actinic keratosis. Our patient was neglected before and did not receive any treatment for the actinic keratosis that was underneath his CH. So his actinic keratosis progressed to SCC, The results

of our case report are in agreement with similar case reports in the literatures^[2-3].

Treatment of the horn depends on the underlying cause. Malignancy is present in 16-20% of cases, with squamous cell carcinoma being the most common^[2-7].

Shave excision is the recommended method of the management. Shave excision must be deep enough to allow the pathologist to evaluate the dermis. An elliptical excision can be performed, especially if the base is nodular or indurated. Local destruction after shave or elliptical excisions is the most favorable treatment for the benign and premalignant conditions^[8-9].

REFERENCES

- 1-Nthumba P (2007): Giant cutaneous horn in an African woman: a case report. *Journal of medical case reports*, 1: 170.
- 2-Kumar S, Bijalwan P and Saini S (2014): Carcinoma buccal mucosa underlying a giant cutaneous horn: a case report and review of the literature. Hindawi Publishing Corporation. *Case reports in oncological medicine*, 214:518372.
- 3-Fernandes N, Sinha S, Lambert W and Schwartz R (2009): Cutaneous horn: a potentially malignant entity. *Acta Dermatoven Alp Panonica Adriat*, 18: 189-193.
- 4-Tauro L, Martis J, John S and Kumar P (2006): Cornu cutaneum at an unusual site. *Indian Journal of Plastic Surgery*, 39: 76.
- 5-Wollina U and Schönlebe J (2010): Giant keratoacanthoma-like cutaneous horn of the upper leg: A case report. *Acta Dermatoven Alp Panonica Adriat*, 19: 29-30.
- 6-Copcu E, Sivrioglu N and Culhaci N (2004): Cutaneous horns: are these lesions as innocent as they seem to be? *World journal of surgical oncology*, 2: 18.
- 7-Oludiran O and Ekanem V (2011): Cutaneous horns in an African population. *Journal of Cutaneous and Aesthetic Surgery*, 4: 197.
- 8- Mantese S, de Oliveira D, Priscila M, Rocha A, Alceu L, Ferreira Ana K and Ferreira T (2010): Cutaneous horn: a retrospective histopathological study of 222 cases. *Anais brasileiros de dermatologia*, 85: 157-163.
- 9-Leelavathy B, Kemparaj T, Sathish S and Khadri S (2015): Squamous cell carcinoma arising from a giant cutaneous horn: A rare presentation. *Indian Journal of Dermatology*, 60: 107.