

Role and Incidence of Parasitic Infection in Adult Egyptian Patients with Acute Appendicitis

Ahmed M. Bayoumy¹, Adel O. Seif Elnasr¹, Ibrahim A. Ibrahim²,
Salah- EL-din S. Semary³, Mahmoud R. Mohamed¹.

¹ Department of Parasitology, Faculty of Medicine (boys), Al-Azhar University, Cairo,

² Department of General Surgery, Faculty of Medicine (boys), Al-Azhar University, Cairo,

³ Department of General Pathology, Faculty of Medicine (Damietta), Al-Azhar University, Egypt

Corresponding author: Ahmed Bayoumy, E-mail: drahmedbayoumy@azhar.edu.eg

ABSTRACT

Background: Appendicitis is the most important acute surgical condition of the abdomen, and appendectomy constitutes one of the most common surgical operations worldwide. Many factors can cause appendicitis but the intestinal parasitic infections are one of the most important causes.

Objective: The present study aimed to evaluate and detect the role and incidence of various parasitic infections in appendectomy specimens from Egyptian adult patients with acute appendicitis attending the General Surgery Emergency room at Al-Azhar University Hospitals, Cairo, Egypt (Al-Husseini and Sayed Galal Hospitals).

Patients and methods: The present study was carried out on 200 patients undergoing appendectomy with a provisional diagnosis of acute appendicitis during the period from December 2015 to November 2016. The removed appendices were fixed in 10% buffered formalin, sectioned, stained with H&E and examined for histopathological changes and presence of parasites. Stool examination was also done by direct smear, formol ether concentration techniques as well as CBC examination for all patients.

Results: Stool examination revealed 120 (60%) out of the total 200 appendectomy patients were positive for parasitic infections, while CBC examination revealed leucocytosis among 167 (83.5%), and eosinophilia in 40 (20%) as well as anemia in 43 (21.5%) in all the studied patients. Histopathological examination revealed parasitic infections in 6 (3%) of appendectomy specimens. The presence of *E. vermicularis* worms and their eggs as well as *Schistosoma* ova were observed in 4 (2%) and 2 (1%) of cases respectively. Features of acute suppurative appendicitis were observed in 143 (71.5%) of cases, of which, 98 (49%) cases had luminal obstruction by fecalith and 45 (22.5%) showed patent lumen. Non suppurative appendicitis were presented in 57 cases (28.5%) which included lymphoid hyperplasia in 21 cases (10.5%) and neuronal hyperplasia in 6 cases (3%) as well as granulomatous appendicitis with features consistent with appendiceal Crohn's disease (CD) in 30 cases (15%). **Conclusion:** The study concluded that parasitic infections constitute 3% of the surgically removed appendices where *Schistosoma* eggs and *E. vermicularis* (adults and eggs) were the parasites recorded. So differential diagnosis of parasitic infections in the etiology of acute appendicitis should be made properly which can save patients from a negative laparotomy, morbidity and even mortality.

Keywords: Appendicitis, *Enterobius vermicularis*, *Schistosoma* species, Histopathology, Parasitic infection, Stool and CBC examination.

INTRODUCTION

Appendicitis is the most common cause of acute abdominal pain that requires surgical treatment. The prevalence of appendicitis is reported to be around 7%. It is more common in males than females (1.4:1) and can be seen at any age but it is more commonly seen in older children and in young adults. It is more common in urban, industrialized societies and relatively rare in developing countries where a less-refined, high-fibre diet is typically consumed. Presumably, the diet in industrialized countries leads to hard stool, higher intra colonic pressure and formation of fecaliths that can serve as obstructing agents in the appendiceal lumen¹. The cause of acute appendicitis is unknown but is probably multifactorial; luminal obstruction, dietary and familial factors have all been suggested². Faecal

stasis, fecaliths, lymphoid hyperplasia and foreign bodies are the most common cause of appendiceal obstruction¹. Another important cause of appendicitis is parasitic infection but the actual role as co-factor in appendicitis is still to debate. There is little evidence regarding the relationship between parasites and acute appendicitis. In even tropical countries, where intestinal parasitic infection is quite common, appendiceal disease is not unusual³. Obstruction of the appendiceal lumen can occur with parasites and their eggs. If the lumen is obstructed, continued secretion and proliferation of bacteria or the parasites may cause an increase in the intra luminal pressure. Increased pressure impairs the circulation of the wall and mucosal damage may cause bacterial invasion, inflammation, sepsis and finally necrosis and perforation⁴. Most prominent parasitic agents

reported to be related with appendicitis are *Enterobius vermicularis*, *Schistosoma* spp, *Trichuris trichura*, *Taenia* spp, *Ascaris lumbricoides* and *Entamoeba histolytica* ³. Pinworm is considered the most common helminthic infection postulated with acute appendicitis and varies from 0.2% to 41.8% worldwide ⁵.

Eggs of *Schistosoma mansoni* have been found in the lumen of the appendix leading to transmural inflammation, granulomatous reactions and purulent exudates. Sometimes, the fibrosis that follows the infection causes a luminal obstruction and later secondary bacterial appendicitis ⁶. *Trichuris trichura* can be asymptomatic but can be visible in the stool and they can cause rectal prolapse and appendicitis ⁷. Appendicitis due to ascariasis can be diagnosed by Ultrasound that shows long filling defects in the right iliac fossa ³. *Entamoeba histolytica* may stay in the appendix ⁸ as well as protoglotids of the adult tapeworms, *Taenia saginata* and *Taenia solium* which may be found in the lumen of the appendix ⁹.

PATIENTS AND METHODS

The present study was carried out during the period from December, 2015 to November, 2016 where a total of two hundred (200) patients with clinical manifestations of appendicitis underwent appendectomy at General Surgery Departments of Al-Hussein and Sayed Galal University Hospitals, Faculty of Medicine, Al-Azhar University, Cairo, Egypt. Right Macberny incision was done, followed by delivery of the caecum, devascularisation of the appendix, base ligation and removal. After appendectomy, each appendix was immediately preserved in 10% formalin in a clean container labelled and transported to the laboratory. The patient's consent was obtained before surgery as per norm. Data for each patient was recorded. All the specimens delivered to the laboratory were examined after obtaining consent from the institutional ethical committee.

Histopathological evaluation

All appendectomy fixed materials were sampled longitudinally in the distal parts and cross-sectionally in the other parts. After overnight tissue processing of specimens, 4 microns (µm) sections were prepared and stained with hematoxylin and eosin (HE) ¹⁰ then examined.

Stool samples were collected from each patient in a clean container, labelled and examined by direct smear method after staining with iodine and formol ether concentration techniques¹¹. Venous blood samples were also collected and analyzed by

an automated hematology cell counter analyzer (DIAGON® D-cell 60 hematology analyzer).

RESULTS

Among the two hundred patients suffering from acute appendicitis, 126 (63%) were males and 74 (37%) were females. The age of them was ranging from 18 to 70 years. Stool examination revealed positive parasitic infection among 120 (60%) of them and the distribution of infection was presented in **table (1)** and **figure (1)** as *E. histolytica* 43(21.5%), *E. vermicularis* 15(7.5%), *Fasciola* sp.2(1%), *G. lamblia* 10 (5%), *S. mansoni* 7(3.5%), *T. trichiura* 1(0.5%), *A. lumbricoides* 19 (9.5%), *Taenia* sp 2(1%) and mixed infection 21(10.5%). Moreover, CBC revealed, leucocytosis among 167 (83.5%), eosinophilia in 40 (20%) and anemia in 43 (21.5%) in all studied patients as seen in **table (2)** and **figure (2)**.

Regarding to histopathological results, extensive transmural neutrophilic infiltrate, edema, congested vessels and mucosal necrosis with intra luminal sloughing were observed in 143 cases (71.5%) and were diagnosed as acute suppurative appendicitis. Among them, 98 (49%) had luminal obstruction by fecalith and 45 (22.5%) had patent lumen. Non suppurative appendicitis were presented in 57 cases (28.5%) which included lymphoid hyperplasia in 21 cases (10.5%) and neuronal hyperplasia in 6 cases (3%) as well as granulomatous appendicitis with features consistent with appendiceal Crohn's disease (CD) in 30 cases (15%).

Parasitic infection was detected in 6 specimens (3%) out of the total (200) investigated cases, see **figure (3)**. Four patients of them (2%) were positive for (*E. vermicularis* and their eggs) and one of these four cases (0.5%) had acute appendicitis and peri-appendicitis with extensive neutrophilic infiltrate and focal perforation. The other 3 cases (1.5%) had lymphoid hyperplasia and patchy eosinophilic infiltrate in the appendiceal wall. The worms were located in the lumen of all of the positive cases without wall invasion. *Schistosoma* ova surrounded by granulomatous reaction were detected in 2 cases (1%) showing extensive wall fibrosis and marked luminal narrowing, see **table (3)** and **figures (4 & 5)**. Of all the investigated cases, 23 of them (11.5%) showed focal perforation of the appendiceal wall, 85 (42.5%) had edematous wall, 35 (17.5%) accompanied with fibrosed wall and the remaining 57 cases (28.5%) were grossly and histologically normal, see **figure (6)**.

Table (1): Distribution of the parasitic infections among investigated patients

Stool Analysis	No.	%
Negative	80	40.0%
Positive	120	60.0%
<i>E. histolytica</i>	43	21.5%
<i>E. vermicularis</i>	15	7.5%
<i>Fasciola</i> sp.	2	1.0%
<i>G. lamblia</i>	10	5.0%
<i>S. mansoni</i>	7	3.5%
<i>T. trichura</i>	1	0.5%
<i>A. lumbricoides</i>	19	9.5%
<i>Taenia</i> sp.	2	1.0%
Mixed infection	21	10.5%
Total	200	100.0%

Table (2): Results of CBC examination

	No.	%
Leucocytosis:		
Absent	33	16.5%
Present	167	83.5%
Eosinophilia:		
Absent	160	80.0%
Present	40	20.0%
Anemia:		
Absent	157	78.5%
Present	43	21.5%

Table (3) : Distribution of histopathological examination of appendices

		No.	%
Inflammatory changes	Negative	7	5%
	Positive	43	5%
Parasitic infections	Negative	94	0%
	Positive	5	0%
	➤ <i>E. vermicularis</i>	4	0%
	➤ <i>Schistosoma</i> sp	2	0%

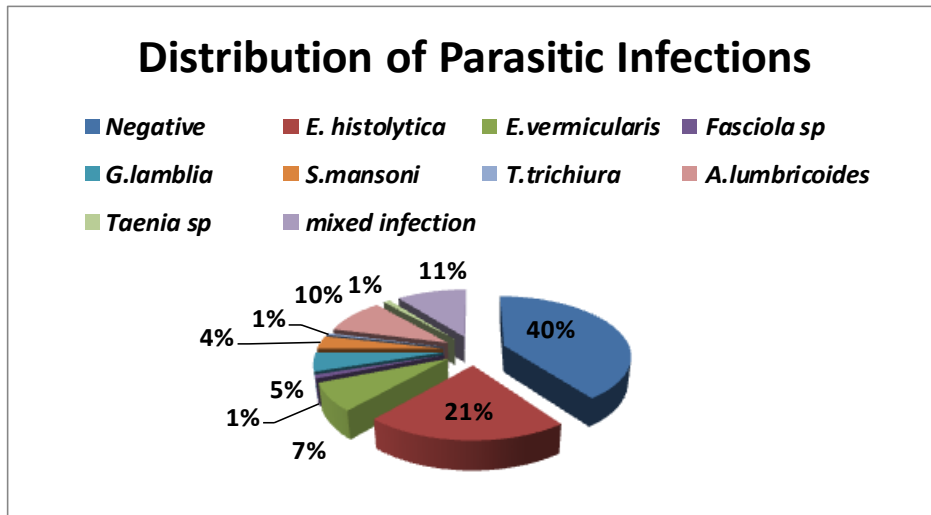


Figure (1): Distribution of the parasitic infections among investigated patients

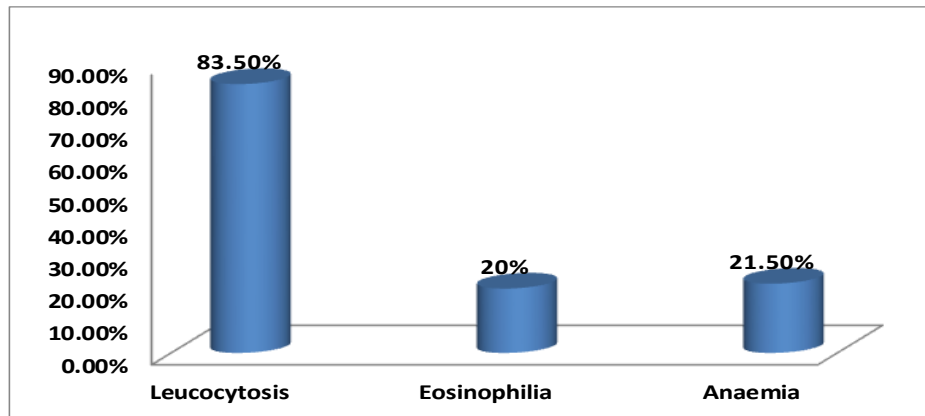


Figure (2): Results of CBC examination

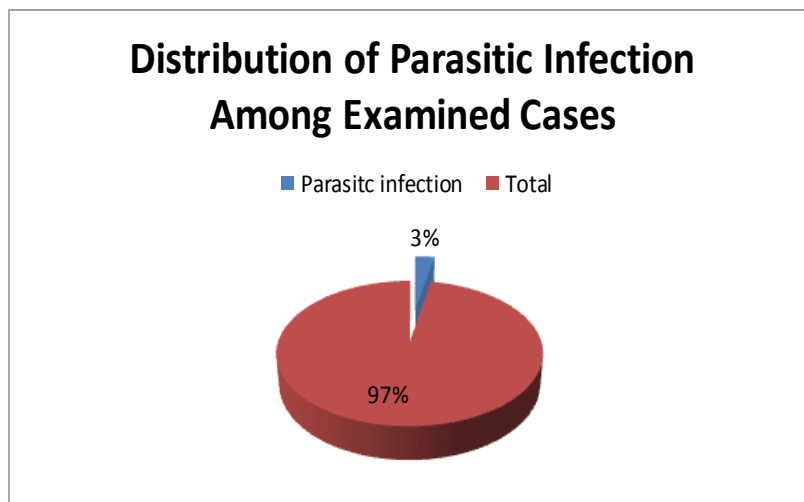


Figure (3): Distribution of parasitic infection among examined cases

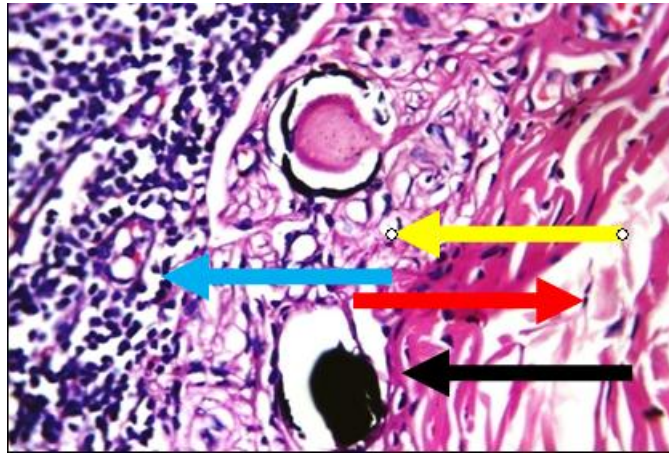


Figure (4): Light photo micrograph of high-power view showing markedly edematous submucosa (red arrow), infestation with fresh (yellow arrow) and calcified bilharzial ova (black arrow), and marked inflammatory infiltrate (blue arrow) (H&E X 360)

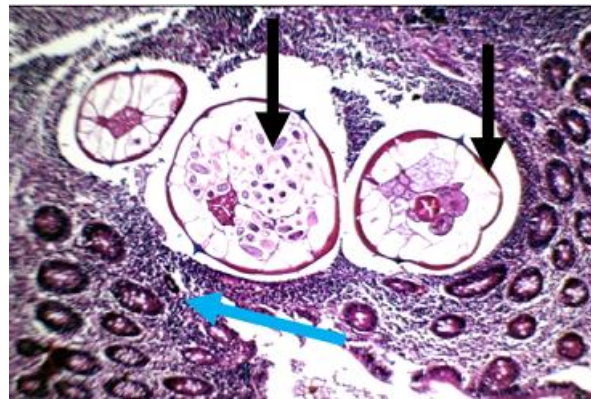


Figure (5): Light photo micrograph of medium-power view showing marked edema and inflammatory cellular infiltrate (blue arrow) and 3 parasites (*E.vermiculais*) invading mucosa and surrounded by clear zone "parasitophorus vacuole" (black arrows) (H&E X 235).

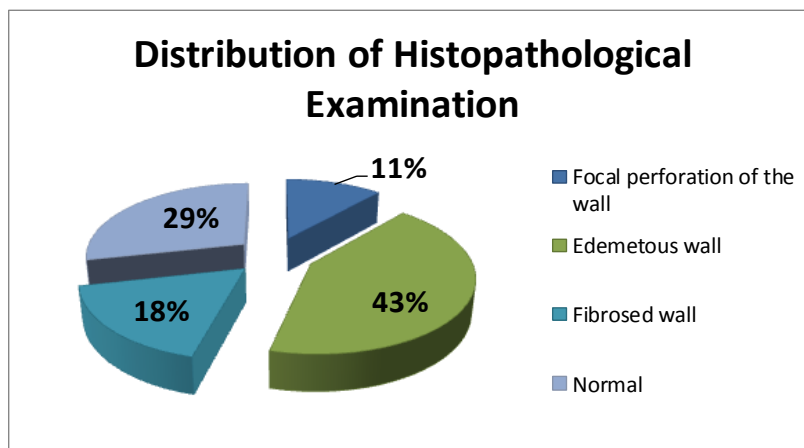


Figure (6): Distribution of histopathological examination

DISCUSSION

Appendicitis is the most common acute surgical circumstance of the abdomen and appendectomy is one of the most common surgical operations worldwide ¹. It is commonly associated with obstruction (50-80% of cases), usually due to a fecalith, gallstone, tumor, presence of *Enterobius vermicularis* and diffuse lymphoid hyperplasia. Obstruction causes increased intraluminal pressure, collapse of draining veins, ischemia, mucosal injury and ulceration, bacterial overgrowth which lead to more edema and more ischemia. However, not all cases show clear evidence of lumen obstruction ⁴.

The current study was performed on two hundred patients suffering from acute appendicitis attending the General Surgery Departments at Al-Hussein and Sayed Galal University Hospitals. Out of them 126 (63%) were males and 74 (37%) were females. The male: female ratio was (1.7: 1) which coincided with that obtained by **Yabanoglu *et al.*** ¹² (1.6: 1) and **Yildirim *et al.*** ¹³ (1.7:1). In contrast, **Helmy *et al.*** ¹⁴ and **Zakaria *et al.***, ¹⁵ reported that the male: female ratio among patients previously diagnosed with appendicitis in Cairo was (1:2) and (1:1.2), respectively.

Features of acute suppurative appendicitis were observed in 143 (71.5%) cases, of which, 98 (49%) had luminal obstruction by fecalith and 45 (22.5%) had patent lumen. Non suppurative appendicitis were presented in 57 cases (28.5%) which included lymphoid hyperplasia in 21 cases (10.5%) and neuronal hyperplasia in 6 cases (3%) as well as granulomatous appendicitis with features consistent with appendiceal Crohn's disease (CD) in 30 cases (15%) which coincided with that obtained by **Yabanoglu *et al.*** ¹² and **Dorfman *et al.*** ³. Of all the investigated cases, 23 of them (11.5%) showed focal perforation of the appendiceal wall, 85 (42.5%) had edematous wall, 35 (17.5%) accompanied with fibrosed wall and the remaining 57 cases (28.5%) were grossly and histologically normal.

Parasitic infection was detected in 6 appendectomy specimens (3%). The presence of *E. vermicularis* worms and their eggs were observed in 4 cases (2%). *Schistosoma* ova were also

detected in 2 cases (1%). These results are coincided with that obtained by **Yabanoglu *et al.*** ¹²

who reported that among 1159 operated patients as acute appendicitis, parasitic infections were seen in 17 (1.4%) patients where *E. vermicularis* was determined in 15 cases (88.2%) and *E. histolytica* in 2 cases (11.7%) of them. Moreover **Zakaria *et al.*** ¹⁵ reported that the ratio was 5.5% and the parasitic infections were (51.1%) enterobiasis, (9.1%) schistosomiasis, (26.1%) ascariasis, (8%) trichuriasis, and (5.7%) taeniasis.

In India, **Jada *et al.*** ¹⁶ detected a wide spectrum of parasitic infections (32%) in one hundred surgically removed appendices which included *A. lumbricoides* (18%), *E. vermicularis* (6%), *A. duodenale* (4%), *Taenia* sp. (2%), *T. colubriformis* (1%) and *T. trichiura* (1%).

In Egypt, **Hedya *et al.*** ¹⁷ reported that the retrospective study of appendectomies revealed 11 out of 251(4.38%) having parasitic infections distributed as *E.vermicularis* (1.59%), *A. lumbricoides* (0.79%), *Schistosoma* sp. eggs (1.19%) and amoebiasis (0.79%).

Also, **Abdellatif *et al.*** ¹⁸ reported that out of 100, surgically removed appendices in Minia University Hospital the presented parasites were *E. vermicularis* (3%), bilharzial granulomas (3%) as well as *A. lumbricoides*, *A. duodenale* and *H. nana* (1% for each).

In another study in Cairo city, **Helmy *et al.*** ¹⁴ reported that parasites were detected in 14.8% of surgically removed appendices.

The present identification of *E. vermicularis* worms in 2% of cases coincided with reported results by **Arca *et al.*** ¹⁹ in USA and **Ramezani and Dehghani**, ²⁰ (2.9%) in Iranian population. In Turkey, several studies recorded the presence of *E. vermicularis* in 3.15% of surgically removed appendices from a Turkish population ²¹ while in Nepal, *E. vermicularis* was identified in 1.62% of Nepalese patients with clinically diagnosed appendicitis ²².

The wide range of these percentages indicates that the association between *E. vermicularis* and appendicitis differs from country to another. This can be explained on the basis that parasitic diseases

affect four billion individuals worldwide, especially in communities that have lower hygiene, sanitation, socio economic status, and education as well as living conditions.

According to stool analysis, 120 cases (60%) were identified as having one or more of the following parasites, *E. histolytica* (21.5%), *G. lamblia* (5.0%), *S. mansoni* (3.5%), *E. vermicularis* (7.5%), *Fasciola* (1.0%), *T. trichura* (0.5%), *Taenia specie* (1.0%) *A. lumbricoides* (9.5%) and mixed infection (10.5%). This agrees with **Mousa et al.**²³ and **Bayoumy et al.**²⁴ who detected high prevalence rate of parasitic infection in Egyptian patients reaching 67%. At the same time these results agreed, with a study in Kenya recorded by **Obala et al.**²⁵ (52.3%) and a study in Ethiopia recorded by **Abate et al.**²⁶. On the other hand these results are higher than that recorded by **Abed et al.**,²⁷ in Qalubia Governorate (24.7%), **Deepesh et al.**²⁸ in India (16.8%) and **Kheirandish et al.**²⁹ in Iran. Also these results were higher than **Ibrahim**,³⁰ who reported that the prevalence of parasitic infection among Egyptian patients in El-Minia Governorate villages in Upper Egypt was 39.3%. However, the present results were less than that reported in Upper Egypt by **El-Masry et al.**³¹ who reported that the prevalence of parasitic infections among Egyptian patients in rural area in Sohag Governorate villages were 88.5%. These differences could be attributed to the locations of the studies, the season of the year of the study was carried out and the method of stool analysis.

The high prevalence of parasitic infections in the present study suggested a generally low standard of living and poor environmental sanitation in the study area and confirmed that intestinal parasitic infection was a common problem in Egypt.

Among the infected 120 cases, 26 (21.7%) of them had anemia, 108 (90%) had leucocytosis and 40 (33.3%) had eosinophilia. There was statistically significant increase in leucocytosis and eosinophilia as regards stool analysis ($P < 0.05$). The ratio of eosinophilia was lower than that obtained by **Meeusen and Balic**,³² who found that 81% of helminthic infections associated with eosinophilia. Also, **Demirci**,³³ who found that 63 % of parasite infected patients had eosinophilia. This difference

because in the present study some parasites that detected in the stool live in intestine only without migration to body tissues.

CONCLUSION

It can be concluded that infections of the appendix by schistosomiasis and enterobiasis are important agents in the pathogenesis of appendicitis in Egypt. Differential diagnosis of parasitic infections as etiology of acute appendicitis should be in mind and this attention can save patients from a negative laparotomy and morbidity and even mortality. Detection and treatment of intestinal parasites should be done regularly to avoid future complications that may necessitate surgical interference.

REFERENCES

- 1-Humes DJ and Simpson J (2006):** Acute appendicitis. Br. Med. J., 333: 530-534.
- 2-Flasar MH and Goldberg E (2006):** Acute abdominal pain. Med. Clin. North Am., 90:481-503.
- 3-Dorfman S, Cardozo J, Dorfman D and Villar DA (2003):** The role of parasites in acute appendicitis of pediatric patients. Invest. Clin., 44:337-340.
- 4- Akbulut S, Tas M, Sogutcu N, Arikanoglu, Basbug M, Ulku A et al . (2011):** Unusual histopathological findings in appendectomy specimens: a retrospective analysis and literature review. World J Gastroenterol., 17:1961-1970.
- 5-Marjorie JA, Robert LG, Jonathan IG, Sue H and Donna AC (2004):** Clinical manifestations of appendical pinworms in children: an institutional experience and a review of literature. Pediatr. Surg. Int., 20:372-375.
- 6-Okolie BI, Okonko IO, Ogun AA, Adedeji AO, Donbraye E, Nkang AO, Ihekanwa CI and Onwuchekwa EC (2008):** Incidence and detection of parasite ova in appendix from patients with appendicitis in South-eastern, Nigeria. W. J. Agri. Sci., 4:795-802.
- 7-Ok KS, Kim YS, Song JH, Lee JH, Ryu SH, Lee JH, Moon JS, Whang DH and Lee HK (2009):** *Trichuris trichiura* infection diagnosed by colonoscopy:case reports and review of literature. Korean J Parasitol., 47: 275-280.
- 8-Tan ZN, Wong WK, Nik Zairi Z, Abdullah B, Rahmah N, Zeehaida M,Rumaizi S, Lalitha P, Tan GC, Olivos-Garcia A and Lim BH (2010):** Identification of *Entamoeba histolytica* trophozoites in fresh stool sample: comparison of three staining techniques and study on the viability period of the trophozoites. Trop. Biomed., 27: 79-88.

- 9-Sartorelli AC, da Silva MG, Rodrigues MAM and da Silva RJ (2005):** Appendiceal taeniasis presenting like acute appendicitis. *Parasitol. Res.*, 97: 171-172.
- 10-Orchard G and Nation B (2012):** Histopathology: From specimen to slide. 1st ed. New York, Oxford Univ. Press Inc.
- 11- Cheesbrough M (1992):** Techniques used to identify parasites. In "Medical Laboratory Manual for Tropical Countries" 2nd edition Educational low priced Books Scheme.
- 12-Yabanoglu H, Aytac HO, Turk E and Karagulle E (2014):** Parasitic infections of the appendix as a cause of appendectomy in adult patients. *Turkiye Parazitol. Derg.*, 38:12-16.
- 13-Yidirim S, Nursal TZ, Tarim A, Kayaselcuk F and Noyan T (2005):** A rare cause of acute appendicitis: parasitic infections. *Scand J. Infect. Dis.*, 37:757-759.
- 14-Helmy A H, Abou Shousha T, Magdi M and Sabri T (2000):** Appendicitis: Appendectomy and the value of endemic parasitic infestation. *Egypt. J. Surg.*, 19:87-91.
- 15-Zakaria OM, Zakaria HM, Daoud MY, Al Wadaani H, Al Buali W, Al-Mohammedy H, Al Mulhim AS, and Zaki W (2013):** Parasitic infestation in pediatric and adolescent appendicitis. *Oman Med. J.*, 28: 92-96.
- 16-Jada S K, Jayakumar K, Sahu P S and Vinorth R (2014):** Faecolith examination for spectrum of parasitic association in appendicitis. *J. Clin. Diagn. Res.*, 8:16-18.
- 17-Hedya MS, Nasr MM, Ezzat H, Hamdy HM, Hassan AM and Hammam O (2012):** Histopathological findings in appendectomy specimens: A retrospective clinicopathological analysis. *J. Egypt. Soc. Parasitol.*, 42:157-164.
- 18-Abdellatif MZ, Abdel-Hafeez EH , Belal US , Mohamed RM, Abdelgelil NH, Abdel-Tawab N and Atiya AM (2015):** Identification of parasitic infections in appendectomy specimens using histopathological and faecolith examinations, *J. Egypt. Parasitol. United*, 101:106.
- 19- Arca MJ, Gates RL, Groner JI, Hammond S and Caniano DA (2004):** Clinical manifestations of appendiceal pinworms in children: an institutional experience and a review of the literature. *Pediatr. Surg. Int.*, 20:372-375.
- 20-Ramezani MA and Dehghani MR (2007):** Relationship between *Enterobius vermicularis* and the incidence of acute appendicitis. *Southeast Asian J. Trop. Med. Pub. Health*, 38:20-23.
- 21-Engin O, Calik S, Calik B, Yildirim M and Coskun G (2010):** Parasitic appendicitis from past to present in Turkey. *Iranian J. Parasitol.*, 5:57-63
- 22- Sah SP and Bhadani PP (2006):** *Enterobius vermicularis* causing symptoms of appendicitis in Nepal. *Trop. Doct.*, 36:160-162.
- 23- Mousa KM, Abdel-Tawab AH, Khalil HH and El-Hussieny NA (2010):** Diarrhea due to parasites particularly *Cryptosporidium parvum* in great Cairo, Egypt. *J. Egypt. Soc. Parasitol.*, 40: 439-450.
- 24- Bayomy AM, Mohamed KA, Ghannam MA, Shahat SA and Al-Saadawy AS (2010):** Opportunistic parasitic infections among immunocompromised Egyptian patients. *J. Egypt. Soc. Parasitol.*, 40:797-808.
- 25- Obala AA, Simiyu CJ, Odhiambo DO, Nanyu V, Chege P, Downing R, Mwaliko E, Mwangi AW, Menya D, Chelagat D, Nyamogoba HD, Ayuo PO, O'Meara WP, Twagirumukiza M, Vandebroek D, Otsyula BB and De Maeseneer JM (2013):** Health and demographic surveillance systems baseline survey of soil-transmitted helminths and intestinal protozoa among children up to five years. *J. Trop. Med.*, 55:734-746.
- 26- Abate A, Kibret B, Bekalu E, Abera S, Teklu T, Yalew A, Endris M, Worku L and Tekeste Z (2013):** Cross-sectional study on the prevalence of intestinal parasites and associated risk factors in Teda Health Centre, North West Ethiopia. *Internat. Schol. Res. Nat. Parasitol.*, 55:757-761.
- 27- Abed NT, Aly NS, Abdel-Gawad ER and Ibrahim SG (2014):** Vitamin D status in children with recurrent acute diarrhea. *Int. J. Curr. Microbiol. App. Sci.*, 3: 858-868.
- 28- Deepesh K, Shrutikirti M and Shivendra M (2013):** A preliminary study of intestinal parasitic infection in a tertiary care hospital of Western UP, India. *Intern. J. Pharma. Sci. Invent.*, 2: 34-39.
- 29- Kheirandish F, Tarahi M, Haghghi A, Nazemalhosseini-Mojarad E and Kheirandish M (2011):** Prevalence of intestinal parasites in bakery workers in khorramabad, lorestan Iran. *Iran J. Parasitol.*, 6: 76-83.
- 30- Ibrahim AA (2011):** Prevalence and predisposing factors regarding intestinal parasitic infections among rural primary school pupils at Minia Governorate, Egypt. *J. Pub. Health in Africa*, 2: 29.
- 31- El-Masry FA, El-Hawary ZM and Salem NA (2007):** Competing anemia among school children using a highly available on preparation. *Egypt. J. Comm. Med.*, 7: 81-94.
- 32- Meeusen EN and Balic A (2000):** Do eosinophil have a role in the killing of helminth parasites? *Parasitol. Today.*, 16: 95-101.
- 33- Demirci M (2001):** Fascioliasis in patient with eosinophilia in Isparta. *Izmir. Parasitology*, 18: 243-251.