

## INTERVENTION PROGRAM FOR NURSING STAFF REGARDING APPROACH TO A PATIENT WITH SPIDER PHOBIA AND/OR BITE

By

MAHFOUZ AHMAD AL-AGROUDI<sup>1</sup>, SALWA ABDALLA MOHAMMAD AHMED<sup>1</sup>  
AND TOSSON A. MORSY<sup>2</sup>

Military Medical Academy<sup>1</sup> and Department of Parasitology, Faculty of Medicine,  
Ain Shams University, Cairo 11566<sup>2</sup>, Egypt

### Abstract

Spider bites are uncommon medical events, since there are limited number of spiders worldwide with fangs strong enough to pierce human skin, and most spiders bite humans only as a final defense when being crushed between skin and another object. Thus, most lesions attributed to spider bites are caused by some other etiology. The spiders that can cause medically significant bites include widow and false widow spiders (worldwide), recluse spiders (mostly North and South America), Australian funnel web spiders (eastern coastal Australia) and Phoneutria spiders (Brazil). Acute spider bites most commonly result in a solitary papule, pustule, or wheal. Systemic symptoms can accompany envenomation of widow; funnel web, and Phoneutria spiders, and less often, those of recluse spiders.

**Key words:** Spiders, Medical importance, Nursing, Control, General review.

### Introduction

Spider bites are rare medical events. Of the thousands of spider species that exist around the world, only a handful causes problems in humans. There are a variety of more common disorders that can mimic a spider bite, some of which represent a far greater threat to the patient if not recognized and treated appropriately (Vetter and Isbister, 2008).

Thus, accurate diagnosis is the initial goal of the clinician evaluating a patient with a lesion that might represent a spider bite. Discerning among the various conditions in the differential diagnosis of a spider bite requires familiarity with these disorders, as well as a rudimentary understanding of the distribution and behavior of medically important spiders.

### Review, Discussion & Recommendation

**Medical importance:** Spiders are arachnids (a group of arthropods), which are symmetrical having four pairs of legs, similar to scorpions, mites, and ticks (Fig. 1). They use sharp fangs at the end of their chelicerae to bite prey (typically insects, other arthropods, or small vertebrates) and inject paralyzing venom.

Most spiders pose no threat to humans. The venom of most spiders has little or no effect on mammalian tissues (Swanson and Vetter, 2005). In addition, only a few species have cheliceral muscles powerful enough to penetrate human skin, and most of these spiders bite humans only in rare and extreme circumstances (e.g., as they are being fatally crushed between skin and some object).

The spiders most likely to inflict medically significant bites in humans include widow and false black widow spiders, recluse spiders, Australian funnel web spiders, and Phoneutria spiders. Each of these spiders is described briefly below, and their appearance and geographical distribution are summarized (Tab. 1).

**Spider phobia (fear):** Acarophobia, entomophobia or delusional parasitosis is a disorder that affected individuals has the mistaken but unshakable belief (delusion) that they are infected by insects, spiders, scorpion, ticks, mites, parasitic worms, bacteria, or other living organisms (Sabry *et al*, 2012). Michalowski *et al*. (2014) investigated long-term memory for unpleasant, neutral and spider pictures in 15 spider-fearful and

15 non-fearful control individuals using behavioral and electrophysiological measures. They concluded that spider-fearful but not control participants responded with larger ERP positivity for correctly recognized old when compared to correctly reject new spider pictures, thus showing the same effects in the neural signature of emotional memory for feared objects that were already discovered for other emotional materials. The increased fear memory for phobic materials observed in the present study in spider-fearful individuals might result in an enhanced fear response and reinforce negative beliefs aggravating anxiety symptomatology and the hindering recovery. Effting *et al.* (2016) suggest that implicit processes might become more pertinent for fear behavior as the ability to control such processes wanes, which may be particularly relevant for anxiety disorders given their association with lowered executive control functioning. As such, training procedures that specifically target implicit processes or control abilities might improve treatment outcomes for anxiety disorders. They suggested that t implicit processes might become more pertinent for fear behavior as the ability to control such processes wanes, which may be particularly relevant for anxiety disorders given their association with lowered executive control functioning. As such, training procedures that specifically target implicit processes or control abilities might improve treatment outcomes for anxiety disorders.

Leibovich *et al.* (2016) explored the role of valence and self-relevance in size estimation of neutral and aversive animals. The participants were highly fearful of spiders and participants with low fear of spiders rated the size and unpleasantness of spiders and other neutral animals (birds and butterflies) and others included additional pictures of wasps (not self-relevant, but unpleasant) and beetles. By the mediation analysis they found that in the high-fear group both relevance and valence influenced perceived size,

whereas in the low-fear group only valence affected perceived size.

Widow spiders: *Latrodectus*, or widow spiders (found worldwide), include the Eastern black widow (show picture 1) and Western black widow in the United States, and the Australian redback spider. Widow bites cause unremarkable local lesions that are sometimes accompanied by a characteristic systemic reaction with prominent, proximally-spreading pain and localized diaphoresis surrounding the site of the bite. Antivenoms are available for several species.

Clinical history: Patients presenting with widow bites typically have a recent (<8 hours) history of an at risk activity such as gardening, chopping wood, or cleaning out a garage. Three quarters of bites are on the extremities, particularly the lower extremities (Maretic and Lebez, 1979).

Lesion and local symptoms: The typical black widow bite is a mild lesion consisting of a blanched circular patch with a surrounding red perimeter and a central punctum (show picture 8). Some bites resemble a wheal and flare reaction. Most bites are either asymptomatic or cause local pain at the site of the bite. The time of onset of more generalized symptoms is typically 40 minutes (20 to 120 minutes range) from the time of the bite, but may be longer on occasion (Clark *et al.*, 1992). Significant envenomation causes acute muscle pain and often localized diaphoresis in the affected limb, and this presentation is highly suggestive of a widow bite. If the bite is on the lower extremities, the muscular pain may extend to the abdomen; upper extremity pain may extend to the chest. The pain may be accompanied by tremor, weakness, myoclonus, and local paresthesias. Diaphoresis may extend to involve the whole extremity, the body, or may be limited to areas distant from the bite. There may also be local lymphadenopathy (Diez Garcia *et al.*, 1996). Black widow bites do not become necrotic.

Systemic symptoms: Vital signs are usually normal with moderate envenomation, alt-

though patients may be anxious and tachypneic. With more extensive envenomation, patients may experience some or all of the following systemic symptoms (Saibil, 2000): The generalized musculoskeletal, abdominal, or back pain, hypertension and tachycardia, nausea and/or vomiting. Generalized or regional diaphoresis headache facial swelling, which can be mistaken for an allergic reaction

Pain is usually the most prominent feature in systemic reactions. Severe abdominal pain with abdominal wall rigidity but normal bowel sounds is characteristic. Abdominal pain from a widow bite has been mistaken for a variety of abdominal emergencies, including acute cholecystitis (Bush, 1999).

Other case reports have described cardiovascular collapse, pulmonary edema, and ileus (leiner-Baumgarten, 1991). Additional reported complications include hematuria, Horner's syndrome, compartment syndrome, rhabdomyolysis, and the toxic epidermal necrolysis (Cohen and Bush, 2005). Death is unusual, even in children, who are generally more affected by envenomations (Woestman *et al*, 1996). The few cases of latrodectism with documented rhabdomyolysis do not show a large rise in serum creatine phosphokinase.

In the patients presenting late with the latrodectism, irrespective of the bite location, principal symptoms may devolve to burning pain in the soles of the feet, pain in the legs, below the knee, and profuse sweating below knees. In infants, latrodectism may present as an inconsolable child, very distressed, refusing food/drink, sometimes with a generalized erythematous appearance. A classic story would be of a newborn brought home and placed in a cot that had been stored in a garage, which develops the above clinical findings. In such cases a squashed widow spider may be found on searching the area in which the infant was lying or sleeping.

Venom properties: Black widow venom contains neurotoxins of the latrotoxin type,

including a vertebrate-specific toxin called alpha-latrotoxin, a large protein toxin (120 kDa) that triggers massive exocytosis from presynaptic nerve terminals and in a variety of neurosecretory cells (Sudhof, 2001). Acetylcholine, norepinephrine, dopamine, glutamate, and enkephalin systems are all susceptible to the toxin (Nicholson and Graudins, 2002). It appears this toxin is present in the venom of all medically important widow spiders and this has clear implications for cross reactivity of anti-*Latrodectus antivenoms*.

Laboratory abnormalities: Abnormal laboratory studies are present in up to half of cases upon presentation and most frequently include elevations in white blood cell counts and serum concentrations of creatine phosphokinase, glucose, and/or liver enzymes (Clark *et al*, 1992). However, laboratory tests are not necessary to make the diagnosis of latrodectism.

False black widow spiders: Steatoda, or false black widow spiders (found worldwide) are less often implicated in human bites, and cause less severe symptoms than those of widows (show picture 2).

Clinical history: The false black widow is found in trash and clutter, and is much more likely to be found inside homes. In an Australian series that included 23 verified Steatoda bites, 78% of bites occurred indoors, often while dressing (Muller, 1993). Bites occurred throughout the year and mostly during waking hours.

Symptoms: Nearly all bites are painful, and pain may increase during the first hour [5,27]. In the Australian series, one-third of victims seeking medical attention had systemic symptoms including nausea, headache, lethargy, and malaise (Isbister and Gray, 2003).

Diagnosis: A presumptive diagnosis of a spider bite is most often based on the history and clinical presentation. Of note, the diagnosis of a spider bite can be considered definitive only if both of the following criteria are fulfilled: A spider was observed inflicting

ing the bite The spider was recovered, collected, and properly identified by an expert arachnologist/ parasitologist If both of the above conditions are not met, then other conditions such as vasculitis, infection, vascular problems, or other relevant disorders must be considered and, where appropriate, excluded. However, latrodectism has a number of distinctive features. In regions where widow spiders are common, it is acceptable for clinicians to make a diagnosis of latrodectism without formal sighting of a confirmed widow spider.

Differential diagnosis: The painful muscle spasms of latrodectism may mimic a variety of other painful conditions. Surgical abdomen - Abdominal muscle spasms and pain may be mistaken for a surgical abdomen, as mentioned previously (La Grange, 1990). Other signs and symptoms may help distinguish latrodectism from other entities. For example, patients with a surgical abdomen (eg, appendicitis) tend to be tired, have constant pain, and are often hypotensive when peritonitis is present. Patients with the latrodectism are more likely to be hypertensive, hyperactive, and have intermittent muscle spasms.

Treatment: The majority of patients who sustain a widow spider bite require only local care of the lesion. Patients with moderate to severe envenomations, characterized by severe local symptoms or the presence of regional or systemic symptoms, may require supportive care and monitoring for complications. Antivenoms are also available for treatment of widow spider bites in selected cases.

Recluse spiders: *Loxosceles*, or recluse spiders are found in predominantly in North and South America (show picture 3). Their bites are notorious for becoming necrotic, although this happens in a minority of cases. Systemic reactions to bites are usually mild, and consist of non-specific systemic signs and symptoms.

Clinical manifestations of bites: *Loxoscelism* is the term for the medical manifesta-

tions of bites by recluse spiders. In this review, the term is used to refer to both local and systemic symptoms resulting from bites, although toxicologists sometimes use the term to refer exclusively to the systemic symptoms.

Venom properties: *Loxosceles* venom contains a large number of enzymes and biologically active substances, of which sphingomyelinase D is the most important. This enzyme is unique in nature to *Loxosceles* and its sister genus, *Sicarius*, but is absent in all other spiders including closely related haplogyne spiders (Binford and Wells, 2003). Sphingomyelinase is believed responsible for skin necrosis and the systemic manifestations of *Loxosceles* envenomation. It activates complement, induces neutrophil chemotaxis, induces apoptosis of keratinocytes and other cells, and initiates the generation of potent collagen and elastin-degrading metalloproteinases (Tambourgi *et al*, 2005).

Clinical history: Recluse spiders (like most spiders) typically bite humans only as a desperate last line of defense as they are being crushed between flesh and some object. This happens most frequently indoors, as a result of rolling over on the spider in bed or putting on clothing or footwear that has been left in closets or on the floor, in which the spider has sought refuge. Recluse spider bites typically occur on the upper arm, thorax, or inner thigh. Bites on the hands or face (ie, uncovered areas) are rare. Recluse bites can be sustained out of doors, although these spiders are rarely found in living vegetation. Patients reporting a painful bite while reaching into living foliage are more likely to have sustained an insect sting or puncture by thorns or other sharp plant matter.

Symptoms following bites: Symptoms may be divided into acute local symptoms, systemic symptoms, and, in a subset of bites, necrosis of the bite site.

Acute local symptoms: The initial bite of a *Loxosceles* spider is usually painless, although they can occasionally be painful or cause a burning sensation. The site can

sometimes be identified by two small cutaneous puncture marks with surrounding erythema. The bite is usually a red plaque or papule, which often develops central pallor. The pain typically increases over the next two to eight hours, and may become severe. In most cases, this lesion is self-limited and resolves without further complications in approximately one week (Anderson, 1991). In some, however, the lesion will develop a dark, depressed center over the ensuing 24 to 48 hours, culminating in a dry eschar that subsequently ulcerates. Some patients develop urticaria or a morbilliform rash in the hours after the bite; this has been suggested by some as evidence of a prior bite, although the phenomenon has not been studied formally.

**Systemic symptoms:** Systemic symptoms are an infrequent complication of recluse bites, and do not correlate to local findings. Small children may be more susceptible to systemic symptoms. The following nonspecific signs and symptoms may appear over several days following a recluse bite: Malaise nausea and vomiting fever myalgias. Rare complications include disseminated intravascular coagulopathy, rhabdomyolysis, myonecrosis, renal failure, coma, and death (Franca *et al*, 2002). Case reports of loxosceles bites during pregnancy have documented no adverse effects on infant outcome. In contrast, these complications are more common with loxoscelism from the South American species *L. laeta* (Futrell, 1991).

**Necrosis:** A minority of lesions become necrotic, usually over the course of several days. The original papule or plaque develops a dusky red or blue color in the center of the lesion, and a dry, depressed center may herald necrosis. There may be anesthesia in the center. An eschar forms and subsequently breaks down to form an ulcer. The lesion may enlarge in a gravitational manner. A fully developed necrotic lesion is usually 1 to 2 cm in diameter, although skin loss can be more extensive and ulcers as large as 40

cm or more have rarely been described. These most typically occur over fatty tissue on the buttocks and thighs. Lesions usually stop extending within 10 days of the bite, and most lesions heal by secondary intent over several weeks, without scarring. Some necrotic lesions take months to heal fully. Permanent scarring or requirement for surgical repair is uncommon (Kemp, 1998).

**Diagnosis:** A presumptive diagnosis of a spider bite is most often based on the history and clinical presentation. An assay for *Loxosceles* venom has been developed but is not commercially available. Of note, the diagnosis of a spider bite can be considered definitive only if both of the following criteria are fulfilled: A spider was observed inflicting the bite (Stoecker *et al*, 2006). If both of the above conditions are not met, then other conditions such as vasculitis, infection, vascular problems, or other relevant disorders must be excluded.

**Differential diagnosis:** Numerous conditions have been mistaken for a necrotic recluse spider bite. The commonest disorders in differential diagnosis are: Solitary ulcerated lesion: Conditions that can cause single ulcerated lesions include infections, trauma, vascular diseases, pyoderma gangrenosum, and vasculitides. Infections: Common infections that can become necrotic include staphylococcus and streptococcal infections, deep fungal infections, and atypical mycobacterial infections. Community-acquired methicillin-resistant *Staphylo-coccus aureus* (CA-MRSA) skin infections can begin with singular or papules or pustules that may evolve to necrotic lesions (Dominguez, 2004). Infections occur both sporadically and as institutional epidemics in nursing homes, prisons, military barracks, and athletic facilities and confused with spider bite (Kawamura *et al*, 2016). Vascular disease: Foot and ankle ulcers can be seen in patients with chronic venous insufficiency, arterial insufficiency, or diabetes mellitus, and a history of the underlying disease should alert clinicians to this possibility. Py-

oderma gangrenosum: it is an idiopathic disorder in which dark, blue-red papules progress to necrotic ulcerating lesions. Patients may report a history of antecedent trauma at the site or have signs of systemic illness. Vasculitides: Vasculitis and necrotizing vasculitis may present with singular lesions. Systemic reactions: The systemic symptoms of recluse spider envenomation (e.g., malaise, nausea and vomiting, fever, and myalgias) are sufficiently nonspecific that an accompanying lesion, preferably with an identifiable spider, is essential for making the diagnosis of a spider bite.

Treatment: Treatment of a recluse spider bite involves local wound care, pain management, and tetanus prophylaxis if indicated. Dapsone may be administered in some cases, both to prevent progression to necrosis, and to reduce pain. An array of other interventions reported in the medical literature, although most are based upon animal studies or isolated human case reports (King and Rees, 1983).

The local wound care: Initial treatment measures following any spider bite include: Clean the bite with mild soap and water Apply cold packs, taking care not to freeze the tissue Maintain the affected body part in an elevated or neutral position (if possible)

General measures following bites Administer pain medication as needed. Some patients will respond to non-steroidal anti-inflammatory medications, while others may require opioids. Administer tetanus prophylaxis if indicated (Barrett *et al*, 1994). Most bites can be managed with minimal intervention and heal without scarring. Resolving bites should be monitored for the development of secondary bacterial infection.

Indications for antibiotics: Antibiotics are prescribed only if there are signs of infection such as increased erythema, fluctuation, and suppuration. If infection is suspected, it should be treated with antibiotics for cellulitis, as outlined in the table (Phillips *et al*, 1995).

Australian funnel web spiders: Australian funnel web spiders are found in limited areas of eastern coastal Australia. Their bites can cause dramatic systemic reactions that mimic organophosphate poisoning and include salivation, diaphoresis, muscle spasms, tachycardia, hypertension, and pulmonary edema. Antivenom is available.

South American Phoneutria: Phoneutria or armed spiders are large spiders found in South America, especially urban areas of Brazil. The bites of these spiders can lead to severe systemic reactions, with occasional fatalities in children. Antivenom is available.

Types of reactions: A spider bite usually presents acutely as a solitary papule, pustule, or wheal. Systemic symptoms can accompany some envenomations, particularly those of widow spiders, funnel web spiders, and less often, recluse spiders. Allergic reactions typically result from contact with spiders (rather than bites).

Local reactions: Photographs of verified spider bites are rare in the medical literature, although dramatic images of necrotic lesions attributed to spider bites are commonplace in both medical journals and on the Internet. In reality, the majority of spider bites result in unremarkable wheals, papules, or pustules (show picture 4). Local redness with a tender nodule at the site of the bite appears within minutes. The lesions are similar to those induced by a bee sting. In some cases, the markings of the fangs (one or two small puncture marks) are visible. Some bites also itch or burn. Spider bites may or may not be painful, and some go unnoticed. Pain can develop gradually over the ensuing hours after a bite, and can range from a slight prickly sensation to severe pain. The variability among bites and patients limits the clinical utility of this information in implicating a specific type of spider. Most local reactions to spider bites resolve spontaneously in approximately 7 to 10 days and occasionally become secondarily infected with skin-derived bacteria.

Necrotizing local reactions: Recluse (*Loxosceles*) spiders inflict bites that may become necrotic, although this is an uncommon complication. Other types of spiders have been implicated in causing necrotic bites, but this is based largely upon circumstantial evidence.

Systemic reactions: Systemic symptoms are reported in a minority of patients, and occur when venom enters the circulation in sufficient amounts. The bites of certain spiders are known for distinct and potentially severe systemic reactions, including bites of the widow, Australian funnel web, and Phoneutria spiders.

Allergic reactions: Allergic reactions to spiders are rare and have been reported mostly in response to contact with spiders (Hasan *et al*, 2005). In the United States, tarantulas are increasingly popular pets (show picture 5). These nonaggressive spiders rarely bite. When threatened, they dislodge small (about 1 mm long) barbed hairs at the posterior of their abdomens and launch them at their attacker. These hairs, as well as airborne material from crushed tarantulas, may cause irritation or urticaria if they come in contact with skin, eyes, or mucous membranes (Castro *et al*, 1995). In addition, airborne material from tarantulas can cause foreign body reactions in the eye (Hered *et al*, 1988). Contact with tarantulas has also induced rare anaphylactic reactions in sensitized individuals (Wong *et al*, 1987).

Diagnosis: A presumptive diagnosis of a spider bite is most often based on the history and clinical presentation. However, the diagnosis of a spider bite can be considered definitive only if both of the criteria below are fulfilled: A spider was observed inflicting the bite. The spider was recovered, collected, and properly identified by an expert entomologist. If these criteria are not met, then other conditions such as vasculitis, infection, vascular problems, or other relevant disorders must be ruled out.

Unfortunately, the criteria above are rarely met, even in published medical reports. This

has resulted in a body of literature and considerable media attention falsely attributing various lesions and symptoms to spider bites. The extent of this problem was illustrated in a review of 600 cases of suspected spider bites, which found that 80 percent of presumed bites could be more reasonably attributed to other causes (Vetter and Bush, 2004). These other causes included bites of different arthropods such as ants, fleas, bedbugs, ticks, mites, mosquitoes, and biting flies, as well as erysipelas, cellulitis, ecthyma, vasculitis, pyoderma, ophthalmic zoster, urticaria, angioedema, and burns.

Medical history: Most patients' reports of spider bites are unreliable. The bite history is often speculative and retrospective and a spider was never visualized, either inflicting the bite or even present. Even when a bite is witnessed by the patient, the "spider" is commonly found to be some other arthropod. The diagnosis of a spider bite is thus highly suspect unless the patient actually observed a spider inflicting the bite and can retrieve it for identification. In the absence of this history and supporting evidence, another explanation should be sought (Spiller and Schultz, 2002).

The setting in which the patient sustained the alleged bite should be carefully reviewed to see if it is consistent with the known habitat and behavior of the venomous spiders that live in the area. People may worry about the possibility that a venomous spider was transported into a non-indigenous area on fruit or other produce. However, it is rare for spiders to survive intact through the many steps involved in produce transportation, and then end up in a situation in which they would bite. The risk may be more significant for people working in food transport and handling, but it are minimal in the general community. Clinical clues that essentially exclude the diagnosis of spider bite include the following: Multiple lesions or more than one lesion on widely-separated parts of the body suggest another etiology. Spider bites are typically single lesions. Bites are gener-

ally not simultaneously sustained by multiple residents of the same household.

Spider bites capture the imagination. Reports exist of patients both feigning spider bites as part of drug seeking behavior and attempting suicide with genuine spider bites (Fisher, 1976).

**Influence of geographic location:** Each of the venomous spiders lives in specific parts of the world (Tab. 1). Clinicians should know which spiders are indigenous to their area. Widows and false black widows are found worldwide. There are no commercially available laboratory tests for identifying the presence of spider venom. Thus, the diagnosis is made clinically (Dominguez, 2004).

**Infections:** Papules and pustules should be carefully unroofed and cultured to identify infectious causes. Common infections that could be mistaken for spider bites include *Staphylococcus* and *Streptococcus* infections, the skin lesion of early Lyme disease, and atypical presentations of herpes zoster or herpes simplex. Community-acquired methicillin-resistance *Staphylococcus aureus* skin infections can begin with singular or papules or pustules that may evolve to necrotic lesions. CA-MRSA is far more prevalent than spider bites. Infections occur both sporadically and as institutional epidemics in nursing homes, prisons, military barracks, and athletic facilities. Risk factors and epidemiology of CA-MRSA are discussed separately. Erythema migrans, the target-like skin lesion of early Lyme disease, may be mistaken for a spider bite. Southern tick-associated rash illness (STARI) is a similar infection with similar skin findings, which occurs in the southern United States (below Maryland). Herpes zoster and herpes simplex infections (especially herpetic whitlow) may occasionally present with singular lesions. Acute onset is associated with vesicles, vesicopustules, severe edema, erythema, or pain. Tzanck staining of vesicles will demonstrate multinucleated giant cells and viral culture will grow HSV.

**Other bites and stings:** A wide variety of insects sting or bite humans, including triatomid bugs, ants, fleas, bedbugs, blister beetles, ticks, mites, mosquitoes, and biting flies (Al-Asmari and Al-Saif, 2004; Morsy, 2012; 2014; Saleh *et al.*, 2013; El-Bahnasawy *et al.*, 2014; Abdel-Rahman *et al.*, 2015).

**Nursing role:** Nurses address many infection control challenges in hospitals as well as community environment. They are responsible to provide the client with a safe environment. Guidelines to address these challenges are important for delivery of safe and high quality care. Care is increasingly being delivered in a wide range of settings. However, the nurses are often inappropriate for careers in the community settings. Nurses in preventive health care are tasked with improving the health of patients. Nurses are required to help patients maintain their health rather than treating diseases and illness as they arise. Preventive care encompasses a wide range of techniques to identify, educate, prevent and treat diseases. As to spider bite, Hifumi *et al.* (2014) reported that approximately one third of cases developed systemic symptoms, and anti-venom was administered effectively and safely in severe cases

McGhee *et al.* (2015) stated that envenomation by spiders or scorpions are a public health problem in many parts of the world and is not isolated to the tropics and subtropics. Spiders and scorpions can be unintentionally transported globally, and keeping them as pets is becoming more popular, so envenomation can occur anywhere. Emergency nurses should be prepared to assess and treat patients who present with a bite or sting.

### **Recommendation**

The bites of recluse spiders can become necrotic, although most bites do not necrose. Allergic reactions to contact with spiders (rather than bites) occur most often in response to tarantulas. Clinicians should know which of the biting spiders (if any) are found in the areas in which they practice, and have



a basic understanding of the entomology of those species. The working diagnosis of a spider bite is based upon suggestive history and clinical presentation. However, definitive identification of a spider bite requires all of the following: a spider was observed inflicting the bite, the spider was recovered, collected, and properly identified by an expert entomologist, and other disorders have been ruled out. In the majority of cases, another etiology is responsible for the lesion, other than a spider bite. The differential diagnosis includes infections, bites and stings of other arthropods, and several other more common dermatosis. Culture should be performed in most cases.

### References

- Abdel-Rahman, TZ, Mohamad, HM, Morsy, ATA, Morsy, TA, 2015:** Allergic reactions caused by venom of hymenopterous stinging insects and the role of health care workers. *J. Egypt. Soc. Parasitol.* 45, 1:403-12
- Al-Asmari, AK, Al-Saif, AA, 2004:** Scorpion sting syndrome in a general hospital in Saudi Arabia. *Saudi Med. J.* 25:64-72.
- Anderson, PC, 1991:** Loxoscelism threatening pregnancy: five cases. *Am. J. Obstet. Gynecol.* 165:1454-8.
- Barrett, SM, Romine-Jenkins, M, Fisher, DE, 1994:** Dapsone or electric shock therapy of brown recluse spider envenomation?. *Ann. Emerg. Med.* 24:21-8.
- Binford, GJ, Wells, MA, 2003:** The phylogenetic distribution of sphingomyelinase D activity in venoms of Haploglyne spiders. *Comp. Biochem. Physiol. B Biochem. Mol. Biol.* 135:25-32.
- Bush, SP, 1999:** Black widow spider envenomation mimicking cholecystitis. *Am. J. Emerg. Med.* 17:315-9.
- Castro, FF, Antila, MA, Croce, J, 1995:** Occupational allergy caused by urticating hair of Brazilian spider. *J. Allergy Clin. Immunol.* 95:1282-90.
- Clark, RF, Wethern-Kestner, S, Vance, MV, Gerkin, R, 1992:** Clinical presentation and treatment of black widow spider envenomation: a review of 163 cases. *Ann. Emerg. Med.* 21: 782-8.
- Cohen, J, Bush, S, 2005:** Case report: compartment syndrome after a suspected black widow spider bite. *Ann. Emerg. Med.* 45:414-20.
- Diez Garcia, F, Laynez Bretones, F, Galvez Contreras, MC, et al, 1996:** Black widow spider (*Latrodectus tredecimguttatus*) bite: Presentation of 12 cases. *Med. Clin. (Barc)* 106:344-9.
- Dominguez, TJ, 2004:** It's not a spider bite, it's community-acquired methicillin-resistant *Staphylococcus aureus*. *J. Am. Board Fam. Pract.* 17: 220-9.
- Efftig, M, Salemink, E, Verschuere, B, Beckers, T, 2016:** Implicit and explicit measures of spider fear and avoidance behavior: Examination of the moderating role of working memory capacity. *J. Behav. Ther. Exp. Psychiatry.* 50: 269-76.
- El-Bahnasawy, MM, Abdel Fadil, EE, Morsy, TA, 2014:** Bedbug: is it a missed vector of medical importance or just an annoying and irritating insect? *Egyptian Military Medical Journal (EM-MJ)* 69, 1:74-81.
- Fisher, DP, 1976:** Letter: Attempted suicide by black widow spider bite. *JAMA* 235:2718.
- Franca, FO, Barbaro, KC, Abdulkader, RC, 2002:** Rhabdomyolysis in presumed viscerocutaneous loxoscelism: report of two cases. *Trans. R. Soc. Trop. Med. Hyg.* 96:287-92.
- Futrell, JM, 1991:** Loxoscelism. *Am. J. Med. Sci.* 304:261-6.
- Hasan, T, Mäkinen-Kiljunen, S, Brummer-Korvenkontio, H, et al, 2005:** Occupational IgE-mediated allergy to a common house spider (*Tegenaria domestica*). *Allergy* 60:1455-64.
- Hered, RW, Spaulding, AG, Sanitato, JJ, Wander, AH, 1988:** Ophthalmia nodosa caused by tarantula hairs. *Ophthalmology* 95:166-9.
- Hifumi, T, Fujimi, S, Yamagishi, T, Arai, S, Sawabe, K, et al, 2014:** Clinical characteristics of redback spider bites. *J. Intensive Care* 2, 1:62-9.
- Isbister, GK, Gray, MR, 2003:** Effects of envenoming by comb-footed spiders of the genera *Steatoda* and *Achaearanea* (family Theridiidae: Araneae) in Australia. *J. Toxicol. Clin. Toxicol.* 41:809-96
- Kawamura, H, Tokuda, K, Imuta, N, Kubota, T, Koriyama, T, et al, 2016:** Epidemiological Analysis of Nosocomial MRSA Outbreaks Using Phage Open-Reading Frame Typing in a Tertiary-care Hospital. *Jpn. J. Infect. Dis.* Jan 8. [Epub ahead of print]
- Kemp, ED, 1998:** Bites and stings of the arthro-

pod kind. Postgrad. Med. 103:88-96.

**King, LE Jr, Rees, RS, 1983:** Dapsone treatment of a brown recluse bite. JAMA 250:648-52

**La Grange, MA, 1990:** Pulmonary oedema from a widow spider bite. S. Afr. Med. J. 77:110-8.

**Leibovich, T, Cohen, N, Henik, A, 2016:** Itsy bitsy spider? Valence and self-relevance predict size estimation. Biol. Psychol. 2016 Jan 21. pii: S0301-0511(16)30008-4.

**leiner-Baumgarten, A, 1991:**Black widow spider bite in the Negev. Harefuah. 120:257-62.

**McGhee, S, Weiner, A, Finnegan, A, Visovsky, C, Clochesy, JM, et al, 2015:** Assessing and managing spider and scorpion envenomation. Emerg. Nurse 23, 7:32-7.

**Michalowski, JM, Weymar, M, Hamm, AO, 2014:** Remembering the object you fear: brain potentials during recognition of spiders in spider-fearful individuals. PLoS One. Oct 8;9(10): e109537. doi: 10.1371/journal.pone. 0109537.

**Mikhail, MW, Soliman, MI, Morsy, TA, 2011:** The current status of fleas according to environmental changes in some governorates in Egypt. J. Egypt. Soc. Parasitol. 41, 1:199-213.

**Morsy, TA, 2012:** Insect bites and what is eating you? J. Egypt. Soc. Parasitol.42, 2:291-308.

**Morsy, TA, 2014:** Zoonotic myiasis in Egypt: with reference to nosocomial or hospital-acquired myiasis. J. Egypt. Soc. Parasitol. 44, 3:637-50.

**Muller, GJ, 1993:** Black and brown widow spider bites in South Africa: a series of 45 cases. S. Afr. Med. J. 83:399-104.

**Nicholson, GM, Graudins, A, 2002:** Spiders of medical importance in the Asia-Pacific: atracotoxin, latrotoxin and related spider neurotoxins. Clin. Exp. Pharmacol. Physiol. 29:785-9.

**Phillips, S, Kohn, M, Baker, D, et al, 1995:** Therapy of brown spider envenomation: a controlled trial of hyperbaric oxygen, dapsone, and cyproheptadine. Ann. Emerg. Med. 25:363-9.

**Russell, FE, Gertsch, WJ, 1983:** For those who treat spider or suspected spider bites. Toxicol 21: 337.

**Sabry, AH, Fouad, MA, Morsy, ATA, 2012:** Entomophobia, acarophobia, parasitic dermatophobia or delusional parasitosis. J. Egypt. Soc. Parasitol. 42, 2:417-30.

**Saibil, HR, 2000:** The black widow's versatile venom. Nat. Struct. Biol. 7:3-8.

**Saleh, AMA, Ali, HA, Ahmed, SAM, Mohammad, NM, Morsy, TA, 2013:** House dust mites: A risk factor to be considered for occupational safety or source of work-related allergens. J. Egypt. Soc. Parasitol. 43, 3:669-78.

**Spiller, HA, Schultz, OE, 2002:** Envenomations as a novel drug-seeking method. Vet. Hum. Toxicol. 44:297-304.

**Stoecker, WV, Green, JA, Gomez, HF, 2006:** Diagnosis of loxoscelism in a child confirmed with an enzyme-linked immunosorbent assay and noninvasive tissue sampling. J. Am. Acad. Dermatol. 55:888-94.

**Sudhof, TC, 2001:** alpha-Latrotoxin and its receptors: neurexins and CIRL/latrophilins. Ann. Rev. Neurosci. 24:933-42.

**Swanson, DL, Vetter, RS, 2005:** Bites of brown recluse spiders and suspected necrotic arachnidism. N. Engl. J. Med. 352:700-8.

**Tambourgi, DV, Paixao-Cavalcante, D, Goncalves de, Andrade RM, et al, 2005:** Loxosceles sphingomyelinase induces complement-dependent dermonecrosis, neutrophil infiltration, and endogenous gelatin-se expression. J/ Invest. Dermatol.124:725-32.

**Vetter, RS, Bush, SP, 2004:** Additional considerations in presumptive brown recluse spider bites and dapsone therapy. Am. J. Emerg. Med. 22:494-9.

**Vetter, RS, Isbister, GK, 2008:** Medical aspects of spider bites. Ann. Rev. Entomol. 53: 409-16.

**Woestman, R, Perkin, R, Van Stralen, D, 1996:** The black widow: is she deadly to children?. Pediatr. Emerg. Care 12:360-9.

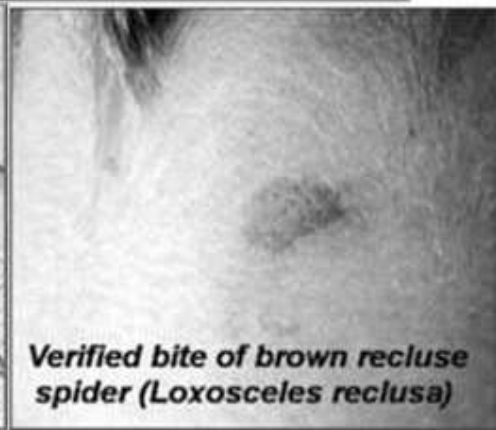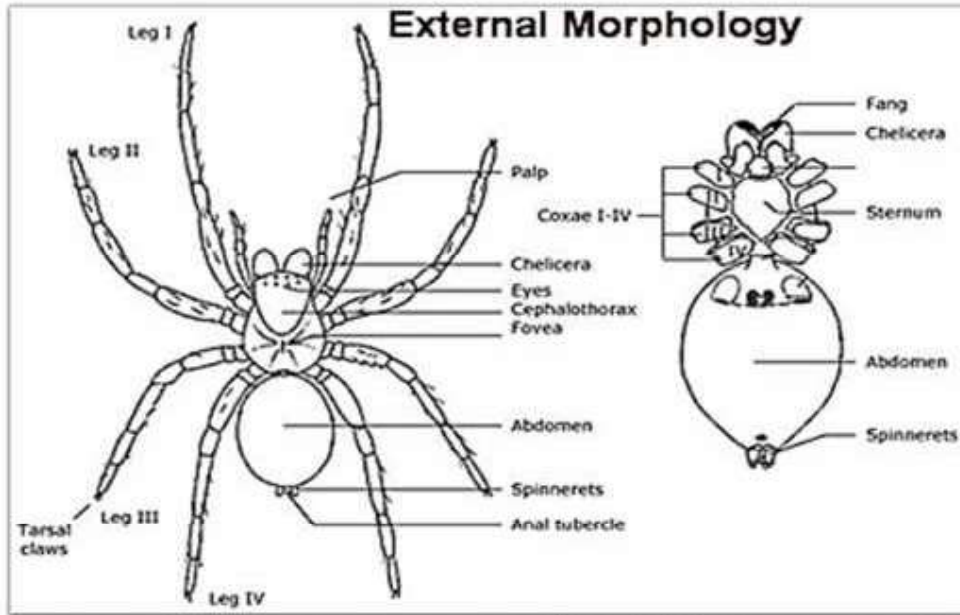
**Wong, RC, Hughes, SE, Voorhees, JJ, 1987:** Spider bites. Arch Dermatol.123:98-102

**Table 1: Spider antivenom sources**

Country	Spiders Anti-venom	Species
Australia	Funnel web spider antivenom	Sydney funnel-web spider
Brazil	Soro antiaracnidico	Brazilian wandering spider and Recluse spider
Chile	Suero antiloxoscelico	Chilean recluse
Mexico	Aracmyn	All <i>Loxosceles</i> and <i>Latrodectus</i> species
Australia	Redback spider antivenom	Redback spider
United States	Black widow antivenom	Black widow spider
South Africa	SAIMR Spider antivenom	Button spider
Argentina	Anti Latrodectus antivenom	Black Widow spider

Table 2: Medically relevant spiders by geographic location

Geographical location	Species	Appearance	Typical habitat
<b>Widows</b>			
Southeastern United States (Maryland, Southern Ohio and lower states)	Eastern black widow <i>L. mactans</i>	Shiny black spider with some form of red on body	Clutter surrounding homes (eg, gardens, sheds, garages)
Western half of the United States from Canada to Mexico	Western black widow <i>L. hesperus</i>		
New Zealand (coastal areas) Australia (coastal areas) Japan (Osaka prefecture)	Australian red back <i>L. hasselti</i>	Shiny black body with dorsal red stripe	Rarely indoors
South America	<i>L. curacuiensis</i>		
Mediterranean	Black hag, black wolf <i>L. tredecimguttatus</i>	Smattering of red dots on dorsal abdomen	
Worldwide and in Southern United States (from Florida to Texas, California)	Brown widow (can bite humans, but mild)	White stripes on a tan abdomen, orange hour-glass	
<b>False Black Widows</b>			
United States: Pacific coast and Colorado Canada: British Columbia Australia	<i>S. grossa</i>	Similar shape to widows Chocolate brown color with tan stripes or markings on abdomen do not have red markings	Clutter surrounding homes Also indoors (in cupboards and undisturbed places)
Europe	<i>S. paykulliana</i> <i>S. grossa</i>		
<b>Recluses</b>			
United States: Mid-west and Southern states extending westward (see map in text)	Brown recluse <i>L. reclusa</i>	Non-descript brown spiders Recluses have 3 pairs of eyes (6 total), monochromatic abdomen and legs, and very fine hairs on legs	Mostly inside homes: attics, basements, cupboards Outdoors: in rock piles and under tree bark NOT in live vegetation
Worldwide infestations of buildings	Mediterranean recluse <i>L. rufescens</i>		
South America (Brazil, Chile, others)	<i>L. laeta</i>		
Isolated reports in South Africa, Australia	<i>L. intermedia</i> <i>L. gaucho</i>		
<b>Phoneutria</b>			
South America	<i>P. nigriventer</i> <i>P. keyserlingi</i> <i>P. fera</i>	Large, extensively-haired spider (up to 95 mm legs pan)	Forage at night and may enter homes to take refuge under household items during day. Found in urban environments in piles of clutter, vegetation, or rubbish.
<b>Australian Funnel Web</b>			
Australia - Southeastern coastal regions (including Sydney and Brisbane)	<i>Atrax robustus</i> 5 species of Hadronyce	Large (25 mm body length), shiny black coloration on body	Moist areas such as basements



**4 months after a brown recluse spider bite with scar remaining**

