

Two-Dimensional and Three-Dimensional Ultrasonography In assessment of Fetal Malformations: Routine versus Selective Use

By

Nahed H.Mohamed and Samia A. Sioudi

Obstetrics and Gynecology Department, Faculty of
Medicinal- Azhar University

Abstract

Objective: This study was conducted trying to answer the question whether three-dimensional ultrasound imaging should be used routinely for prenatal screening of congenital malformations or only used selectively for specific high risk women for congenital malformations.

Subjects & Methods: This study included 1000 pregnant women between 14 and 32 weeks gestation, Routine ultrasound examination was done during antenatal care of 500 pregnant women with no history of risk factors of congenital malformation, their ages were < 35 y (group 1). Selective ultrasound examination was indicated for screening of 500 pregnant women with history of one or more risk factors for getting malformed babies (group 2). Serial ultrasound examinations were done for assessment of fetal organs, first using transabdominal traditional 2-D ultrasound imaging, then 3-D ultrasound examinations using the same machine.

Results: On routine antenatal examinations of group (1) there was no significant difference in detection of congenital malformations between 2-D and 3-D ultrasound examinations (0.2 % and 0.6 % respectively, $P > 0.05$). On the other hand, there was no significant difference between selective 2-D and 3-D ultrasound examinations of high-risk group (11) (0.8 % and 1.4 % respectively, $P > 0.05$). There was no significant difference between routine and selective ultrasound use for detection of congenital malformations ($P > 0.05$). Three-dimensional ultrasound provided the same informations as 2-D ultrasound imaging in 33.33% (1/3 diagnosed anomalies) of group (1) and 57.14% (4/7 anomalies) of group (11). Whereas it was more accurate in diagnosis of fetal anomalies than 2-D imaging in 66.66% (2/3 anomalies) of group (1) and 42.85%(3/7 anomalies) of group (2.).These results were not statistically significant ($P > 0.05$).

Conclusion: Many fetal malformations could be diagnosed by traditional 2-D ultrasonography, yet in some cases limitations do exist. Therefore, a high degree of expertise and training is needed. Traditional 2-D ultrasonography was used routinely early and late in pregnancy for other obstetric indications. We do not support the routine use of 3-D ultrasonography during antenatal assessment of the pregnant women . The adjunctive use of 3-D ultrasonographic imaging system with the 2-D imaging in selective cases can greatly increase diagnostic accuracy of congenital malformation. On the other hand, It is equally important to weigh the human costs against the benefit.

Introduction

Screening for fetal abnormalities has become one of the most profile health care issues of modern obstetrics.

Ultrasound is the chief method for detecting fetal malformations. In this context, Merz et al.(1995) reported that

Two-Dimensional and Three-Dimensional Ultrasonography

a wide range of major malformations have been detected with advances in ultrasound imaging. The appearance of an increasing number of minor malformations has been described including subtle markers of chromosome abnormalities. Ploechinger et al, (1996) reported that 3-D ultrasound technique will represent an important contribution to the research of the developing embryo in-vivo.

There is a clear difference between selective and routine use of ultrasound. The time taken, the detail inspected, and perhaps the seniority of the ultrasonographer will vary with the reason for the examination. Routine examinations must be accomplished quickly for practical reasons and, therefore, some fetal malformations are less likely to be detected than when there are specific reasons to anticipate their presence. The selective examination should be tailored to answer a specific question posed by the person who request the examination (Nelson and Grant 1998).

Whether three-dimensional ultrasound imaging should be used routinely for prenatal diagnosis of congenital malformation or only used selectively for specific indications of high-risk women, has not yet been firmly established. In this study we are trying to answer this question.

Patients and methods

The participants in this study were pregnant women between 14 and 32 weeks gestation attending the antenatal clinics of Al Zahraa and Bab Al Sharia University Hospitals, for antenatal care, in the period from January 2000 to November 2000. History was taken with special attention to maternal age, history of high-risk factors for getting a malformed baby, exposure to teratogenic agents or administration of known teratogenic drugs especially

during the first trimester and history of medical disorders. Accordingly, the cases were classified into two groups:

Group 1: Healthy pregnant women with no apparent risk for getting a malformed baby, their age < 35 y (n =500).

Group 11: pregnant women with high-risk features for getting a malformed baby (n=500). These included women with history of one or more of the following:

- 1- Maternal age ≥ 35 years (n=354), first degree relative parents,
- 2- Previous offspring with congenital malformation or abnormal biochemical screening in maternal serum (n = 15),
- 3- Those exposed to teratogenic agents during current pregnancy: teratogenic drugs or irradiation (n =115), and
- 4—Those suffering medical disorders that may affect fetal development: diabetes mellitus, SLE or viral infections, TORCH, Rh isoimmunization .etc (n=216).

Each woman has singleton pregnancy. For each woman routine antenatal examinations, investigations and ultrasound screening for detection of congenital anomalies were performed

Routine ultrasound examination was done for group (1) during antenatal care.

Selective ultrasound examination was indicated for screening of congenital malformation of the high-risk women of group (2).

Ultrasound Screening for Detection of Congenital malformations.

Each case was underwent serial transabdominal ultrasound examinations of fetal anatomy in detail for detection of malformations of the central nervous, cardio -vascular, gastrointestinal, genitourinary and skeletomuscular systems. Ultrasound

examinations included:

i. Transabdominal two-dimensional ultrasound examination was done first, then

ii. Three-dimensional U/S examination. Three-dimensional U/S examination was done at Bab Al Sharia University Hospital using a specially developed abdominal 3-D transducer, and this imaging system proved capable of providing conventional 2-D sonography images while also possessing the capacity to generate within seconds high quality fine 3-D images on the screen with no need for an external workstation. The 3-D investigation was performed in a similar manner to the conventional two-dimensional ultrasound examination: The Ultrasound equipment used was a Combison 530D (Kretz- technik ,Austria) with transabdominal Voluson sector transducer (3.5/5 MHZ) (Kretz Technik / Austria). This system allowed selection of orthogonal planes at any orientation and position. This system enabled us for the first time to provide a clear three-dimensional surface rendering or a translucency view of fetal structures within a few seconds. The abdominal voluson sector transducer is a 90° mechanical annular array transducer within a relatively large coupling area. It is fast scan sector that is swept automatically in a direction perpendicular to the fast scan plane.

After the field of interest is targeted with a volume box in the normal two-dimensional scan, a volume scan can be activated, causing the transducer inside the transducer housing automatically to sweep 40° within L/S in the normal velocity mode. By this volume scan, the data set from a pyramid shaped tissue volume is acquired. The complete data set is stored in the combison random access memory (RAM). In the stored volume, a set of precisely equally

spaced sector scans can be reviewed simultaneously in the three dimensions, producing tomographic images.

Depending on the volume size and data acquisition time different numbers of scans are available, longitudinal sections, transverse section and frontal or coronal section, surface reconstruction. The volume can be rotated in a dimension such that the fetus or the organ of interest is directly facing the examiner. Disturbing factors such as the placenta, the arm or leg of the fetus or the umbilical cord can be eliminated by so-called Cortesian storing, where only the most interesting part of the volume is stored. After the selection of such a volume of interest, unwanted small echo signals can be suppressed with the lower threshold. The view angle and the number of three-dimensional reconstruction are then defined. After reconstruction of several views from various angles, the object can be rotated on the screen to provide a better representation of spatial geometry.

Risk factors were screened for their association with the development of congenital malformations. Data were analyzed using student's t test, the X^2 test, and crosstab / chi-square tests. Odds ratio for the risk factors were calculated and P value <0.05 was considered significant.

Results

The results of this study were recorded in 4 tables and 6 figures. Table (1) demonstrated that, ultrasound screening of congenital malformations in this study revealed detection of 10 congenitally malformed fetuses (10/1000). All of these malformations were diagnosed by 3-D ultrasound examination [3 (3/500) on routine ultrasound examination in group (1),

Two-Dimensional and Three-Dimensional Ultrasonography In

and 7 (7/500) on selective scanning in group (11)]. Only 4 of these malformations could be visualized by the use of traditional 2-D ultrasound examinations [one (1/500) in group (1) and three (3/500) in group 11].

Gross fetal anomalies diagnosed by 2-D ultrasound examination, like Hydrocephalus and fetal hydrops, could be visualized between 14-20 weeks gestation, anencephally was certainly diagnosed after 20 weeks gestation. A diagnosis of a case with small spinabifida was missed on routine 2-D ultrasound examination of the low risk women. While on selective 2-D ultrasound examination of group (11), diagnosis of spinabifida after 26 weeks gestation was suspected and confirmed by 3-D imaging.

Selective ultrasound examination revealed that only 4/216 (1.85%) of the women suffering medical disorders diagnosed to have congenitally malformed babies (fetal hydrrors, anencephally, spinabifida and cleft lip). There was no significant difference in the incidence of developing fetal anomalies between

women suffering medical diseases and healthy women ($P > 0.05$) (Table 3)

According to Odd's ratio, the risk of developing fetal anomalies are probable 2 times at women aged < 35 years in comparison to ≥ 35 years (which is against the usual), and at women suffering medical diseases in comparison to healthy women and probable 3 times at relative parents more than non relatives. Also the risk of developing fetal anomalies are probable 25 times in women with previous malformed offspring in comparison to low risk women according to Odd's ratio (table 3).

We found that 3D ultrasound provided the same informations as 2D ultrasound in 33.33% (1/3 of Congenital malformation detected in group 1 and 57.14% (4/7) in group 11. whereas it was more accurate in diagnoses than 2D ultrasound in 66.66% (2/3) in group 1 and 42.85%(3/7) in group 11. The sensitivity of 3D ultrasonography on routine or selective screening of fetal malformations is 100% (table 4).

Table (1) Congenital malformations detected by 2-D and 3-D ultrasonographic examinations in the studied groups

Group	Congenital malformations	2-D ultrasonography	3-D ultrasonography
Group 1	Hydrocephalus Talipes equinovarus Spinabifida	Detected Not detected Not detected	Detected Detected Detected
Total P value	(3/500) 0.6%	(1/500) 0.2%	(3/500) 0.6%
$P > 0.05$ (NS)			
Group 11	Fetal hydrops Anencephally Spinabifida Hydrocephalus Cleft lip Clew hand Phocomalia	Detected Detected Detected Detected Not detected Not detected Not detected	Detected Detected Detected Detected Detected Detected Detected
Total P value	(7/500) 1.4%	(4/500) 0.8%	(7/500) 1.4%
$P > 0.05$ (NS)			
P value (between group 1 & 11)	$P > 0.05$ (NS)		

(2) gestational age at which fetal anomalies were detected

Gestational age	Group 1		Group 11		P value
	2-D U/S	3-D U/S	2-D U/S	3-D U/S	
14-20 week	1	1	1	2	> 0.05 (NS)
21-26 week		1	2	3	
> 27 week		1	1	2	
total	1/500	3/500	4/500	7/500	

Table (3) fetal anomalies detected in group (11) in relation to risk factors

Risk factors	Congenitally malformed fetuses			Non affected fetuses		P value
	N	%	Odds ratio	N	%	
Maternal age(y)						
age < 35 Y(n=146)	3	0.6%	0.02	143	28.6%	> 0.05 (NS)
age ≥35 Y(n= 354)	4	0.8%	0.01	350	70.0 %	
Total 500	7	1.4%		493	98.6 %	
*Medical disorders:						
-present (n=216)	4	0.8%	0.02	212	42.4 %	> 0.05 (NS)
-no disorders(n=284)	3	0.6 %	0.01	281	56.2 %	
Total 500	7	1.4 %		493	98.6 %	
**Exposure to teratogenic agents:						
-Exposed (n=115)	2	0.4 %	0.02	113	22.6 %	> 0.05 (NS)
-Non Exposed (385)	5	1.0 %	0.01	380	67.0 %	
Total 500	7	1.4 %		493	98.6 %	
***-History of previous affected offspring (N=15)	3	0.6 %	0.20	12	2.4 %	< 0.001 (HS)
-no affected offspring (N=495)	4	0.8 %	0.008	481	96.2 %	
Total 500	7	1.4 %		493	98.6 %	
****Positive consanguinity (N=100)	3	0.6 %	0.03	97	19.4 %	> 0.05 (NS)
No consanguinity (N=400)	4	0.8 %	0.01	396	79.2 %	
Total 500	7	1.4 %		493	98.6 %	

Sometimes the same participant shared more than one of these risk factors

*Medical disorders: these malformations were detected in one case with rhesus isoimmunisation, two diabetic women and one case suffering SLE , ** One case exposed to x- ray irradiation and one treated with cortisone, *** History of previous offspring with hydrocephalus, anencephaly and meningocele, and **** three relative parents: two of them with no affected children and one with two fetuses with anencephaly and meningocele.

Two-Dimensional and Three-Dimensional Ultrasonography In

Table (4) Sensitivity of 2D and 3D ultrasonography in routine and selective screening of congenital malformation

	Congenital malformation detected in Group 1(n=3)		Congenital malformation detected in Group 11(n=7)	
	N	%	N	%
2D ultrasound examination		3		
3D ultrasound examination	3.33		57.14	
	3	100%	7	100%

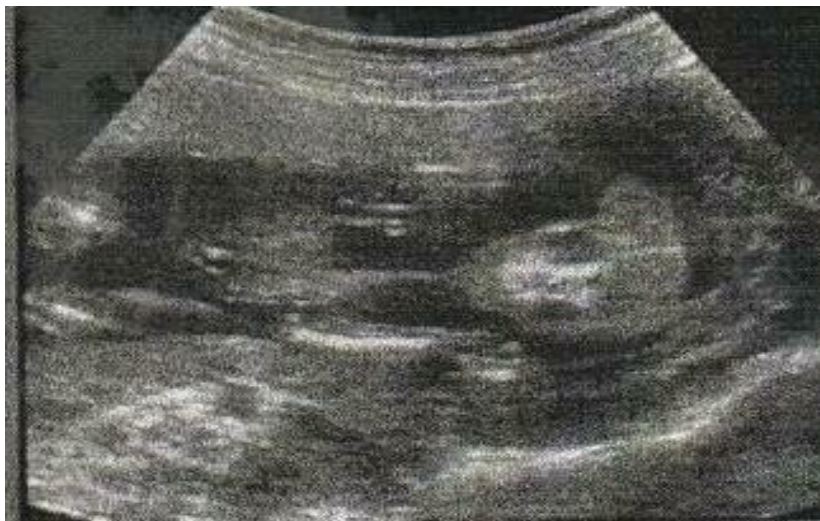

Figure 1. Two- dimensional ultrasound image of second trimester fetus with anencephally (group 11)

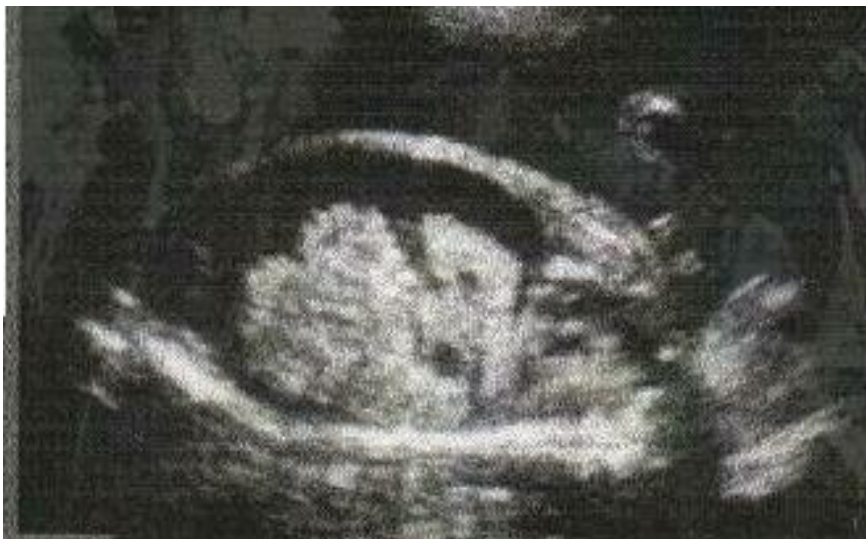

Figure 2. Two-dimensional ultrasound image of fetal hydrops at 19-weeks gestation (ascitis and hydrothorax) group 11

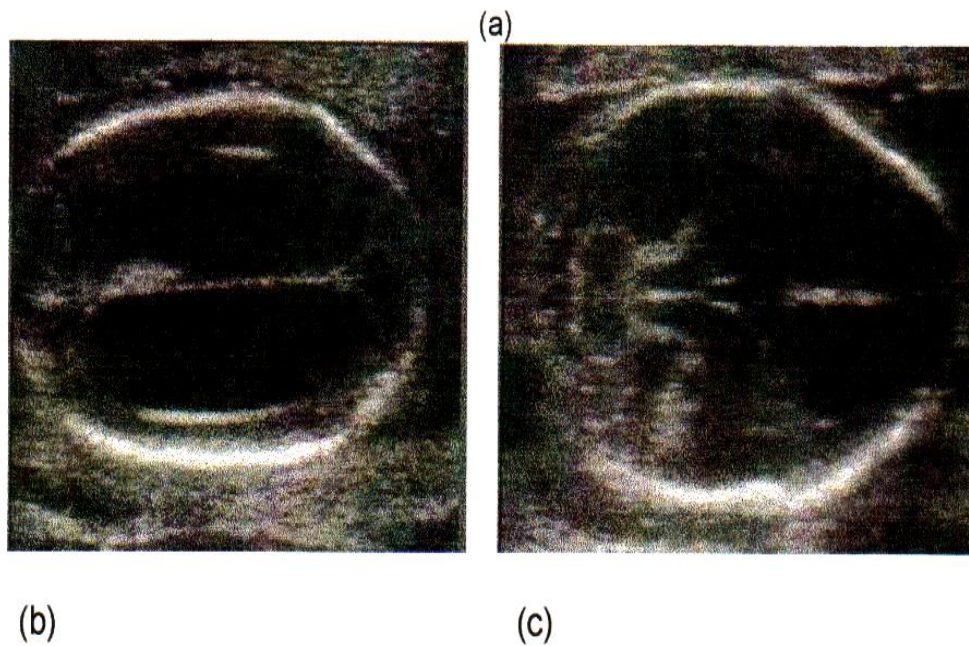
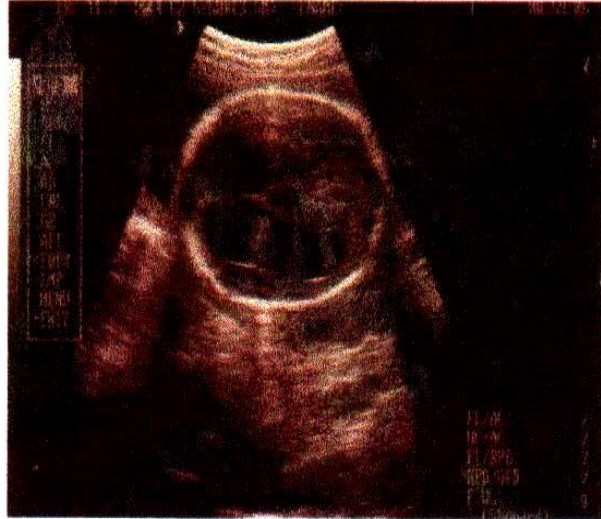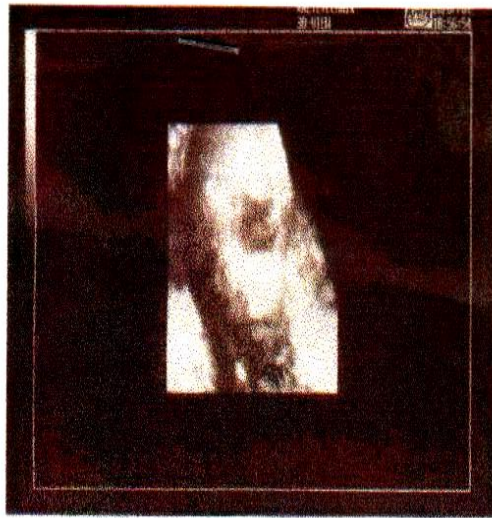
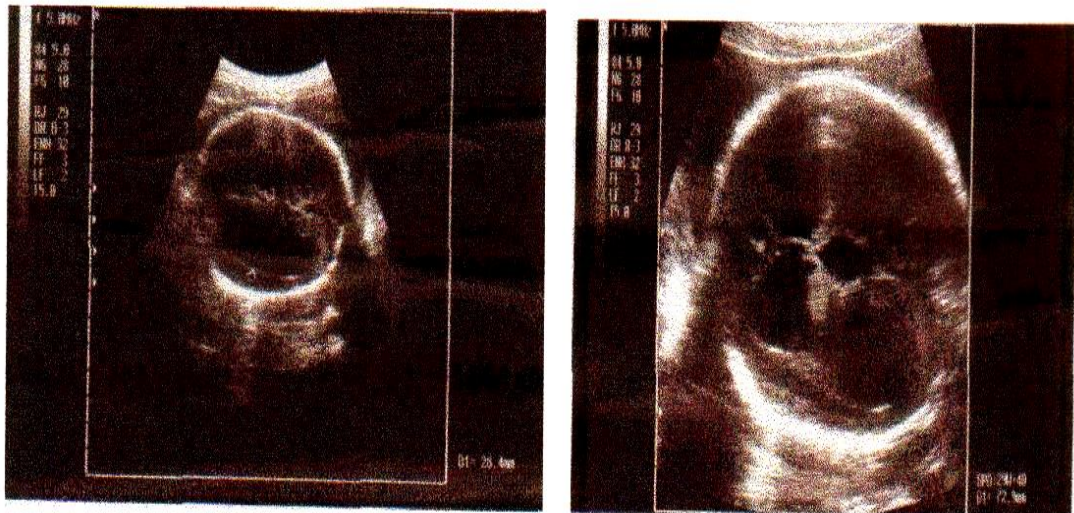


Figure 3. Two-dimensional ultrasound images of hydrocephalous in (a) 20 week gestation and (b and c) in a 27 weeks gestation of the same fetus (with two different machines), with moderate dilatation of the third ventricles and marked dilatation of the lateral ventricles (group 1)

Two-Dimensional and Three-Dimensional Ultrasonography In



(a)



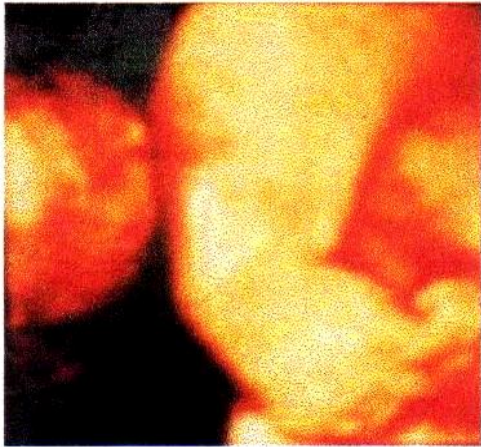
(b)

(c)

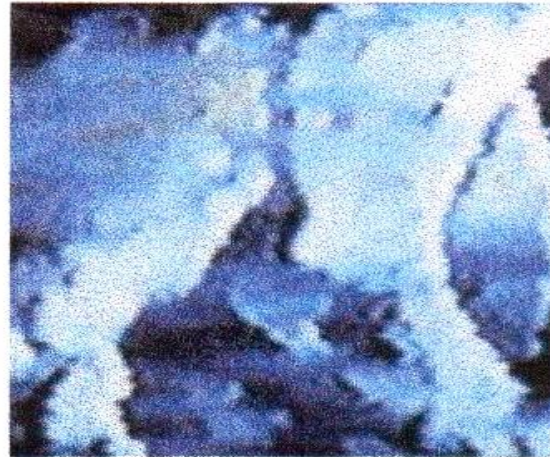
figure 4. Three and Two- dimensional ultrasound images of moderate hydrocephalous in a 29 weeks gestation fetus. In the images (a)Three dimensional surface of fetal head depicting hydrocephalus . In the images (b and c) moderate dilatation of the third and the lateral ventricles of the same fetus. group 11)

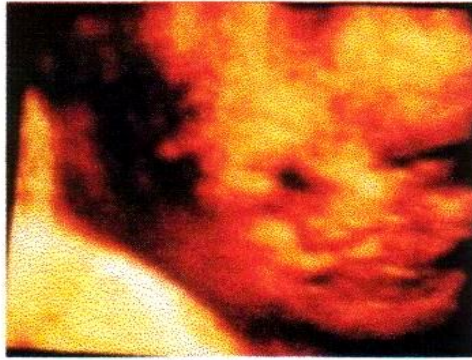

Figure 5. Three – dimensional surface image of a fetus with Cleft lip detected at 24 weeks gestation (11)



(a)



(b)

Figure 6. Three – dimensional ultrasound images of two different fetuses, image (a) Clenched hand detected at 30 weeks gestation in group 11, and image (b) Talipes equinovarus detected at 31 weeks gestation in group 1

Discussion

Many situations in which the selective use of ultrasound can provide invaluable help include localization of the placenta in cases of suspected placenta praevia, assessment of amniotic fluid volume in suspected polyhydramnios or oligohydramnios, or assistance for other procedures such as cervical cerclage or external cephalic version. In the investigation of possible fetal malformation, ultrasound can often visualize the malformation and can facilitate other diagnostic techniques, such as amniocentesis and chorion villus sampling (Neilson and Grant 1998).

One of the benefits that expected of routine ultrasonography in early pregnancy is detection of malformed fetuses. In this trial, the screened women had a lower perinatal mortality (but no increase in the proportion of live births) because of early detection and selective termination of pregnancies. Varying standards of ultrasound expertise are essential for this purpose. On the other hand, one of the main purposes of routine scanning in late pregnancy is to identify malformed baby who may benefit from elective delivery. This routine scanning in late pregnancy suggested increasing incidence of antepartum hospital admissions and of induction of labour, with no improvement in perinatal outcome. (Neilson and Grant 1998)

In the present study we did not find significant difference in detection of fetal malformation on routine antenatal use of 2-D and 3-D ultrasound examination or selective use for high-risk pregnant women for fetal malformations. We found that many fetal malformations could be diagnosed by traditional 2-D ultrasonography, yet in

some cases limitations do exist. Selective use of 3-D ultrasound imaging for the high-risk group revealed detection of seven malformed fetuses (1.4 %). Whereas, these malformations were visualized certainly with 3D ultrasound imaging, only four (0.8 %) were first precisely visualized by 2D ultrasonography (hydrocephalus, anencephaly, spina bifida and fetal hydrops). These were major anomalies that could be easily diagnosed by the traditional 2-D ultrasound whereas minor or surface anomalies could not.

On the other hand, some fetal anomalies could be visualized certainly on selective 2-D ultrasound examinations of the high-risk women, while diagnosis of the same anomalies was missed on routine 2-D-ultrasound imaging of low risk women. That may be due to small anomalies that could not be detected by 2-D imaging or limitation in the application of 2-D ultrasound examination as routine 3-D-ultrasound examination of these low risk women enabled visualization of these anomalies. Unfortunately the malformations may not be anticipated in these low risk women for getting malformed baby. Unfortunately, diagnosis of some fetal malformations is less likely to be missed when there are specific reasons to anticipate their presence. So that, great attention should be given to the importance of careful ultrasound examination of the pregnant women even in the low risk group.

Although 2-D ultrasound has been established as a reliable, cost effective and non-invasive technique for the evaluation of fetal organs, disadvantage of this technique is that the examination of the organ is usually limited to transverse and longitudinal sections, which give an incomplete view of the

structure. For complex malformations, a high degree of expertise and training is needed to translate 2-D images into the interpretation of 3-D structure. On the other hand, transabdominal route rarely permits a fully detailed fetal structural evaluation before 16 weeks. It allows detection of these anomalies between 20 to 24 weeks with accuracy (Chain et al 1997).

We found that 3-D ultrasound examination provided the same 2-D ultrasound informations in 33.36% of the diagnosed anomalies on routine examinations and 57.14% on selective use among the screened high risk group. Therefore, 3-D imaging was more accurate in diagnosing fetal malformations than 2-D ultrasound in 66.66% on routine ultrasound examinations and in 42.86% on selective examinations. This study showed that 3-D ultrasound provides more information critical for clinical diagnosis than did traditional 2-D ultrasound. In spite, our results were statistically not significant. Our results were in agreement to that of Pretorius et al, (1995) and Muller et al, (1996).

Merz et al., (1995) have reported their experience in scanning of patients with congenital anomalies, using both 2-D and 3-D ultrasonography. They found that 3-D ultrasound was worthwhile in 62% of cases, provided the same information in 36% of cases and was disadvantageous in 2% of fetuses with cardiac anomalies.

Three-dimensional ultrasound examination helped to clarify the type of fetal malformation presenting and provided a useful tool with which to explain fetal problems to parents. Various studies have already shown that 3-D ultrasound can detect or exclude not only major anomalies but also subtle abnormalities such as cleft lip or palate, auricular malformation or small

spinabifida (Steiner et al., 1994, Pretorius et al., 1995, and Muller et al., 1996).

Ludomirski et al., (1996) and Merz, (1999) reported that 3-D ultrasonography has several potential advantages over conventional 2-D scanning. They reported that one of the advantages of 3-D ultrasound examination is the generation of additional views, especially surface views, cross sectional cuts and volume renderings which offer the possibility of more accurate assessment of anatomic structures,. Another advantage is reduced scanning time, which results in more cost-effective use of equipment and sonographer's time. Merz, (1999) also reported that 3-D ultrasonography improved recognition of anomalies by less experienced physicians. They stated that 3-D scanning gives the possibility of retrospective review or consultation with specialists if any anomaly is subtle or difficult to assess or after the patient has finished the examination. They reported that 3-D scans provided more complete anatomic information than comparable optimal views obtained by traditional 2-D scanning. Therefore, Three-dimension ultrasound has been introduced into clinical practice overcoming the limitation of 2-D sonography. They also suggested that sometimes with highly expert physician and improvement in the ultrasound technology, as transvaginal ultrasound examination, some minor fetal malformations could be detected with 2-D ultrasound examinations.

Unfortunately there are many limitations of 3-D scanning as its difficulty to obtain good images when mother is obese, when oligohydramnios is present or when the fetus is in awkward position. Other problems include motion artifact, particularly of organs that have inherent motion.

Two-Dimensional and Three-Dimensional Ultrasonography

Scatter interference may be exaggerated at the surface interfaces, and as a result uneven contours may be given to surfaces (Ludmirski et al, 1996).

Merz et al, (1999) also reported that the loss of contrast or improper fetal position can sometimes cause difficulties in ultrasound examination of the fetus. They reported that 3-D ultrasound technology resolves some of these problems by allowing unlimited choices of possible viewing point by the operator and the ability to obtain ultrasound sections which are impossible to see on a routine scan, and the ability to perform accurate volume measurements. Pairleitner (1999) showed that several of these difficulties have been improved largely and the solutions of these problems are worked out primarily by the industry. Technical developments such as improvements in focusing and digital beam formation will provide better image quality. Reduction of motion artifacts will be achieved by much more data acquisition. Finally they stated that education and most important spread of any technological development and training courses are already in place for 3-D ultrasound.

This study showed that there was no significant difference in the incidence of congenital malformations and maternal or gestational age, parity, occupations, socioeconomic status, medical disorders or exposure to teratogenic agents. Whereas, Haddow and Palomaki, (1993) found a good relation between the incidence of congenital malformation and maternal age particularly Down syndrome where the incidence is much higher with advanced maternal age. On the other hand Voriheid, (2000) speculated that the low socioeconomic state or more deprived populations have a higher risk of congenital anomalies of non-

chromosomal origin. They found that maternal dietary inadequacy may be risk factor of congenital malformation especially concentrated on preconceptional folic acid containing multivitamin supplementation. The study of Schafer et al.(2000) found increasing risk of congenital anomalies in offspring of women with gestational diabetes, Type I and Type II diabetes. They suggested that the obstetricians should focused on preconceptional and early pregnancy program in women with Type I, & II and gestational diabetes to reduce perinatal mortality and malformation rates to general population levels.

Although screening programs may bring reassurance to some women who are tested, they may generate anxiety for others by merely raising the question of abnormality. The consequences of erroneous diagnoses, both positive and negative, warrant particularly careful consideration. At present, there is no sound evidence that ultrasound examination during pregnancy is harmful.

We concluded that many fetal malformations could be diagnosed by traditional 2-D ultrasonography, yet in some cases limitations do exist. There are great values of selective 3-D ultrasound examination for specific indications in pregnancy, as detection of congenital malformations in high-risk group. The adjunctive use of 3-D ultrasonography with the 2-D mode in selective cases can greatly increase diagnostic accuracy of congenital malformation.

Traditional 2-D ultrasonography was used routinely early and late in pregnancy for other obstetric indications. The place for routine 3-D ultrasound examination has not been determined as yet. We do not support the routine use of 3-D ultrasonography

in pregnancy. Such routine use should be considered experimental for the present and must be accomplished for certain practical reasons as for those pregnant women at high risk for congenital malformation. In view of the fact its safety has not been convincingly established, On the other hand, It is equally important to weigh the human costs against the benefit.

We recommend early prenatal diagnosis of congenital malformations that may improve fetal outcome and may help in successful fetal or neonatal surgery. Careful ultrasound examination of all fetal systems is essential to overcome missing diagnosis of minor fetal anomalies. For complex malformation a high degree of expertise and training is needed to overcome the limitations and problems with 2-D and 3-D Ultrasound. Future use of 4-D imaging may overcome the problems and limitations of 3-D ultrasound examination in detection of fetal malformations.

We thank Professor Dr. Ibrahim Mahrous for his great assistance in three dimensional ultrasound examinations of our cases.

References

Chain L, Uerpaiojkit B, and Reece A: Diagnosis of congenital malformations using two- dimensional and three-dimensional ultrasonography. Fetal diagnosis and therapy. Obstetrics and Gynecology clinics of North America. 1997; V 24, 1, March: 49-69

Haddow, J.E. and Palomaki, G.E. : Prenatal screening for Down Syndrome. In Simpson, J.L.; Elias, S. Eds. Essentials of prenatal diagnosis. Churchill Livingstone, 1993:185-220.

Kupesic, S. and Kurjak, A.: Septate uterus: detection and prediction of obstetrical complication by different forms of Ultrasonography. J.

Ultrasound Med. 1998; 17: 631-6.

Ludommski, A., Uerpainof, B. and Whiteman, V.E.: New technology in 3-dimensional ultrasonography. Technique advantages and limitations Am. J. Obstet. Gynecol, 1996; 174:319.

Merz, E.; Bahlman, F. and Weber/ G.: Volume scanning in the evaluation of fetal malformations: a new dimension in prenatal diagnosis. Ultrasound Obstet. Gynecol. 1995; 5:222-7.

Merz, E.: Three dimensional transvaginal ultrasound in gynecological diagnosis. Ultrasound. Obstet. Gynecol. 1999;481-6.

Muller, G.M.; Weiner, C.P. and Yankowitz: Three dimensional ultrasound in the evaluation of fetal head and spine anomalies. Obstet. Gynecol. 1996; 88:372-378.

Nilson J. and Grant A: Imaging ultrasound in pregnancy. In: A guide to effective care in pregnancy and childbirth. Oxford university press, New York , second Ed, 1998; 40-44.

Pairleitner H.: Three-dimensional color histogram using three-dimensional power Doppler. In Kurja, K.A, ed. Three dimensional power Doppler in Obstetrics & Gynecology-Carnforth, U.K. : Parthenon Publishing, 1999 : 35-9.

Pretrorius, D.H. and Nelson, T.R.: Fetal face visualization using three-dimensional ultrasonography. J. Ultrasound Med. 1995,19:349-56.

Schafer-Graf, A.M.; Buchanan, T.A. and Xiang: Patterns of congenital anomalies and relationship to initial maternal fasting glucose levels in pregnancies complicated by type 2 and gestational diabetes. Am. J. Obstet. Gynecol. 2000, Feb.,182 (2) 313-20.

Steiner, H.; Standach, A. and Spitzer, D.: Three dimensional ultrasound in obstetrics and gynaecology: technique possibilities and limitations. Hum.

Reprod. 1994; 9:1773-8.

Voriheid M. : Socioeconomic in equalities in risk of congenital

anomalies. Arch Dis. Child 2000; May., 84(5): 349-52.

الملخص العربي

الموجات فوق الصوتية ثنائية الأبعاد و ثلاثية الأبعاد في تقييم التشوهات

الخلقية للأجنة: الاستخدام الروتيني أم الاختياري

ناهله حسين محمد - سامية عبد الحميد سعودي

قسم التوليد و أمراض النساء - كلية الطب - بنات - جامعة الأزهر

يهدف هذا البحث إلى تقييم استخدام جهاز التصوير بالموجات فوق الصوتية ثنائية الأبعاد و ثلاثية الأبعاد في تشخيص التشوهات الخلقية للأجنة ومعرفة إمكانية استخدام هذه الأجهزه روتينيا أثناء الحمل أم اختياريًا لبعض الحالات المعرض اجنتها للتشوهات الخلقية

اشتمل البحث على آلف سيدة حامل من المترددات على عيادة متابعة الحمل بمستشفى الزهراء الجامعي و مستشفى باب الشعرية الجامعي . تم فحصهن خلال مدة الحمل من الأسبوع 14-32 للحمل وبمعرفة التاريخ الطبي لهن تم تقسيمهن الى مجموعتين :

المجموعة الأولى: خمسمائة سيدة حامل ذات حمل سليم . أعمارهن اقل من 35 سنة ولا يشمل تاريخهن المرضى على خطر الإصابة بالتشوهات الخلقية

المجموعة لثانية : خمسمائة سيدة حامل معرض أجنتهن لخطر الإصابة بالتشوهات الخلقية وذلك لوجود واحد أو اكثر من العوامل الآتية: 1-أعمارهن 35 سنه او اكثر

2- وجود قرابة بين الزوجين

3-إصابة أحد أبنائهن السابقين أو أحد أفراد عائلتهن بالتشوهات الخلقية

4-تعرضن للإشعاع أثناء الحمل أو أشعة اكس أو تناولن أدوية يعرف أنها قد تسبب التشوهات الخلقية للأجنة

5- الاصابه بأحد الأمراض -أثناء الحمل -التي يعرف أنها قد تسبب التشوهات الخلقية للأجنة مثل مرض السكر أو بعض الفيروسات او عدم توافق فصائل الدم بين الزوجين وغيرهم

تم عمل متابعة الحمل وعمل تصوير بالموجات فوق الصوتية ثنائية الأبعاد أولاً ثم ثلاثية الأبعاد عدة مرات أثناء الحمل لفحص جميع أعضاء الجنين و تشخيص وجود تشوهات خلقية بها.

نتائج البحث : في المجموعة الأولى أمكن تشخيص تشوهات خلقية في جنين واحد (2.%) بالموجات فوق الصوتية ثنائية الأبعاد, وثلاث حالات(6.%) بالموجات فوق الصوتية ثلاثية الأبعاد , وهذه النتيجة ليست ذات دلالة إحصائية, وفي المجموعة لثانية أمكن تشخيص تشوهات خلقية في أربع حالات(8.%) بالموجات فوق الصوتية ثنائية الأبعاد, وسبع حالات (1,4%) بالموجات فوق الصوتية ثلاثية الأبعاد , وهذه النتيجة أيضا ليست ذات دلالة إحصائية.. وبمقارنة تطبيق استخدام جهاز الموجات فوق الصوتية ثلاثية الأبعاد لم توجد فروق ذات

دلاله إحصائية بين استخدامه روتينيا في متابعة الحمل لحالات المجموعة الأولى أو اختياريًا في المجموعة لثانية الأكثر خطرا لإصابة أجنهن بالتشوهات الخلقية .
من ذلك نجد أن الموجات فوق الصوتية ثلاثية الأبعاد اكثر كفاءة في تشخيص التشوهات الخلقية من الموجات فوق الصوتية ثنائية الأبعاد. قد يرجع هذا لصغر أو تعقيد التشوهات الخلقية فلم يمكن تشخيصها بالموجات فوق الصوتية ثنائية الأبعاد . ومع ذلك توجد بعض العيوب في الموجات فوق الصوتية ثلاثية الأبعاد التي يمكن التغلب عليها بالتعليم و التدريب والتقدم العلمي والصناعي لخدمة هذه الأجهزة.
يوصى هذا البحث بالتعليم و التدريب على الموجات فوق الصوتية ثنائية الأبعاد الذي يمكن من استخدام امثل لها لزيادة إيجابيات التشخيص بها. و لا نفضل الاستخدام الروتيني للموجات فوق الصوتية ثلاثية الأبعاد لان لتكلفتها العالية التي يجب أن توزن أمام الفائدة التي ستجنى من استخدامها.