

Prevalence of Impacted Teeth and Associated Pathologies – A Radiographic Study, Al Ahsa, Saudi Arabia Population

Ahmad M. Al-Ramil¹, Ali M. Al-Wosaibi¹, Mohammed T. Bukhary¹
Mahdi M. Al-wusaybie².

¹ College of Dentistry King Saud University, ² College of Dentistry
Imam Abdulrahman bin Faisal University

Corresponding author: Ahmad M. Al-Ramil, E-mail: F_uoh@hotmail.com, mobile: 0555156989

ABSTRACT

Background: Impaction has been defined as a tooth which is prevented from completely erupting into a normal functional position within the expected time, due to lack of space, obstruction by another tooth or an abnormal eruption path^[5], inadequate bony length and insufficient development of the retromolar space with the tooth either partly visible/in communication with the oral cavity or completely invisible.

Objectives: To investigate the prevalence of impacted teeth and associated pathologies in Al Ahsa, Saudi population.

Materials and Methods: this is a retrospective study. The total record of 1985 patients were examined found 537 patients with impacted teeth and 130 patients have panoramic x-ray, digital camera was used with plastic box on x-ray viewer to stabilize the magnification.

Results: 27.1% of Saudi patients in Al Ahsa presented with at least one impacted tooth. Among the 355 impacted teeth, the mandibular third molars were the most common impacted tooth (62.3%), followed by the maxillary third molars (30.7%), and the least was the maxillary canine (1.7%). The results of this study indicated that caries was associated with 23.1% of the impacted third molars and 11.5% of the distal surfaces of adjacent second molars. The results of this study indicated that pericoronitis was associated with 61.5% of impacted third molars. Caries was associated with 23.1% of the impacted third molars and 11.5% of the distal surfaces of adjacent second molars. Root resorption was associated with 3% of the second molars that was adjacent to the impacted third molars. Dentigerous cyst was associated with one of impacted tooth.

Conclusion: The prevalence of impacted teeth was high, and there was a predominant for impaction of the mandibular third molars in this study of Al Ahsa Saudi population. Pericoronitis associated with impacted mandibular third molar were related to the erupted maxillary third molars created potential trauma of the pericoronal tissues of the partially erupted mandibular third molars. Caries and periodontal disease were commonly associated with the impacted third molars, whereas root resorption and cystic pathology were rarely observed.

Keywords: Impacted teeth, Radiographic study, Molar, wisdom teeth.

INTRODUCTION

Teeth may become impacted when they fail to erupt or develop into the proper functional location^[1]. Impaction has also been defined as a tooth which is prevented from completely erupting into a normal functional position within the expected time, due to lack of space, obstruction by another tooth or an abnormal eruption path^[2], inadequate bony length^[3] and insufficient development of the retromolar space^[4] with the tooth either partly visible/in communication with the oral cavity or completely invisible.

The principal teeth that present as impactions are either third molars or canines. The prevalence of impacted teeth varies among different populations depending on the age group, assessment method, and diversity within the sample population^[5]. Mandible third molars are considered to be the most commonly impacted teeth. Third molar impaction is reported to occur in 18% to 32%

of the population but impaction rates of up to 40% have been noted^[6].

Incompletely erupted third molar could give cause for various symptoms and pathologies, such as pericoronitis, pain, swelling, cheek ulceration, distal caries, bone loss and root resorption of adjacent teeth, odontogenic cysts, benign or malignant tumors and systemic infection^[7].

Eruption status, position and angulation have an impact on these symptoms and pathologies. A partially erupted, vertical angulated mandibular third molar, at or near the same level of adjacent second molar, is considered to have a high risk for developing pericoronitis^[8]. Likely, a partially erupted, mesioangular or horizontal angulated mandibular third molar that contacts the amelocemental junction of second molar could give rise to caries development^[9] and bone loss at the distal surface of a second molar^[10].

Panoramic radiographs have been suggested for routine third molar examination because of frequent anomalies of third molar development, morphology, position, and eruption.

Many imaging techniques have been developed to assess the precise anatomic location of impacted teeth, such as the periapical film, dental panoramic film, cross-sectional plane tomography, computed tomography (CT), and magnetic resonance imaging (MRI).

The impacted teeth that fail to attain a functional position may be abnormal and or associated with pathological changes and should be considered for removal [11]. The removal of impacted third molars is the most frequent operation performed by oral and maxillofacial surgeons due to symptoms and or associated pathology. Although it is generally considered a

safe procedure, some complications can occur during surgery or in the postoperative period.

Common postoperative complications associated with third molar extraction are: alveolitis, infection, postoperative bleeding, transient dysfunction of the inferior alveolar nerve and permanent dysfunction of the inferior alveolar nerve [12].

The literatures showed that there is considerable variation in the prevalence and distribution of impacted teeth in different regions of the jaw and in different populations (Table 1).

There is no data on the prevalence of impacted teeth and the associated pathology in Al Ahsa region of Saudi Arabia.

The aims of this study were to investigate the prevalence and pattern of impacted teeth in Al Ahsa Saudi population, and to report the features of associated pathologies.

Table (1): Prevalence and number of impacted teeth reported in the dental literature.

Authors	No. of patients with impacted teeth/total no. of patients (prevalence)	No. of impacted teeth	Upper third molar	Lower third molar	Upper canine	Lower canine	Others
<i>Ahlqwist d Grondahl,13</i>	1991 117/1418 (8.3%)	166	*	141	17	*	8
<i>Aitasalo et al,11</i>	1972 571/4063 (14.1%)	823	304	323	147	19	30
<i>Brown et al,14</i>	1982 583/1895 (30.8%)	1259	372	606	150	44	87
<i>Dachi and Howell,15</i>	1961 281/1685 (16.7%)	489	213	209	28	13	19
<i>Eliasson et al,16</i>	1961 281/1685 (16.7%)	1211	477	734	*	Not studied	Not studied
<i>Haidar and Shalhoub,17</i>	1986 323/1000 (32.3%)	1173	*	*	Not studied	Not studied	Not studied
<i>Hattab et al,18</i>	1995 78/232 (33.6%)	194	102	92	*	Not studied	Not studied
<i>Kramer & Williams,19</i>	1970 684/3745 (18.3%)	1218	717	429	*	48	24
<i>Mead,20</i>	1930 276/1462 (18.9%)	518	213	248	23	2	32
<i>Sandhu and Kapila,21</i>	1982 264/1015 (26.0%)	321	78	243	Not reported	Not reported	Not reported
<i>Shah et al,24</i>	1978 546/7886 (6.9%)	918	286	505	61	8	58
<i>Stermer Beyer-Olsen et al,27</i>	1989 22/141 (15.6%)	31	18	12	1	0	0
<i>Yamaoka et al,26</i>	1995† 155/1834 (8.5%)	181	*	Not reported	Not reported	Not reported	Not reported

MATERIALS AND METHOD

King Fahad General Hospital in Al Ahsa Eastern Province of Saudi Arabia applied a new filling system of patients in 1427H. 328733 patients opened new file between the year 1427H and 1429H. 35210 of the new file were dental patients that require dental treatment. 1985 dental cases were referred to the surgical operation room for various investigations and surgical procedures including collection of tissue specimens and surgical removal of tumors and impacted teeth. Among these, 537 cases were for the surgical removal of impacted teeth. Out of the 537 files, only 200 files were found to have panoramic radiograph and other files contains other types of radiographs such as periapical or lateral oblique that does not meet the requirement of this study. Searching the 200 files with panoramic radiographs revealed that only 130 panoramic radiographs are suitable for this study and the remaining 70 files either had no x-ray film inside the file or the panoramic radiographic is not clear and cannot be used in this study.

To study the available 130 panoramic radiographs it was necessary to duplicate or photograph the radiographs, because it was not allowed to take the radiographs outside the reception or the clinic. Duplicating machine was not available and the photography was the only solution. Photographic set up was constructed and consist of a clear cuboid shape plastic box (**figure 1**), a digital camera and a light box. The dimensions of the cuboid plastic box are 31 cm long, 20.5 cm wide and 20 cm deep. The box is open from the bottom to fit over the light box and the center of the top has a hole that fit the camera lens. Such a design was selected to give the best focus and magnification of the images and stabilize the camera relationship to




Figure 1: plastic box that used in the study

the light box and the film during removal and changing the panoramic radiographs. The digital camera is Nikon cool pix S4, 6 mega pixels, 10X optical zoom that was fitted over the cuboid plastic box during the session of photography. The light box is standard type x-ray light box gives good illumination. Each panoramic radiograph was fitted in the center of the light box by sticking tape. All the radiographs were photographed and transferred to digital images and stored in the computer. On the computer screen each image was thoroughly analyzed.

A tooth was defined as impacted when the tooth was obstructed on its path of eruption by an adjacent tooth, bone, or soft tissue. A tooth was defined as embedded if it was covered by bone without adjacent tooth obstructing its eruption path. The pathologies associated with impacted teeth included:

- (1) Caries of the impacted and/or adjacent teeth.
- (2) Pericoronitis.
- (3) Root resorption of the adjacent tooth.
- (4) An increase in the pericoronal space of the dental follicle of more than 2 mm around the impacted tooth.

Following the radiographic evaluations the patient files and records were re-studied to supplement the radiographic finding by the clinical examination and to determine from the chief complaint whether they attended the hospital for the impacted teeth or the signs and symptoms related to the impacted teeth. Data collected were entered into a spreadsheet (Excel 2007; Microsoft) and analyzed using the Statistical Package for Social Sciences (Windows version 12.0; SPSS Inc., Chicago, US).

The study was done after approval of ethical board of King Fahad Hospital.

RESULTS

The prevalence of impacted teeth in this study was 27.1% of 1985 patients that were referred to the surgical room. The range of the patient age was from 9 years to 43 years. The 130 patients with impacted teeth were divided into five age related groups with an interval of six years. **Table (2)** shows the prevalence of impacted teeth in different age-groups. The 23-29 years age group had the highest prevalence of tooth impaction 62.3%, followed by the 16-22 years (25.4%), the 30-36 years (6.9%), the 9-15 years (3.8%) and the least was the 37-43 years age group (1.5%).

Table (2): Prevalence of impacted teeth in different age-groups of patients

Age group (year)	PTS with impacted teeth	Percentage %
9 – 15	5	3.8%
16 – 22	33	25.4%
23 – 29	81	62.3%
30 – 36	9	6.9%
37 – 43	2	1.5%
Total	130	≈100%

Table (3) showed the distribution of impacted teeth. In this study 355 teeth were impacted. The mandibular third molars were most commonly encountered with 223 impaction out of the 355 impaction (62.8%), followed by the maxillary third molars with 109 impaction (30.7%), and the maxillary canines were 6 impaction (1.7%), and

maxillary central incisors were 5 impaction (1.4%), and the mandibular premolars were 4 impaction (1.2%), and the mandibular second molars were 1 impaction (0.2%). The supernumerary teeth were 7 (1.9%).

The analysis of the developmental stages and the eruptive status of the third molars in patients with impacted tooth/teeth showed that the distribution of impacted teeth was similar between the left and right sides. Out of the 332 impacted mandibular and maxillary third molars, there were 10 patients with one impacted third molar (10 impaction), 54 patients with two impacted third molar (108 impaction), 14 with three impacted third molar (42 impaction), and 43 patients with four impacted third molar (172 impaction).

Table (3): Distribution of impacted teeth

Tooth type	FDI tooth numbering	Quantity	Percentage
Mandibular third molars	38,48	223	62.80%
Maxillary third molars	18,28	109	30.70%
Maxillary canines	13,23	6	1.70%
Maxillary central incisors	11,21	5	1.40%
Mandibular premolars	34,35,44,45	4	1.20%
Mandibular second molars	37	1	0.20%
Supernumerary teeth		7	1.90%
Total		355	≈100%

Table (4) revealed the pathologies associated with impacted teeth in different age groups of patients in Al Ahsa, Saudi Arabia. 60.6% of impacted third molars had pericoronitis. 22.7% of the impacted teeth had caries on the impacted third molars. Caries were also found in 11.4% of the distal surfaces of the adjacent second molars. 3% of the second molars adjacent to the impacted third molars had root resorption on the distal surface. One of impacted tooth had dentigerous cyst.

Table (4): Pathologies associated with impacted teeth in different age groups of Patients

Age group	Pericoronitis	Caries of impacted teeth	Caries of adjacent teeth	Root resorption	Pericoronal space of dental follicle	Cysts
9-15	0	0	0	0	0	0
16-22	22	4	1	1	1	0
23-29	51	23	12	2	1	0
30-36	5	3	2	1	0	1
37-43	2	0	0	0	0	0

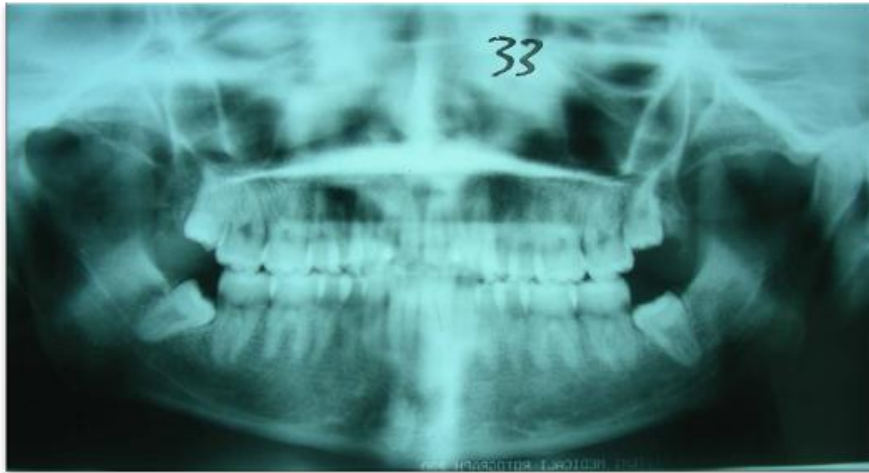


Figure (2): showing caries of adjacent tooth (#37, #47)

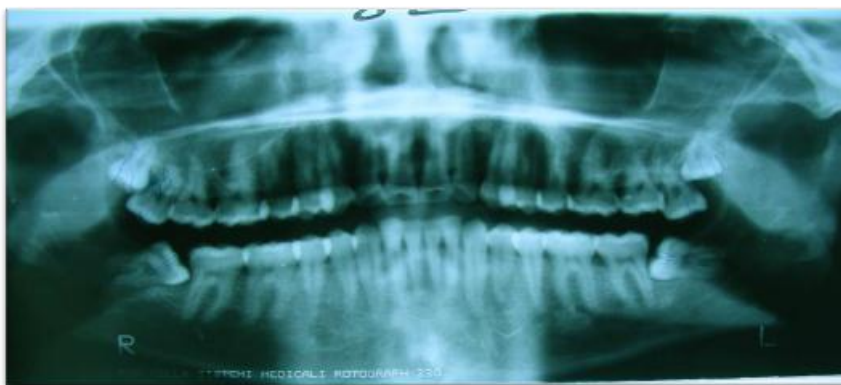


Figure (3): showing supernumerary teeth in upper right and left side

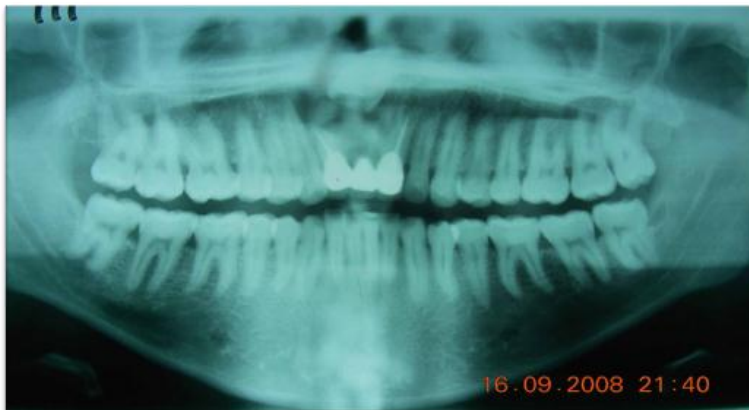


Figure (4): showing dentigerous cyst with impacted of upper central incisor.

DISCUSSION

The use of dental panoramic tomography (DPT) for the study of impacted teeth is limited to hospital dental patients and large dental practices because of associated costs and ethical considerations [21]. The photographic set utilized in this study facilitated the analysis of the DPT for the study of impacted teeth and the associated pathologies. To ensure diagnostic validity in this study, the radiographic findings were verified

with the clinical records, which were collected on standard forms as part of the routine examination process.

Impacted wisdom teeth account for 98% of all impacted teeth. The result of this study that the mandibular third molars were most commonly encountered (84.5%) is in agreement with most the previously published studies [21-22], and the impacted tooth that is most frequently extracted is the mandibular third molar. The finding in this study showed that most patients

have two impacted third molars which is in agreement with the finding of Chu et al.^[8] who also found that the Chinese patients have two impacted third molars and disagree with the finding of Ma'aita^[25] who found that most patients in Jordan have four impacted third molars. The finding of this study disagrees with Mead^[20] who found an equal prevalence of impactions in both jaws, and disagrees with Bjork et al.^[23] who noted preponderance in the maxilla. The finding of this study is in agreement with Shah et al.^[24] and Van der Linden et al.^[9] who reported a higher prevalence of impacted third molar in the mandible than the maxilla. The finding of this study disagree with Dachi and Howell^[15] who found 16.9% third molar impaction, of which 63.7% were maxillary and 36.5% were mandibular. Aydin et al.^[28] in Turkey found a prevalence of canine impaction 3.58% while in this study the finding was 1.7% of impacted canine.

This study disagree with Ma'aita^[25] who found that pericoronitis was present in 23.6% of impacted teeth compared to this study that reach to 60.6%.

Although this study may not represent the Al-Ahsa population as a whole, the patients studied represent the range of dental patients treated under general anesthesia for the various oral surgical procedures. The prevalence of impacted teeth in the study population was 27.1% out of the 1985 patients. Most age group which have impacted teeth (62.3%) were the 23-29 years, this may reflect increased dental awareness in this group of patients, mandibular third molar has 84.5% of all impacted teeth, maxillary third molars 41.7% and maxillary canine 3.03% . These numbers are comparable to those of Chu et al.^[8] in Hong Kong population.

CONCLUSION

Impacted teeth were found in 27.1% of the 1985 patients in this study. The order of impacted tooth found was identical to previous reports, but there was a predilection for impacted mandibular third molars in this study. Three quarters of impacted third molars had impacted mandibular third molars, while more than 50% of their upper counterparts had erupted. Such a combination may lead to trauma of the pericoronal tissues by the upper third molars were 61.5%. The caries of the teeth adjacent to

impacted third molars were found in approximately 11.5% of cases.

ACKNOWLEDGEMENT

We are grateful to the administration, College of Dentistry, King Saud University, Riyadh, Saudi Arabia, and to the Internship Program, and the director. We also acknowledged the help of the administration of King Fahad Hospital in Hofuf, Oral and Maxillofacial Surgery Department, Al Ahsa Eastern Province, Saudi Arabia. Thanks should be extended to the technicians, assistants, and any person who helped to finish this project. Lastly, we would like to express our sincerest gratitude to Professor M. T. Bukhary who supported and gave the guidance and inspirations as our supervisor.

REFERENCES

1. **Hattab F, and Alhaija E (1999):** Radiographic evaluation of mandibular third molar eruption space. *Oral Surgery, Oral Medicine, Oral Pathology, Oral Radiology and Endodontics*, 88:285-291.
2. **Richards D (2000):** Management of unerupted and impacted third molar teeth. *A National Clinical Guideline. Evidence-Based Dentistry*, 2:44.
3. **Forsberg C (1988):** Tooth size, spacing, and crowding in relation to eruption or impaction of third molars. *American journal of orthodontics and dentofacial orthopedics*, 94:57-62.
4. **Grover P, and Lorton L (1985):** The incidence of unerupted permanent teeth and related clinical cases. *Oral Surgery, Oral Medicine, Oral Pathology*, 59: 420-425.
5. **Chu F, Li T, Lui V, Newsome P, Chow R, and Cheung L (2003):** Prevalence of impacted teeth and associated pathologies-a radiographic study of the Hong Kong Chinese population. *Hong Kong Med. J.* 9:158-163.
6. **Niedzielska I, Drugacz J, Kus N, and Kręska J (2006):** Panoramic radiographic predictors of mandibular third molar eruption. *Oral Surgery, Oral Medicine, Oral Pathology, Oral Radiology and Endodontics*, 102: 154-158.
7. **Doğan N, Orhan K, Günaydin Y, Köymen R, Okçu K, Uçok O (2007):** Unerupted mandibular third molars: symptoms, associated pathologies, and indications for removal in a Turkish population. *Quintessence International*, 38:497-505.
8. **Yamalık K, and Bozkaya S (2008):** The predictivity of mandibular third molar position as a risk indicator for pericoronitis. *Clinical oral investigations*, 12:9-14.
9. **Van der Linden W, Cleaton-Jones P, and Lownie M (1995):** Diseases and lesions associated with third molars: Review of 1001 cases. *Oral Surgery, Oral Medicine, Oral Pathology, Oral Radiology and Endodontics*, 79:142-145.

- 10. Brickley M, Shepherd J, and Mancini G (1993):** Comparison of clinical treatment decisions with US National Institutes of Health consensus indications for lower third molar removal. *British dental journal*, 175:102-105.
- 11. Aitasalo K, Lehtinen R, and Oksala E (1972):** An orthopantomography study of prevalence of impacted teeth. *International Journal of oral surgery*, 1:117-120.
- 12. Lysell L (2010):** Current Concepts and Strategies for Third Molar Removal. *Oral and Maxillofacial Surgery*, 7:195.
- 13. Ahlqwist M, and Gröndahl H (1991):** Prevalence of impacted teeth and associated pathology in middle-aged and older Swedish women. *Community dentistry and oral epidemiology*, 19:116-119.
- 14. Brown L, Berkman S, Cohen D, Kaplan A, and Rosenberg M (1982):** A radiological study of the frequency and distribution of impacted teeth. *The Journal of the Dental Association of South Africa= Die Tydskrif van die Tandheelkundige Vereniging van Suid-Afrika*, 37:627-630.
- 15. Dachi S, and Howell F (1961):** A survey of 3,874 routine full-mouth radiographs: II. A study of impacted teeth. *Oral Surgery, Oral Medicine, Oral Pathology and Oral Radiology*, 14:1165-1169.
- 16. Eliasson S, Heimdahl A, and Nordenram A (1989):** Pathological changes related to long-term impaction of third molars: A radiographic study. *International journal of oral and maxillofacial surgery*, 18:210-212.
- 17. Haidar Z, and Shalhoub S (1986):** The incidence of impacted wisdom teeth in a Saudi community. *International journal of oral and maxillofacial surgery*, 15:569-571.
- 18. Hattab F, Ma'amon A, and Fahmy M (1995):** Impaction status of third molars in Jordanian students. *Oral Surgery, Oral Medicine, Oral Pathology, Oral Radiology and Endodontics*, 79:24-29.
- 19. Kramer R, and Williams A (1970):** The incidence of impacted teeth: A survey at Harlem Hospital. *Oral Surgery, Oral Medicine, Oral Pathology*, 29: 237-241.
- 20. Mead S (1930):** Incidence of impacted teeth. *American Journal of Orthodontics and Dentofacial Orthopedics*, 16:885-890.
- 21. Sandhu S, and Kapila B (1982):** Incidence of impacted third molars. *Journal of the Indian Dental Association*, 54:441-444.
- 22. VARRELA J (1990):** Occurrence of malocclusion in attritive environment: a study of a skull sample from southwest Finland. *European Journal of Oral Sciences*, 98:242-247.
- 23. Björk A, Jensen E, and Palling M (1956):** Mandibular growth and third molar impaction. *Acta odontologica scandinávica*, 14:231-272.
- 24. Shah R, Boyd M, and Vakil T (1978):** Studies of permanent tooth anomalies in 7,886 Canadian individuals. I: impacted teeth. *Dental journal*, 44:262-264.
- 25. Ma'aita J (2000):** Impacted third molars and associated pathology in Jordanian patients. *Saudi Dental Journal*, 12:16-19.
- 26. Yamaoka M, Furusawa K, and Yamamoto M (1995):** Influence of adjacent teeth on impacted third molars in the upper and lower jaws. *Australian dental journal*, 40: 233-235.
- 27. Stermer Beyer-Olsen E, Bjertness E, Eriksen H, and Hansen B (1989):** Comparison of oral radiographic findings among 35-year-old Oslo citizens in 1973 and 1984. *Community dentistry and oral epidemiology*, 17:68-70.
- 28. Aydin U, Yilmaz HH, Yildirim (2004):** A survey of impacted canines in Turkey. *Dentomaxillofacial Radiology*, 33:164-169.