

Role of CT Enterography in the Diagnosis of Crohn's Disease

Sherine K. Amine⁽¹⁾, Merhan A. Nasr⁽¹⁾, Ahmed M. Moustafa⁽²⁾, Rania M. Abd El Rasool⁽¹⁾

(1) Department of Radiodiagnosis, Faculty of Medicine, Ain Shams University

(2) Department of Radiodiagnosis, Faculty of Medicine, Al-Azhar University

Corresponding author: Rania M. Abd El Rasool; Mobile: 01067841674; Email: rania.abdelrasool55@yahoo.com

ABSTRACT

Background: Crohn's disease is a multifactorial chronic inflammatory disease characterized by non-caseating granuloma formation with a tendency toward remission and relapse, it affects any part of the GIT from mouth to anus with 80% small bowel involvement, most commonly the terminal ileum, with characteristic multiple discontinuous sites involvement (skip lesions) and transmural inflammation. **Aim of the Work:** The purpose of this study is to highlight the value of CT in diagnosis of (CD) and its ability to assess the degree of activity and its complications. **Patients and Methods:** This prospective study was conducted on 87 patients with GIT symptoms where CTE was performed to evaluate its possible impact on accurate diagnosis, detection of complications and consequent guidance for management planning. It was performed in radiological department of Ain –Shams University hospital: CT Unit in the period from “July 2017 to April 2018. The patients’ age ranged between (24 – 72 years) with a mean of 48 years. **Results:** Of the 87 patients with GIT symptoms that were highly suggestive of inflammatory bowel disease evaluated, 32 were UC, 21 were CD, 9 were other types of IBD and 25 were normal. Of the 21 CD patients evaluated, 7 were male and 14 were female. **Conclusion:** The role of MDCT in the diagnosis of Crohn’s disease and its complications is undeniable, with a proven efficacy in identifying the enteric and extra-enteric manifestations of the disease. However, advancements in CT E protocol design have allowed increasing accuracy in diagnosis, and the acquisition of studies at a much lower radiation dose. **Recommendations:** Further studies on a larger scale of patients are needed to confirm the results obtained by this study.

Keywords: CT enterography, small bowel, Crohn's disease (CD).

INTRODUCTION

Crohn's disease (CD) is an idiopathic chronic inflammatory disease of the gastrointestinal tract that has varying levels of severity, diverse manifestations, and an unpredictable course. It may affect any part of the gastrointestinal tract from mouth to anus. Signs and symptoms often include abdominal pain, diarrhea (which may be bloody if inflammation is severe), fever, and weight loss⁽¹⁾.

The etiology of Crohn’s disease is complex and likely multifactorial, with genetic, immunologic, infectious, microvascular, and possibly environmental and lifestyle factors contributing⁽²⁾.

Enteric involvement tends to be segmental, and inflammation often is transmural. Superficial mucosal (aphthous) and deep linear ulcers may be present, separated by segments of uninvolved mucosa, depending on the severity and chronicity of Crohn’s disease⁽³⁾.

Barium small bowel follow-through (SBFT) studies and enteroclysis have been the traditional radiologic standards of reference for assessment of the small bowel. However, both techniques may fail to clearly depict extraluminal complications such as fistula and abscess formation, and both have limited sensitivity, particularly when there are overlapping pelvic loops. In addition, there is a radiation burden with both techniques⁽⁴⁾.

Conventional Enteroclysis (CE): Crohn’s disease has been traditionally investigated with the use of small bowel barium enteroclysis, which

detects early mucosal disease (sens. 69.6%, spec. 95.8%) as well as complications such as strictures, fistulae, and abscesses (diagnostic accuracy 80.3%)⁽⁵⁾. Computed tomography enterography (CTE) is undoubtedly a superior imaging test compared with SBFT. It is more sensitive and reproducible, can detect extraluminal complications, and is faster and better tolerated. A potential downside of CTE is that the radiation doses are higher than SBFT. The radiation dose from a single CTE is not particularly concerning, and newer CT techniques have shown a significant decrease in radiation dose using modified protocols and reconstruction algorithms⁽⁶⁾.

CT Enterography plays an invaluable role in the evaluation of acutely ill patients with Crohn’s disease, particularly when there is concern for high-grade obstruction, perforation, or abscess. The combination of a short examination time, single-breath-hold scanning, and widespread availability ensures that CT will continue to play an important role in the care of these individuals. However, CT enterography has a high radiation burden, especially in young patients, who may require multiple examinations over several years⁽⁴⁾.

MR imaging of the small bowel combines a high-tissue-contrast examination with multiplanar interrogation of the abdomen and pelvis. There is no ionizing radiation burden, a major advantage in young patients. Furthermore, like CT enterography, MR imaging allows excellent depiction of the complications of inflammatory bowel disease⁽⁵⁾.

The speed of CTE is its greatest advantage over MRE. Due to short acquisition times, images are free of motion artifacts caused by normal intestinal peristalsis even without administration of antiperistaltic agents (e.g., glucagon). Clear, motion-free images allow confident assessment of hyperenhancement and bowel wall thickening, with excellent interobserver agreement. Multi detector row CT scanners allows high spatial resolution imaging of the entire abdomen and pelvis in just a few seconds, generating isotropic images that can be reconstructed in multiple planes to facilitate visualization of subtle abnormalities. CT scans are typically informed for IBD evaluation of both oral and IV contrast to detect bowel wall abnormalities and abnormal enhancement ⁽⁶⁾.

AIM OF THE WORK

The purpose of this study is to highlight the value of CT in diagnosis of Crohn's disease and its ability to assess the degree of activity and its complications.

PATIENTS AND METHODS

***Patients:**

The present study is a prospective research work that included 87 patients with GIT symptoms where CTE was performed to evaluate its possible impact on accurate diagnosis, detection of complications and consequent guidance for management planning.

This study was performed in radiological department of Ain –Shams University hospital: CT Unit in the period from “July 2017 to April 2018. The patients' age ranged between (24 – 72 years) with a mean of 48 years.

• **Inclusion Criteria:**

Young adult patients aged between 20-60 years, who had positive pathologic results and/or barium follow through suggestive of Crohn's disease.

• **Exclusion Criteria:**

- Young children who need follow up.
- Pregnant women will be excluded.

***Image Analysis:**

Imaging analysis including Computed Tomography Enterography reading was performed under the guidance of two qualified consultants of radiology, M.D. certified (Professor and lecturer- of radiology). Imaging- guided biopsy for the detected masses was performed by the consultants. The film readers were blind to each other's analysis as well as to the pathology results at the time of initial evaluation. At the stage of final evaluation, there was a multidisciplinary discussion of cases with the referring physician.

***Methods:**

Computed Tomography Enterography:

CT enterography data sets from 87 GIT symptoms complaining from one or more of the following symptoms: vague abdominal pain, chronic diarrhea, recurrent vomiting and unexplained anemia. Patients undergoing ileoscopy were examined for three different CT parameters: CT bowel enhancement, as defined by the ratio of terminal ileal versus control ileal loop attenuation; vascular enlargement of the vasa recta (“the comb sign”); and mesenteric fat density. Correlations between CT scan parameters, endoscopy, and histology severity scores.

This was a cross-sectional, retrospective, observational study, undertaken at a single institution between June 2017 and April 2018. The study was approved by the Research Ethics Committee of the Ain Shams University of Medicine. All patients gave written informed consent.

We included 87 patients with clinical suspicion of IBD, 21 consecutive patients with a clinical diagnosis of Crohn's disease, and for all of them CT enterography was indicated because of suspicion of inflammatory activity or complications related to the disease.

The exclusion criteria were as follows: patients who refused to participate in the study; having a history of severe allergic reaction to iodinated contrast medium; having renal failure; and presenting with any other contraindication to abdominal CT involving the use of iodinated contrast medium.

Methods of Study:

- Full clinical assessment including recording of age, sex and presentation.
- Revision of the patient's laboratory investigations including renal function tests (blood urea and serum creatinine).
- Revision of the radiological & endoscopic diagnostic investigations previously done for the patients.

Patients were scheduled to undergo CTE and the results were compared to the upper and lower GIT endoscopies, the laboratory and histopathology results in all patients.

CTE Examination:

- The patients included in this study were examined by using GE 64 channels MSCT scanners.
- Prior to the examination, the patients had been fasting for at least 6 hours.
- A large bore (18-gauge) intravenous line was placed in the antecubital fossa.
- Negative oral contrast medium solution was given; (a mixture of 1250 cc of water and 250 cc of lactulose 67%) and was given within 50

minutes in a continuous regular manner (250 cc every 10 minutes).

- The patients were instructed to follow the breath hold technique. The examination takes about 10 seconds in 64 channels MSCT scanners.
- IV spasmolytic drug (Hyoscine-N- butyl bromide 0.2 mg / Kg body weight) was given just before imaging to relax any smooth muscle spasm that mimics bowel wall thickening & abnormal enhancement. Five patients did not take the spasmolytic drug due to presence of contraindications. eg; glaucoma, cardiac disease and prostatic enlargement
- IV contrast medium (about 70 – 120 ml) of non ionic contrast medium iopromide (Ultravist 300; Berlin, Germany) according to the body built (1.5 ml/kg body weight) was given by infusion pump at rate 3 ml/second.
- The patient lies supine on the examination table and images were obtained from the diaphragm superiorly down to the symphysis pubis as determined from the scout image.
- Portal phase images were obtained usually 30 to 40 seconds after initiation of IV contrast.
- All imaging was performed with slice collimation 2.5 mm, Pitch 1 to 1.5, matrix 512x512, 200 to 350 milliamper and 120 to140 kilovolt.
- Total scanning time of 20 to 30 seconds on the 4 channel multi-slice CT scanners while 6 to 10 seconds on 64 multi-slice CT scanners.
- From this data set, the technologist will generate a set of axial 3 mm sections and a set of 3 mm thick coronal, sagittal and oblique multi-planar reformatted images at 3 mm intervals encompassing the entire bowel.

*** Histopathologic Diagnoses:**

The histological evaluation of the inflammatory activity in the bowel wall served as a reference standard. After macroscopic examination, endoscopic and surgical bowel specimens underwent fixation with formalin and standard hematoxylin-eosin safran stain and microscopic analysis. The extent of inflammatory activity was reported by a pathologist with experience in inflammatory bowel disease who was blinded for clinical, biological and radiological data.

In 21 cases the finding of Crohn's disease was detected as transmural (full-thickness) inflammation, involvement of discontinuous segments of the intestine (skip areas), and, in a proportion of cases, by non-necrotizing granulomas composed of epithelioid histiocytes. Patients present with a range of symptoms, including crampy abdominal pain and diarrhea, which may be complicated by intestinal fistulas, particularly after

surgical intervention, by intramural abscesses, and by bowel obstruction

In 32 cases the finding of UC was detected as diffuse (contiguous and symmetrical) inflammation, restricted to the colonic mucosa. Overall, the resected specimen will show diffuse mucosal granularity, edema, and erythema with or without ulceration.

Statistical Analysis

Basic descriptive data were expressed as medians with interquartile range (Q1–Q3). Calculations were performed with SPSS 22 (IBM, Armonk, New York, USA). Spearman's rank correlation coefficient was calculated for potential CT-biomarkers and histological inflammatory activity score. By convention between 0.0–0.2 was regarded as negligible, 0.2–0.4 as weak, 0.4–0.7 moderate, 0.7–0.9 strong, and 0.9–1.0 very strong correlation. Multiple testing was compensated for by the Bonferroni-Holm method.

RESULTS

Of the 87 patients with GIT symptoms that were highly suggestive of inflammatory bowel disease evaluated, 32 (36.8%) were UC, 21 (24.2%) were Crohn's disease (CD), 9 (10.3%) were other types of IBD and 25 (28.7%) were normal.

Of the 21 Crohn's disease patients evaluated, 7 (33%) were male and 14 (67%) were female. Ages ranged from 28 to 65 years (mean, 39.5 years). The mean time since the onset of symptoms was 11.2 years (range, 1-17 years).

Table (1): Case distribution among the studied cases

	No.	%
UC	32	36.8%
CD	21	24.2%
Other types of IBD	9	10.3%
Normal	25	28.7%

21 patients diagnosed with Crohn's disease were included in a retrospective study (7 male, 14 female, median age 32 years). Abdominal CT imaging was carried out on symptomatic patients at a single institution 0–10 days prior to endoscopic biopsy or surgery using a protocol optimized for the characterization of structural bowel alterations. Image data were initially reviewed independently by two radiologists and discrepancies were settled in consensus with a focus on mesenteric fat stranding and combing, mesenteric adenopathy, mesenteric abscess, intraperitoneal free fluid, fistula, skip lesions, highest wall thickness and the localization of the affected bowel. The extent of inflammatory activity in the bowel wall was determined subsequently by histological analysis.

Table (2): Sex distribution among the studied CD cases

	No.	%
Males	7	33%
Females	14	67%

All intestinal and extraintestinal CT findings except the mesenteric comb sign showed a tendency towards higher extent or prevalence in patients with high histological inflammatory activity score, especially median bowel wall thickness (6.0 mm vs. 3.5 mm), mesenteric abscesses (32% vs. 0%) and mesenteric adenopathy (94% vs. 45%). Spearman rank order correlation coefficient indicated a significant correlation of bowel wall thickness ($r = 0.40, p < 0.05$), mesenteric adenopathy ($r = 0.54, p < 0.05$), mesenteric abscess ($r = 0.33, p < 0.05$) and mesenteric fat stranding ($r = 0.33, p < 0.05$) with the histological inflammatory activity score.

CT enterography data sets from 21 Crohn’s disease complaining from one or more of the following symptoms: vague abdominal pain, chronic diarrhea, recurrent vomiting and unexplained anemia.

- Vague abdominal pain was the most common presentation. It is encountered in 14 patients.
- Three patients presented with chronic diarrhea.
- Two patients presented with recurrent vomiting & constipation.
- Two patients presented with anemia.

Anatomical location of the small intestinal disease:

According to the small intestinal segments which is divided into proximal duodenum, middle jejunum and distal ileal loops, the percentile prevalence of lesions among them is shown in Table 3. We found that most intestinal lesions were seen within the ileum.

Table (3): Distribution of the lesions at different small intestinal segments & their percentage.

Intestinal segment	Number of patients	Percentage
Duodenum	6	28%
Jejunum	6	28%
Ileum	9	44%

All patient data sets showed diagnostic image quality.

Specifically, image quality was estimated to be excellent in the majority (17/21) of patients. Good image quality was found in 3/21 and moderate image quality in 1/21 patients, in such cases it was mainly due to mild respiratory motion artifacts.

Considering the relatively small number of individuals with low to moderate inflammatory activity score, we formed two patient groups (score = 0–2 vs. score = 3) for the tabular display of descriptive data (Table 4). Notably, the extent of

bowel wall thickness (6.0 mm vs. 3.5 mm), and the prevalence of mesenteric abscesses (32% vs. 0%) and mesenteric adenopathy (94% vs. 45%) tended to be higher in patients with a high inflammatory activity score (Table 4).

Table (4): Prevalence or extent of CT findings in relation to histological inflammatory activity.

CT-based biomarkers prevalence (%)/extent (mm)	Histological inflammatory activity score	
	0–2	3
Wall thickness	3.5 mm (Q1 = 1.3; Q3= 4.0)	6.0 mm (Q1= 5.0; Q3= 7.0)
Mesenteric fat stranding	73%	94%
Mesenteric comb sign	64%	48%
Mesenteric lymphadenopathy	45%	94%
Mesenteric abscess	0%	32%
Intraperitoneal free fluid	18%	39%
Fistula	27%	38%
Skip lesions	45%	60%

Efficiency of MSCTE technique in detecting different intestinal lesions:

The ability of CT to depict small bowel abnormalities with a sensitivity of 100%, a specificity of 95%, a positive predictive value of 94% and a negative predictive value of 100%.

The detection rate of complications by CTE as fistulae, strictures and abscesses is 96.3%, 61.6% and 89.9% respectively.

The prevalence of CT findings in the abdominal digestive tract including mesenteric fat stranding, mesenteric adenopathy, mesenteric abscess, intra-peritoneal free fluid, fistula and skip lesions as well as the extent of bowel wall thickening tended to be higher in patients with high histological inflammatory activity score (score = 3) compared to patients with low to moderate inflammatory activity (score = 0–2). The prevalence of the mesenteric comb sign tended to be lower in patients with high inflammatory activity.

Spearman rank order correlation coefficient Rho calculated for the extent of bowel wall thickening, the presence of mesenteric fat stranding, adenopathy, and abscesses with histological inflammatory activity score in Crohn’s disease.

Case 1

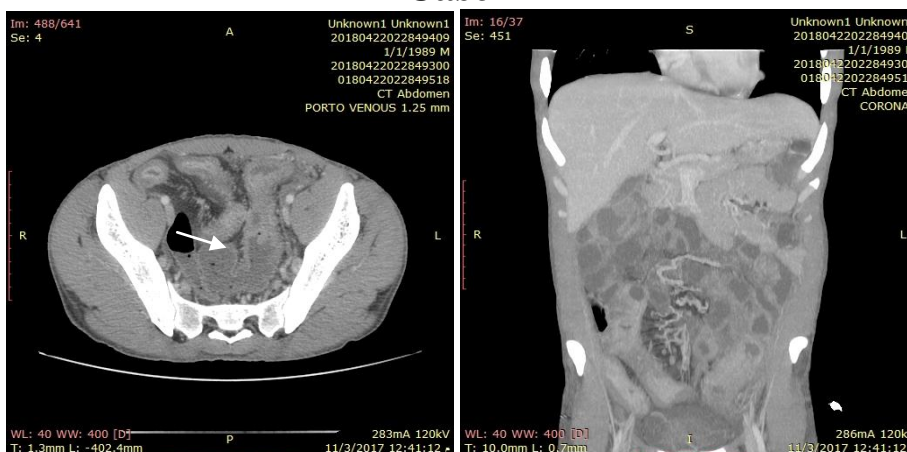

Figure (1): The axial and coronal CT enterographic picture is highly suggestive of active penetrating Crohn's disease of the ileum and sigmoid colon, with deep fissuring/ulcerations, and adherence of the ileal and sigmoid loops mounting to fistulous formation (arrow).

Pathological diagnosis:

- Crohn's disease with Surface ulceration and fissuring.

Case 2

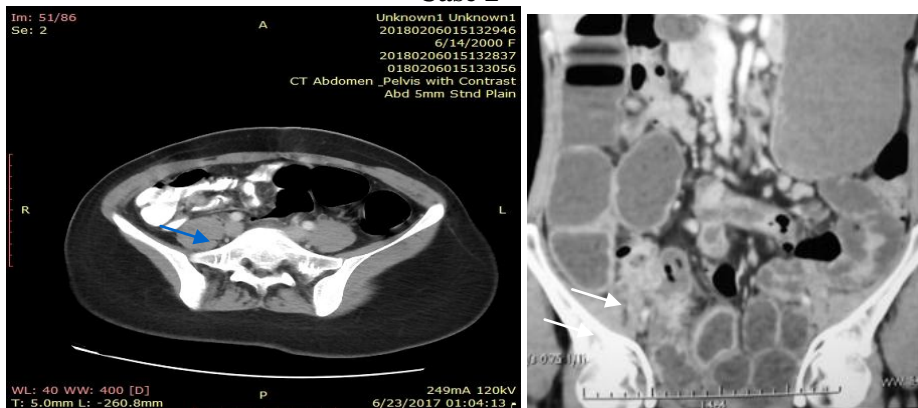


Figure (2): Axial and coronal CT enterography shows ileocecal wall thickening (arrows) with surrounding smudging of fat planes and surrounding pericolic LN

Pathological diagnosis:

Picture of chronic phase of Crohn's disease.

DISCUSSION

The case series consisted of patients who had a CT abdomen done as part of their investigations and a final diagnosis of GIT symptoms. The CT films were reviewed and findings evaluated for distinctive features.

Crohn's disease is regarded as an unpredictable, relapsing, transmural inflammatory disease potentially affecting any part of the GIT. It usually involves the large intestine and the distal small bowel causing inflammation, ulcerations, bleeding and ultimately fibrosis and scarring of the GIT wall (8).

Proper diagnosis of Crohn's disease is challenging and requires multiple tests. Diagnosis is based on medical history, physical examination, laboratory tests, endoscopy including biopsy and

imaging studies. The Montreal classification with age at diagnosis, location, behavior and the Crohn's disease Activity Index (CDAI) are widely used for disease assessment and therapy stratification. However, these scores are unreliable in differentiating remission and active Crohn's disease (8).

Currently, endoscopy and biopsy are the gold standard for assessing the inflammatory activity of Crohn's disease. Nevertheless, diagnosis in the small bowel disease is difficult to achieve, because common endoscopy is limited to the colon and distal small bowel. Furthermore, endoscopic examination including biopsy is not always immediately available and can be stressful for the patient. In contrast, CT imaging is widely available and provides a non-invasive method for the evaluation of the entire GIT including

extraintestinal manifestations and complications of Crohn's disease, which are not visible by endoscopy⁽⁸⁾.

CT and MRI are the imaging modalities of choice to depict the localization and Crohn's disease severity and provide information on disease activity. Imaging of the morphological characteristics of Crohn's disease include assessment of mucosal alterations, transmural involvement and extraintestinal manifestations. In this context, CT may provide image-based biomarkers for the inflammatory activity of Crohn's disease, which could further contribute to effective therapy stratification. Here we explore the potential value of CT morphologic pattern as predictor of inflammatory activity in Crohn's disease⁽⁸⁾.

In our study Crohn's disease diagnosis was based on four pillars: clinical history, endoscopy, imaging/radiology exams and histopathology. Undoubtedly, colonoscopy is the election test for Crohn's disease diagnosis by allowing a complete view of the entire colon, ileocecal valve and terminal ileum, which are the anatomical areas most commonly affected, as well as, performing biopsies of the involved areas, mandatory for definitive diagnosis.

Azevedo and Martins⁽⁹⁾ also found that the characteristic endoscopic findings include skip lesions, aphthous ulcers and a mucosal pattern in cobble stone, frequently involving the terminal ileum and sparing the rectum.

Histological findings in favor of the chronicity of the inflammatory process are the distortion of architecture, increased cellularity in the lamina propria, metaplasia of the pyloric gland and Paneth cells. Although the presence of granulomas is highly suggestive of Crohn's disease, it is not considered pathognomonic and can be found in many other conditions including Ulcerative colitis, tuberculosis and sarcoidosis⁽¹⁰⁾.

Azevedo and Martins⁽⁹⁾ stated that the CTE has the advantage of presenting a high spatial resolution, allowing the visualization of the entire bowel, with no overlap of intestinal loops, allowing the observation of the intestinal wall, the detection of extra-luminal disease and other potential alterations associated. In fact, the fine cuts and multiplanar reconstructions that this imaging technique allows, can overcome barriers to view the small intestine such as the superposition of loops and its extension.

CT imaging was performed using a GE 64 row MDCT unit and using an imaging protocol dedicated to the assessment of structural alterations of the GIT.

In our study distension of small bowel loops was obtained by administration of

approximately 1.0 L oral contrast medium (3% Gastrografin solution, meglumine diatrizoate, Bristol-Myers Squibb) over 60 min. Intravenous contrast of 100 mL iopromide (Ultravist 300, 300 mg iodine/mL; Bayer Health Care Pharmaceuticals Inc, Wayne, NJ) was injected at a rate of 3.0 mL/sec and bolus-tracking with a region of interest in the descending aorta at the level of the first lumbar vertebra was applied to generate enteric phase CT data. Image acquisition started at 35 s after the trigger (trigger threshold level 100HU [Hounsfield Unit]) during breath hold at a mean inspiratory level. Axial and coronal CT images (slice thickness 0.5 mm, reconstruction interval 0.3 mm) were reconstructed and transferred to a picture archiving and communication (PACS) system for image interpretation.

Image data were independently reviewed by two experienced radiologists who were blinded to clinical or histopathological data. Discrepancies were settled in consensus. The presence or absence of potential CT findings related to Crohn's disease including mesenteric fat stranding, comb sign, mesenteric adenopathy, mesenteric abscess, free intraperitoneal fluid, fistula, skip lesions, wall thickness and localization of the affected bowel segment were reported. The maximum wall thickness of inflamed bowel was quantified by manual measurement on axial or coronal image reconstructions, depending on the most appropriate image orientation.

In our study we found that the onset of Crohn's disease is between 20 and 40 years with no significant difference between men and women. This was also found by *del Val*⁽¹¹⁾ who reported that many people with Crohn's disease had symptoms for years prior to the diagnosis. The usual onset was between 15 and 30 years of age, with equal incidence among men and women.

In nearly half of the patients with Crohn's disease was seen in both the small and large bowel. In approximately one third of the patients, inflammation was isolated to the small bowel (mostly in the terminal ileum). Inflammation was confined to the colon in up to 20% of the patients while *Laghi et al*⁽¹²⁾ stated that the ileum is the most common site affected in Crohn's disease. Our study showed that more evident lesions were seen within the ileum & other small bowel segments rather than the colon.

In the present study, we aimed to explore the potential value of various intestinal and extraintestinal MDCT-based morphologic patterns to evaluate the extent of inflammatory activity in Crohn's disease. Inflammatory activity determined by histological analysis was highly prevalent (95%) in this patient cohort. Imaging patterns of inflammatory bowel alterations were detected by

MDCT in 21 subjects with active Crohn's disease, confirming the ability of CT to detect inflammation in patients with inflammatory bowel disease. This finding is supported by *Paquet et al.* ⁽⁸⁾ who found a high sensitivity of CT enterography in the diagnosis of Crohn's disease with CT and demonstrated the ability of CT to differentiate between inflammatory and fibrostenotic lesions.

The main localization of inflammation was found in the ileum and ileocolic region in 23% of lesions with low to moderate inflammatory activity and in 67% of lesions with high activity. This allows MDCT to play to its strengths, since small bowel loops are difficult to reach with endoscopy, accompanied by increased risk for bleeding, perforation and capsule retention if capsule endoscopy is performed.

The detection rate of complications by CTE as fistulae, strictures and abscesses is 96.3%, 61.6% and 89.9% respectively.

We found a significant correlation of MDCT-based patterns of bowel inflammation and the histological inflammatory activity score. In this context, four different patterns appeared to be valuable predictors of inflammatory activity: mesenteric adenopathy (highest correlation), bowel wall thickness (moderate correlation) and mesenteric abscess/fat stranding (weak correlation) with the histological inflammatory activity score. Consequently, mesenteric adenopathy showed high prevalence in patients with high inflammatory activity (94%) compared to patients with no or low activity (45%). Mesenteric fat stranding showed high prevalence both in patients with high (94%) as well as moderate inflammatory activity (73%).

Abscesses were infrequent and found in subjects with high inflammatory activity. Bowel wall thickness was almost twice as high in patients with high inflammatory activity (6.0 vs. 3.5 mm).

Results of *Paquet et al.* ⁽⁸⁾ also showed CT findings of small bowel obstruction secondary to Crohn's disease with a thickened small bowel wall and luminal narrowing that was evident at the transition zone in most of examined patients.

Skip lesions or fistula did not correlate with the histological inflammatory activity score, since such findings reflect chronic inflammation, and our patient cohort suffered from acute onset inflammation. Additionally, mesenteric comb sign did not correlate with histological inflammation, since it is also mainly found in patients with chronic inflammation and only in few patients with acute inflammation ⁽⁸⁾.

Comb sign is detected in up to 60% in patients with inactive ulcerative colitis and up to 8% of patients with Crohn's disease. This finding is supported by *Paquet et al.*, ⁽⁸⁾ who found that comb

sign may also be seen in radiation enteritis, graft versus host disease, and chronic ischemic bowel. The localization of Crohn's disease did not correlate with inflammatory activity, which is not surprising because Crohn's disease can potentially occur anywhere in the GIT.

The distinction between active disease and disease in chronic phase is very important so that the most appropriate treatment can be applied. Patients with imaging findings characteristic of acute disease benefit from treatment with corticosteroids while in the chronic phase the best treatment option involves surgery or other invasive procedures ⁽⁹⁾.

Regarding CTE, the presence of wall thickening, increased enhancement of the intestinal wall, wall stratification, densification of the mesenteric fat, engorgement of the vasa recta, lymphadenopathy, fistulae and abscesses, are considered suggestive imaging findings of Crohn's disease's active phase ⁽⁹⁾.

The predictive value of intestinal and extraintestinal CT findings for inflammatory activity of Crohn's disease may be of relevance in subjects whose pathology is located mainly in small bowel segments, which are difficult to access by endoscopy. In such cases, MDCT may provide additional information about the status of inflammation and help to guide therapy. Moreover, the value of CT imaging in Crohn's disease lies not only in the estimation of inflammatory activity. CT imaging offers the opportunity for detection of extraintestinal manifestations of Crohn's disease, such as spondylarthritis and sacroiliitis. Also extraluminal abscess or the extent of a perforation cannot be pre-estimated by endoscopy. These findings were also noted by *Paquet et al.* ⁽⁸⁾ who noted that ileoscopy offers a very limited access to the small bowel due to its localization to the terminal ileum.

Paquet et al. ⁽⁸⁾ found that MDCT provides a total overview of the small bowel. Moreover, MDCT allows for the detection of metastases of malignant diseases, which are hidden from endoscopy. This is of relevance since patients with Crohn's disease are at increased risk of small bowel adenocarcinoma and lymphoma, which can result in liver metastasis and adenopathy. Therefore, the predictive value of MDCT for inflammatory activity will not lead to a replacement of endoscopy, but MDCT is able to provide complementary information with regard to small bowel inflammation, extraintestinal manifestations and possible malignant comorbidities.

Paquet et al. ⁽⁸⁾ stated that there are several limitations of our study. First of all, the radiation exposure of patients and the cancer risk due to the cumulative radiation dose of CT in young patients

are limiting factors. Furthermore MDCT has a lower spatial resolution compared to conventional enterography. MRI is an alternative noninvasive imaging technique that can be used as a radiation-free alternative for evaluation of patients with Crohn's disease. But in an emergency setting CT is widely used in patients with abdominal pain.

In addition *Paquet et al.*⁽⁸⁾ found that MDCT is less stressful for the patient in the acute period of Crohn's disease compared to MRI since it is faster and less confining. Often a MDCT scan is performed as the first imaging method to rule out acute abdominal pathology resulting in the diagnosis of Crohn's disease. CT is also the fastest and most cost effective imaging method.

It is generally accepted that new CT techniques and advances in post processing, e.g. iterative reconstructions, are an excellent choice for radiation dose reduction without compromising image quality. *Paquet et al.*⁽⁸⁾ used an effective dose of approximating 1 msv in patients with Crohn's disease to confirm the feasibility of sub-millisievert abdominopelvic CT.

In conclusion, to prove the value of CT in the clinical assessment of Crohn's disease prospective studies are needed to determine whether information gained from CT actually changes clinical decision-making and outcomes⁽⁸⁾.

The speed of CTE is its greatest advantage over MRE. Due to short acquisition times, images are free of motion artifacts caused by normal intestinal peristalsis even without administration of antiperistaltic agents (e.g., glucagon). Clear, motion-free images allow confident assessment of hyperenhancement and bowel wall thickening, with excellent interobserver agreement.

Multi detector row CT scanners allows high spatial resolution imaging of the entire abdomen and pelvis in just a few seconds, generating isotopic images that can be reconstructed in multiple planes to facilitate visualization of subtle abnormalities .CT scans are typically informed for IBD evaluation of both oral and IV contrast to

detect bowel wall abnormalities and abnormal enhancement.

REFERENCES

- 1) **Baumgart DC, Sandborn WJ and Sandborn Y (2012):** "Crohn's disease". *The Lancet*, 380 (9853): 1590–605.
- 2) **De Hertogh G, Aerssens J, Geboes KP, Geboes K (2008):** Evidence for the involvement of infectious agents in the pathogenesis of Crohn's disease. *World J Gastroenterol.*, 14:845–852.
- 3) **Gramlich T and Petras RE (2007):** Pathology of inflammatory bowel disease *Semin Pediatr Surg.*, 16:154–163.
- 4) **Jaffe TA, Gaca AM, Delaney S et al. (2007):** Radiation doses from small-bowel follow-through and abdominopelvic MDCT in Crohn's disease, *Am J Roentgenol.*, 189: 1015–1022.
- 5) **Wiarda Bart M, Kuipers E, Heitbrink M et al. (2006):** MR Enteroclysis of Inflammatory Small-Bowel Diseases, *AJR.*, 187:522-531.
- 6) **Grand T and Mayo-Smith V (2011):** Imaging in medicine: Imaging Crohn's disease: comparing the benefits of CT & MR enterography *Imaging Med.*, 3(5), 489–492.
- 7) **Kayhan A, Oommen J, Dahi F, Oto A et al. (2010):** Magnetic resonance enterography in Crohn's disease: Standard and advanced techniques. *World J Radiol.*, 2(4): 113-121.
- 8) **Paquet AN, Glickman JN, Erturk SM, Ros PR, Heverhagen JT and Patak MA (2016):** Crohn's disease Activity: Abdominal Computed Tomography Histopathology Correlation: *Eur J Radiol Open*, 3: 74–78.
- 9) **Azevedo AC and Martins SF (2017):** Computed tomography enterography and magnetic resonance enterography in small intestine of Crohn's disease *Journal of Coloproctology*, 37(3): 251-254.
- 10) **Pezhouh MK, Cheng E, Weinberg AG, Park JY (2016):** Significance of paneth cells in histologically unremarkable rectal mucosa. *The American journal of surgical pathology*, 40(7): 968-71.
- 11) **del Val JH (2011):** Old-age inflammatory bowel disease onset: a different problem?. *World journal of gastroenterology: WJG.*, 17(22):2734.
- 12) **Laghi A, Paolantonio P, Iafrate F et al. (2002):** Oral contrast agents for magnetic resonance imaging of the bowel, *Top Magn Reson Imaging*, 13: 389–396.