

Role of Diffusion Weighted MRI in Grading of Endometrial Carcinoma

Lobna A. Habib, Nourhan A. Gaber, Rasha S. Hussein

Radiology Department, Faculty of Medicine, Ain Shams University, Cairo, Egypt

Corresponding author: Nourhan A. Gaber, Mobile: +201150189304, E-mail: dr.nourhangaber@gmail.com

ABSTRACT

Background: Recent developments in diagnostic imaging techniques have magnified the role and potential of MRI in female pelvic imaging. Functional imaging by means of diffusion weighted magnetic resonance imaging (DW-MRI) is now part of the standard imaging protocols for evaluation of the female pelvis.

Objective: This study aimed to highlight the role of Diffusion Weighted MRI in tumor grading noninvasively prior to surgery.

Methodology: This study carried out in Radiology Department of Ain Shams University Hospitals. This study included 20 patients. All patients were subjected to careful history taking, Histologic diagnosis of endometrial carcinoma and pelvic MRI was done.

Result: The difference between the mean ADC values of high grade and low grade endometrial carcinoma was significant.

Conclusion: MRI is accurate in assessing the depth of myometrial invasion and cervical extension, allowing for selective lymphadenectomy, with higher accuracy measures for Diffusion Weighted MRI than for Dynamic Contrast Enhanced MRI in both lesion characterization and staging.

Keywords: Endometrial carcinoma, DW MRI.

INTRODUCTION

Endometrial carcinoma is the leading malignant tumor of the female genital tract in industrialized countries. Over the last decade the annual incidence has remained stable with an estimated 25.1 cases per 100,000 women⁽¹⁾.

The vast majority of endometrial cancer is diagnosed at an early stage with atypical uterine bleeding in postmenopausal age. The 5-year overall survival is 81.7%, but it varies broadly from 20 to 91% for different tumor histologies and stages⁽²⁾.

Advances in magnetic resonance imaging (MRI) technology provide excellent soft tissue contrast resolution with multiplanar capabilities when evaluating the female pelvis⁽³⁾.

There has been a growing interest in functional imaging modalities. Diffusion-weighted imaging (DWI) with the aid of quantitative apparent diffusion coefficient (ADC) measurement is a unique, noninvasive modality that was shown to improve the radiological diagnosis of malignant tumors⁽⁴⁾.

Diffusion weighted MR imaging is a functional imaging technique that displays information about water mobility, tissue cellularity, and the integrity of the cell membranes. It carries the potential to improve tissue characterization when findings are interpreted together with conventional MR imaging sequences⁽⁵⁾.

High grade endometrial carcinomas have high cellular density and are expected to have lower ADC values compared to low grade ones. Thus, the expected clinical significance of ADC measurement in endometrial cancer would be in

predicting tumor grade noninvasively prior to surgery⁽⁶⁾.

Diffusion weighted -MRI may help to differentiate endometrial cancer from normal endometrium, however this has limited clinical utility at the diagnosis of endometrial cancer which is made by endometrial biopsy and the role of contrast enhanced MRI is to stage a known endometrial carcinoma⁽⁷⁾.

AIM OF THE WORK

The aim of this study was to highlight the role of DW-MRI in tumor grading noninvasively prior to surgery.

PATIENTS AND METHODS

Patients: The study was conducted in the period between October 2017 and May 2018 in Radiology Department at Ain Shams University Hospitals. The patients underwent MR examination using a 1.5 T machine (Achieva, Philips medical system, Eindhoven, Netherlands) using phased array coil.

Inclusion criteria: Patients presented with a histologic diagnosis of endometrial carcinoma.

Exclusion criteria: Patients known to have contraindications for MRI, e.g. an implanted magnetizable device, pacemakers or claustrophobia and patients having allergy to contrast.

Ethical Considerations: All participants signed an informed consent after explaining to them the objective of the study. The study was approved by the Ethics Board of Ain Shams University.

MR-imaging protocol: Localizer images in both axial and sagittal planes: 1- Sagittal T2WI. 2- Axial oblique T2WI. 3- Coronal oblique T2WI.

4- Axial T1WI. 5- Post contrast fat suppressed images: sagittal, coronal oblique & axial oblique.

Diffusion study: Axial oblique DWI was performed. Data acquisition was obtained by applying three different b factors of 0, 500, and 1000 s/mm². DW images were utilized for calculation of the ADC values. ADC measurements were automatically calculated by drawing the largest possible region of interest (ROI) with focus on the solid component of the uterine carcinomas. ADC value was usually expressed in ($\times 10^{-3}$) square millimeters per second.

Imaging evaluation: MR images analysed for following parameters: Thickness of the endometrium. Tumor signal intensity on T2-weighted image compared with that of adjacent myometrium. Myometrial invasion. Uterine enhancement pattern at dynamic images. Downward extension. Extra uterine extension and distant metastasis. Lymph node assessment. Signal loss at DWI. ADC (Apparent Diffusion Coefficient) value is lower in carcinoma than normal endometrium and polyps. Densely cellular tissue or those with cellular swelling exhibits low (ADC) and this is particular in tumor characterization. In this study we used a cut off ADC value $1.2 \times 10^{-3} \text{mm}^2/\text{s}$. to distinguish endometrial carcinoma from benign lesions. In Dynamic Contrast Enhanced-MRI, imaging was acquired at 0,30,60,90 and 120 seconds postcontrast.

ADC calculation: -The mean ADC was measured by drawing a region of interest (ROI) over the lesion. The ADC was measured twice and the two measurements were averaged. To ensure that the same areas were measured. ROI was copied and pasted from DW images to ADC map.

Statistical Analysis: The collected data were revised, coded, tabulated and introduced to a PC using Statistical package for Social Science (SPSS 15.0.1 for windows; SPSS Inc, Chicago, IL). Data were presented as mean and standard deviation (+SD) for quantitative parametric data, and median and Interquartile range for quantitative non parametric data. Frequency and percentage were used for presenting qualitative data. Suitable analysis was done according to the type of data obtained. Student T test or Mann Whitney test were used to analyze quantitative data while chi square test and fisher exact test were used to analyze qualitative data. P-value: level of significance: $P > 0.05$: Non significant (NS). $P < 0.05$: Significant (S). $P < 0.01$: Highly significant (HS).

RESULTS

This study included (20) female patients with pathologically proven endometrial carcinoma. They were sent for confirmation of diagnosis and preoperative staging.

The patients age ranged from (40-78) years old and the mean age was 53.4 ± 7.29 (table 1) and 15 patients (75%) complained of post-menopausal bleeding, while 5 patients (25%) complained of menorrhagia.

Table (1): Age distribution among the study group.

Age (years)	No.	%
≤ 50 years	8	40.0
> 50 years	12	60.0
Total	20	100.0
Range [Mean \pm SD]	40-78 [53.4 \pm 7.29]	

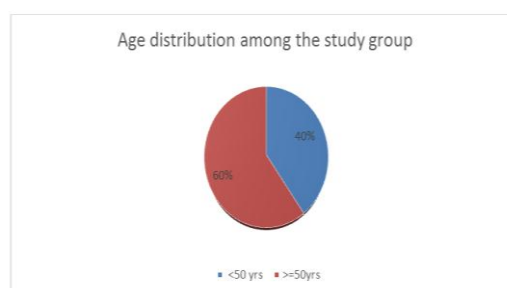


Fig. (1): Age distribution among the study group.

Table (2): Grade of tumor distribution among the endometrial carcinoma cases.

Grade of tumor	Number	%
Grade 1 endometrioid adenocarcinoma (well differentiated)	8	40%
Grade 2 endometrioid adenocarcinoma (moderately differentiated)	5	25%
High grade (Grade 3 endometrioid adenocarcinoma and non endometrioid endometrial carcinoma (poorly or undifferentiated))		35%
Total	20	100%

Grade 1 endometrioid adenocarcinoma (well differentiated) was seen in (8/20, 40%) cases by histopathology.

Grade 2 endometrioid adenocarcinoma (moderately differentiated) was the grade of tumor in (5/20, 25%) of cases.

High grade (grade 3 endometrioid adenocarcinoma and non endometrioid endometrial carcinoma) in (7/20, 35%) of cases.

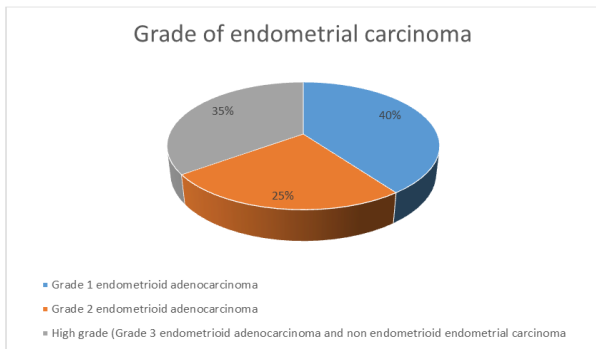


Fig. (2): Grade of tumor distribution among the endometrial carcinoma cases.

Table (3): Correlation between histological grade of endometrial carcinoma and the ADC value of each grade.

Grade of tumor	Mean ±SD
Grade 1 (well differentiated)	0.78±0.09
Grade 2 (moderately differentiated)	0.77±0.12
Grade 3 and undifferentiated	0.75±0.10

Correlation of the ADC values with the different histological grades was done. The mean ADC values were $0.78 \pm 0.09 \times 10^{-3} \text{mm}^2/\text{s}$ for grade 1 (G1), $0.77 \pm 0.12 \times 10^{-3} \text{mm}^2/\text{s}$ for grade 2 (G2), and $0.75 \pm 0.10 \times 10^{-3} \text{mm}^2/\text{s}$ for grade 3 (G3) and undifferentiated endometrial carcinoma. There was significant difference between grades (1 and 2) from grade 3. i.e.: there was significant difference ($P = 0.03$) between well differentiated & poor differentiated tumors.

Table (4): Overall Accuracy measures of DWI-MRI in grading of endometrial carcinoma in relation to histopathology.

Overall Accuracy measures of DWI-MRI in grading of endometrial carcinoma	%
Sensitivity	90.6%
Specificity	87.5%
Accuracy	90.0%

The overall (sensitivity, specificity and accuracy) of DWI-MRI in grading of endometrial carcinoma were 90.6%, 87.5% and 90.0% respectively.

DISCUSSION

The endometrial cancer patient’s prognosis depends mainly on histologic grade, tumor stage including the depth of myometrial invasion, and lymph node involvement⁽⁶⁾.

Preoperative knowledge is a critical step for treatment planning, and tailoring the surgical approach⁽⁷⁾.

This study was conducted at the Radiology Department in Ain Shams University hospitals in 2018. Our aim was to detect the impact and sensitivity of Diffusion Weighted MRI in preoperative grading of endometrial carcinoma, with histopathological diagnosis taken as a reference.

The study included 20 females with pathologically proven endometrial carcinoma. Their age ranged from 40-78 years. 8(40%) were <50 years and 12 (60%) were > 50 years with mean age 53.4 years.

Endometrial cancer is the fourth most common malignancy in females. The endometrial cancer prevalence is increasing due to an aging population combined with rising levels of obesity; 75% of cases occur in postmenopausal women, with the median age at diagnosis being 70 years old. Adenocarcinomas account for 90% of endometrial neoplasm⁽⁸⁾.

In the current study, the clinical presentation in 15 patients (75%) was postmenopausal bleeding, while 5 patients (25%) complained of menorrhagia.

In *Todo et al.*⁽⁹⁾ study, more than 90% of the study group were found to have endometrioid adenocarcinoma. Of these, 52% were grade 1 tumours, 25% were grade 2 tumours and 15% were grade 3 tumours. The remaining 8% were associated with poor prognosis and included clear cell carcinoma and serous adenocarcinoma.

In our study, 90% were found to have endometrioid adenocarcinoma and 10% had serous adenocarcinoma. Of these cases, 40% were grade (1), 25% were grade (2) and 35% were grade (3) and (serous adenocarcinoma) high grade tumour.

DWI is a recent technique that reflects the changes in microscopic mobility of water molecules⁽¹⁰⁾.

It might allow distinguishing cancerous from normal tissues. A tissue with high cellular density - such as neoplastic tissue - shows high signal on DWI, while tissue with lower cellular density - normal tissue - shows lower signal intensity on DWI⁽¹¹⁾.

In our study, b 0, b 500, and b 1000 DW images were obtained. We used the b 1000 image in our interpretation.

Many studies used b value of 800 such as *Taufiq et al.*⁽¹²⁾. Other studies used b 1000 DW image^(13,7,14). According to *Andreano et al.*⁽⁶⁾. Meta-analysis this difference in b values did not seem to affect the final results.

ADC maps enabled obtaining quantitative information. The ADC values of malignant tumors were lower than those of normal tissue or benign lesions in several anatomic districts⁽¹⁵⁾.

Mohammad et al.⁽¹⁶⁾ showed the role of DW-MRI in the diagnosis of malignant uterine tumors; 20 cases with suspected gynecological lesions and 10 of them pathologically proven endometrial carcinoma were included. The Mean ADC of this study was $(0.78 \pm 0.22 \times 10^{-3} \text{mm}^2/\text{s})$.

In *Shen et al.*⁽¹⁷⁾ study, the mean ADC of endometrial carcinoma of 24 cases was $(0.864 \times 10^{-3} \text{mm}^2/\text{s})$.

Dogan et al.⁽¹⁸⁾ showed higher mean ADC of endometrial cancer $1.02 \pm 0.48 \times 10^{-3} \text{mm}^2/\text{s}$.

In our study, all cases of endometrial cancer demonstrated high signal intensity on DW images and low signal intensity on ADC maps. The mean ADC for endometrial cancer was $0.77 \pm 0.01 \times 10^{-3} \text{mm}^2/\text{s}$. In line with *Kierans et al.*⁽¹⁹⁾ who reported $0.77 \pm 0.12 \times 10^{-3} \text{mm}^2/\text{s}$ as mean ADC value of endometrial cancer.

Bharwani et al.⁽²⁰⁾ study, 42 cases of endometrial lesions including 23 malignant and 19 benign lesions, the cut-off ADC value of his study was $(1.28 \times 10^{-3} \text{mm}^2/\text{s})$.

Also another study *Kamiyama et al.*⁽²¹⁾, a total of 95 patients were included in this study. Thirty-nine of the females (mean age, 57.6 years; age range, 32-84 years) were pathologically proven to have endometrial cancer, 43 patients with a cut-off ADC value of $(1.2 \times 10^{-3} \text{mm}^2/\text{s})$.

In recent works, no overlap between the ADC values of normal endometrium, myometrium, and endometrial cancer was found⁽¹⁹⁾.

In our study, all cases of endometrial cancer have ADC values $(< 1.2 \times 10^{-3} \text{mm}^2/\text{s})$.

DWI with measurement of mean ADC value is useful in demonstrating the presence of endometrial cancer. However, histological tumor grades could not be distinguished based on the mean or minimum ADC value of the tumor⁽²⁰⁾.

Nakamura et al.⁽²²⁾ reported a significant difference between mean ADC of grade 1 and grade 3 tumors. *Inoue et al.*⁽²³⁾ results suggested that minimum ADC that reflects portions of highest cellularity within the tumor might be useful for predicting endometrial carcinoma grades. However, some authors found no significant difference among different tumor grades⁽²⁴⁾.

In our study, there was significant difference between grades (1 and 2) from grade 3. i.e.: there was significant difference ($P = 0.03$) between well differentiated & poor differentiated tumors.

CONCLUSION

Although TVUS is the first imaging modality that can be used for detection of uterine mass lesion. The final diagnosis of the endometrial carcinoma is based on the histological examination; it is desirable to pre-operatively decide whether surgery is required, and which type of surgery is appropriate.

Thus, MRI could help avoiding unnecessary surgery. It tells us the exact volume, shape, and direction of the primary lesion, local extent of the disease, and nodal status accurately, which helps the clinician in treatment planning.

MRI is an ideal non-invasive technique and superior to other imaging modalities in the evaluation of pelvic abnormalities. The anatomical relation of the visceral organs, the differential zonal anatomy of the corpus uteri and the cyclical endometrial changes during the menstrual cycle are well depicted with MRI.

In addition, lesion characterization is done with the help of MRI. Complementary role of both conventional and functional MRI is necessary in morphological and functional characterization of the lesion.

The purpose of this study was to evaluate the impact of Diffusion Weighted Magnetic resonance imaging in preoperative grading of endometrial carcinoma, with histopathological diagnosis taken as the reference.

MRI had been found to be cost-effective because in addition to its capability of accurate staging, it can replace multiple other radiological and interventional procedures, as computed tomography (CT), cystoscopy, and sigmoidoscopy.

Mean ADC value measurement can provide useful information in differentiating benign from malignant endometrial lesions. This information could be clinically relevant in those patients where preoperative endometrial sampling was not possible.

It helps to decide operability, the type of operation and aids in the selection of patients who need a special referral to a gynecologist oncologist.

The sensitivity, specificity and accuracy of ADC value in grading of endometrial carcinoma in relation to histopathology were 90.6%, 87.5% and 90.0% respectively.

REFERENCES

1. **Siegel RL, Miller KD and Jema A (2015):** Cancer statistics 2015. *CA Cancer J Clin.*, 65:5–29.
2. **Haldorsen LS and Salvesen HB (2012):** Staging of endometrial carcinomas with MRI using traditional and novel techniques. *Clin Radiol.*,67:2–12.
3. **Sala E, Rockall A, Rangarajan D et al. (2010):** The role of dynamic contrast-enhanced and diffusion weighted magnetic resonance imaging in the female pelvis. *E J Radiol.*, 76:367–85.
4. **Rauch GM, Kaur H, Choi H et al. (2014):** Optimization of MR Imaging for pretreatment evaluation of patients with endometrial and cervical cancer. *Radiograph.*,14:1082–98.
5. **Tamai K, Koyama T, Saga T et al. (2007):** Diffusion-weighted MR imaging of uterine endometrial cancer. *Jrnal of magnetic resonance imaging. JMRI.*, 26(3):682-687.
6. **Andreano A, Rechichi G, Reborra P, Sironi S, Valsecchi M. and Galimberti S (2014):** MR diffusion imaging for preoperative staging of myo-metrial invasion in patients with endometrial cancer: a systematic review and meta-analysis.*Eur.Radiol.*,(6):1327–1338.
7. **Rechichi G, Galimberti S, Signorelli M et al. (2011):** Endometrial cancer: correlation of apparent diffusion coefficient with tumor grade, depth of myometrial invasion and presence of lymph node metastases. *AJR.*, 197:256–62.
8. **Rechichi G, Galimberti S, Signorelli M et al. (2010):** Myometrial invasion in endometrial cancer: diagnostic performance of diffusion-weighted MR imaging at 1.5-T. *Eur Radiol.*, 20(3):754-762
9. **Todo Y, Kato H and Kaneuchi M (2010)** Survival effect of para-aortic lymphadenectomy in endometrial cancer. *The lancet*, 375(9721):1165-1172.
10. **Lewinski M, Mack S, Hulse P et al. (2012):** MRI Manual of Pelvic Cancer. New York, NY: Informa.,243(15): 77–96.
11. **Chen S, Chiou Y, Wang J et al. (2008):** Diffusion-weighted single-shot echo-planar imaging with parallel technique in assessment of endometrial cancer. *A.J.R. Am. J. Roentgenol.*,190: 481-8.
12. **Taufiq M, Mansoor I and Hussain Z (2016):** Diagnostic accuracy of diffusion weighted magnetic resonance imaging in the detection of myometrial invasion in endometrial carcinoma. *J Coll Physicians Surg Pak.*, 26(1):13-7.
13. **Hori M, Kim T and Onishi H (2013):** Endometrial cancer: preoperative staging using three-dimensional T2-weighted turbo spin-echo and diffusion-weighted MR imaging at 3.0T:a prospective comparative study.*Eur. Radiol.*,23:2296–305.
14. **Beddy P, Moyle P, Kataoka M et al. (2012):** Evaluation of depth of myometrial invasion and overall staging in endometrial cancer: comparison of diffusion-weighted and dynamic contrast-enhanced MR imaging. *Radiology*, 262(2):530-537.
15. **Koplay M, Dogan N, Erdogan H et al. (2014):** Diagnostic efficacy of diffusion-weighted MRI for preoperative assessment of myometrial and cervical invasion and pelvic lymph node metastasis in endometrial carcinoma. *J Med Imag Radiat Oncol.*,61:45–52.
16. **Mohammad K, Hazem A,Mostafa A et al. (2015):** Role of MRI Diffusion Weighted Imaging in the Diagnosis of Malignant Uterine Tumors, *Med. J. Cairo Univ.*,83(2): 159-167.
17. **Shen S, Chiou Y, Wang J et al. (2008):** Diffusion-weighted single-shot echo-planar imaging with parallel technique in assessment of endometrial cancer. *A.J.R. Am. J. Roentgenol.*,190: 481-8.
18. **Dogan D, Inan N, Sarisoy H et al. (2013):** Preoperative evaluation of myometrial invasion in endometrial carcinoma: diagnostic performance of 3T MRI. *Abdom.Image*, 38:388–96.
19. **Kierans A, Bennett G, Haghghi M and Rosenkrantz A (2014):** Utility of conventional and diffusion-weighted MRI features in distinguishing benign from malignant endometrial lesions. *Euro J. Radiol.*, 83:726–32.
20. **Bharwani N, Miquel E, Sahdev A et al. (2011):** Diffusion-weighted imaging in the assessment of tumour grade in endometrial cancer.*The British Journal of Radiology*,84: 997–1004.

- 21. Kamiyama T, Fukukura Y, Takumi K *et al.* (2010):** Diffusion-weighted imaging of uterine endometrial cancer using the apparent diffusion coefficient value at 3.0 T MRI: Differentiation endometrial cancer from normal endometrium and endometrial benign lesions, *Proc. Intl. Soc. Mag. Reson. Med.*,18: 4761.
- 22. Nakamura K, Imafuku N and Nishida T (2012):** Measurement of the minimum apparent diffusion coefficient (ADC min) of the primary tumor and CA125 are predictive of disease recurrence for patients with endometrial cancer. *Gynecol Oncol.*,1 24:335–9.
- 23. Inoue C, Fujii S, Kaneda S *et al.* (2013):** Correlation of apparent diffusion coefficient value with prognostic parameters of endometrioid carcinoma. *J. Magn Reson Imag.*, 39:1–7.
- 24. Beddy P, O'Neill C, Yamamoto K *et al.* (2012):** FIGO staging system for endometrial cancer: added benefits of MR imaging. *Radiographics*, 32(1):241-54.