

Multiparametric Magnetic Resonance Imaging in Assessing Ovarian Cysts

Arwa T.M. Ali, Rasha S.E. Hussein, Sherine G. Moftah

Radiology Department, Faculty of Medicine, Ain Shams University, Cairo, Egypt

Corresponding author: Arwa T.M. Ali, Mobile: +201003505714, E-mail address: doctor.arwa@hotmail.com

ABSTRACT

Objective: Is to study the role of multi-parametric MRI including the novel sequences, diffusion weighted images (DWI) in the characterization of ovarian cystic lesions.

Methodology: This study carried out in MRI unit, Radiology Department of Ain Shams University Hospitals. 20 patients with pathologically proven nature of ovarian cyst underwent pelvic MRI examination including diffusion weighted imaging (DWI) and apparent diffusion coefficient (ADC)

Result: Diffusion weighted imaging (DWI) and apparent diffusion coefficient (ADC) to detect nature of ovarian cysts can't be carried alone but need to be combined by conventional and DCE MRI.

Keywords: Multi-parametric MRI (Mp-MRI), Adnexal, Ovarian, Cysts, Apparent diffusion coefficient (ADC)

INTRODUCTION

Ovarian cancer remains the leading cause of death amongst gynecological malignancies. The degree of suspicion for malignancy in a given ovarian cystic lesion is largely based on diagnostic imaging⁽¹⁾.

Differentiating a benign from a malignant adnexal cystic lesion would provide a base for optimal preoperative planning and may also reduce the number of unnecessary laparotomies patients undergoing treatment for benign disease⁽²⁾.

MRI provides additional information on the composition of cystic lesions using differences in MR relaxation properties seen in various types of tissue. More recently developed MRI sequences, like diffusion weighted, susceptibility weighted, and dynamic contrast enhancement sequences provided additional capacities for adnexal lesion tissue characterization⁽³⁾.

It was reported that Mp-MRI limits additional expense and invasive diagnostic and surgical applications and has advantages in terms of cost-effectiveness contrary to general belief⁽⁴⁾.

Diffusion-weighted imaging (DWI) has some utility for characterization of adnexal cystic lesions, and is especially useful in the detection of metastases and peritoneal implants⁽⁵⁾.

Fibrous lesions with very low ADC values usually also show low signal on DWI, suggesting benignity. Further, lesions with benign features on both ADC maps and DWI are most often benign, and demonstration of low DWI signal within a mass may augment diagnostic confidence when features on other sequences favor a benign process⁽⁵⁾.

Quantitative dynamic contrast enhanced MRI (DCE-MRI) provides an accurate method for the prediction of malignancy, particularly in preoperative indeterminate cases⁽²⁾. The early enhancement patterns of ovarian epithelial tumors on DCE-MR images can help distinguish between benign, borderline, and invasive epithelial tumors⁽⁶⁾.

AIM OF THE WORK

The objective of this study is to study the role of multiparametric magnetic resonance imaging (Mp-MRI) including the novel sequences, namely diffusion weighted images (DWI) in the characterization of ovarian cystic lesions.

PATIENTS AND METHODS

Patients: During a period of 6 months duration from December 2017, twenty patients were enrolled in the study. All patients with sonographically detected ovarian cystic lesion where histopathological report of the nature of cyst or strict follow up was done. MRI examination was done prior to any intervention. **The study was approved by the Ethics Board of Ain Shams University.**

Inclusion criteria: Female patients with sonographic findings of ovarian cysts. No age predilection.

Exclusion criteria: Patients known to have contraindications for MRI, e.g. an implanted magnetic device, pacemakers or claustrophobia. Patients with bad general condition needing life support and those with severe hepato-renal disease. Purely solid ovarian masses. Histopathological Analysis The histology was reviewed by an experienced pathologist.

MRI imaging: Conventional MRI and DWIs were performed using PHILIPS Achieva 1.5 Tesla, Netherlands, using a torso XL 16 channels phased array coil.

Diffusion study: DW images were acquired in the axial plane using the single-shot echo-planar imaging technique. Diffusion-encoding gradients were applied using three b values of 0,600 and 800 s/mm² along the three orthogonal directions of motion-probing gradients. ADC maps were automatically constructed on a pixel by-pixel basis.

MRI data analysis: When the ROI was drawn, attention was paid to the exclusion of the

areas of necrosis and cystic regions to minimize any error in the calculation of the mean ADC and semi-quantitative dynamic parameters.

Statistical analysis: Data were analyzed using Statistical Program for Social Science (SPSS) version 17 (SPSS Inc., Chicago, IL, USA). Quantitative data were expressed as range, mean± standard deviation (SD). Qualitative data were expressed as number and percentage.

The following tests were done: Student t-test was applied to compare parametric quantitative variables between two groups. Fisher’s exact test of significance was used in order to compare proportions between two qualitative parameters.

RESULTS

The 20 patients enrolled in this study were ranging from 18-64 years with mean age of 42.4 with SD +/- 15 years. There was statistically non-significant difference between the mean age of proven benign (44.6 with SD +/- 6 years) and that of malignant lesions (37.3 with SD +/- 5 years) with P-value of 0.28.

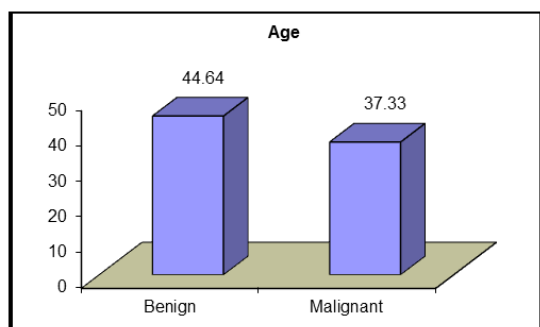


Figure (1): Demonstrating the mean age in the cases with benign and malignant ovarian cyst

Regarding the histopathological type of the diagnosed ovarian cysts, 14 women (70%) had benign lesions, while 6 women (30%) had malignant lesions.

Conventional MR features revealed 11 cases are likely to be benign (55%) and 9 cases are likely to be malignant (45%).

From the 20 studied cystic lesions, 4 lesions (20%) showed no DWI restriction, while 9 lesions (45%) of them showed low DWI restriction and 7 lesions (35%) showed high DWI restriction.

As regard the mean ADC value median was $0.8 \times 10^{-3} \text{ mm}^2/\text{s}$, with range, 0.24 – 2.89.

6 cases (30%) were provisionally benign on the other hand 14 cases (70 %) were provisionally malignant.

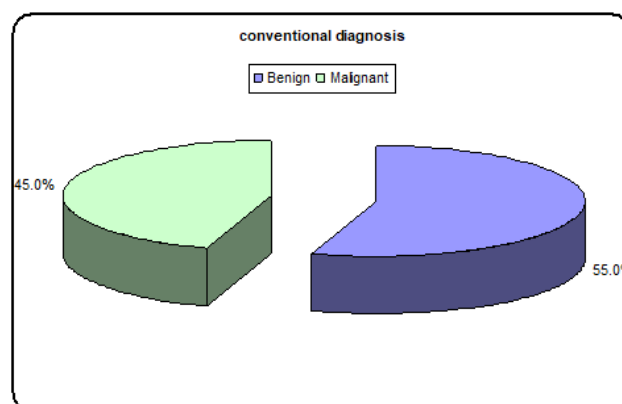


Figure (2): Pie chart demonstrating percentage of conventional MR features in T2WI in characterizing the nature of ovarian cyst

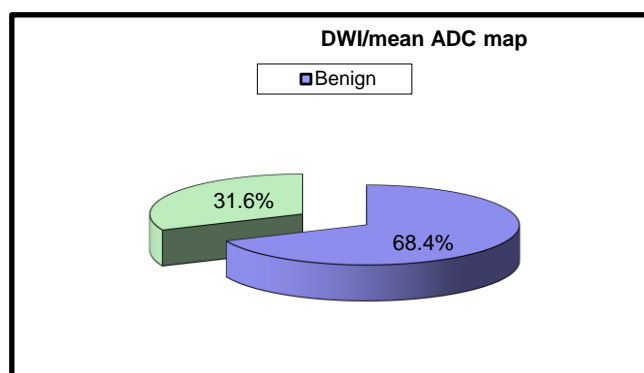


Figure (3): Pie chart demonstrating percentage DWI/mean ADC map in determining the nature of ovarian cyst.

Statistically highly significant correlation was obtained regarding the presence of solid component in the lesion. The rest of the morphologic parameters as number of locules, septa or wall thickness together with the conventional MR features in T1, T2 WIs and fat saturation signals were statistically non-significantly correlated in the studied cases.

The conventional MR features showed statistically highly significant correlation in cystic ovarian lesion characterization.

The degree of diffusion restriction in the studied cystic ovarian lesions as well as the mean ADC value are shown to have statistically non-significant correlation.

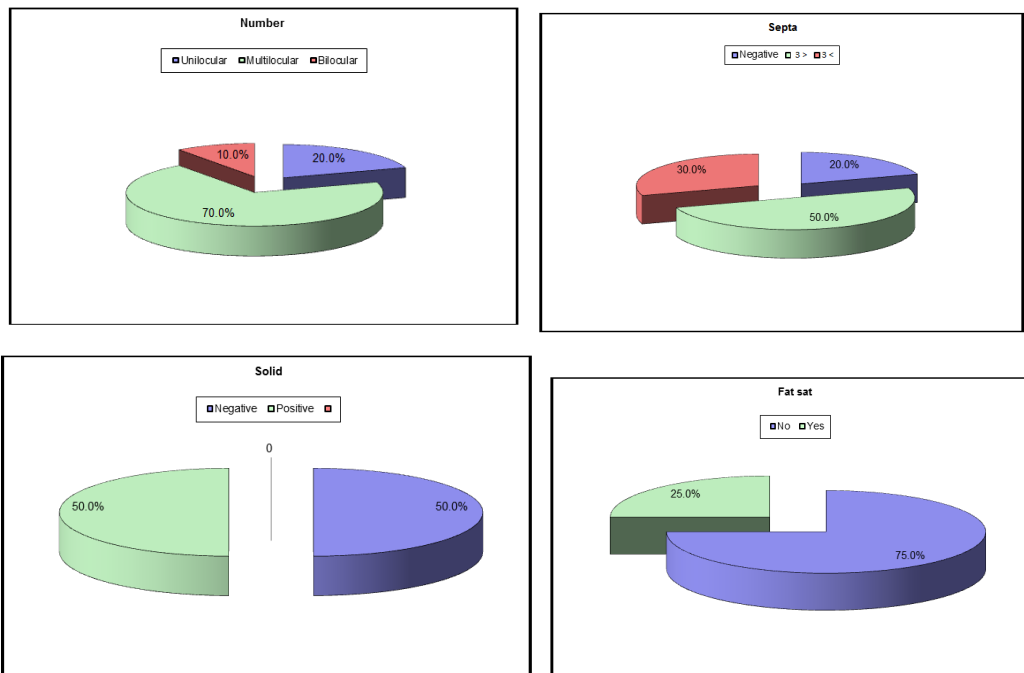
Table (1): Comparison between proven benign and malignant cystic ovarian lesions regarding the conventional MR features of the studied lesions

		Pathologically proven diagnosis				Test value*	P-value	Sig.
		Benign		Malignant				
		No.	%	No.	%			
Number of locules	Unilocular	4	28.6%	0	0.0%	3.673	0.159	NS
	Multilocular	8	57.1%	6	100.0%			
	Bilocular	2	14.3%	0	0.0%			
Septa/wall thickness (mm)	Negative	3	21.4%	1	16.7%	1.667	0.435	NS
	< 3	8	57.1%	2	33.3%			
	> 3	3	21.4%	3	50.0%			
Solid component	Negative	10	71.4%	0	0.0%	8.571	0.003	HS
	Positive	4	28.6%	6	100.0%			
T1 WI SI	Low	5	35.7%	5	83.3%	4.127	0.248	NS
	Intermediate	5	35.7%	1	16.7%			
	High	3	21.4%	0	0.0%			
	Mixed	1	7.1%	0	0.0%			
T2 WI SI	Low	0	0.0%	1	16.7%	6.243	0.100	NS
	Intermediate	8	57.1%	1	16.7%			
	High	6	42.9%	3	50.0%			
	Mixed	0	0.0%	1	16.7%			
Fat saturation	No	9	64.3%	6	100.0%	2.857	0.091	NS
	Yes	5	35.7%	0	0.0%			
Conventional MR features provisional diagnosis	Benign	11	78.6%	0	0.0%	10.476	0.001	HS
	Malignant	3	21.4%	6	100.0%			

NS: Non significant; HS: Highly significant *:Chi-square test

The conventional MR features showed statistically highly significant correlation in cystic ovarian lesion characterization.

The following 7 figures illustrates the different conventional parameters as follows:



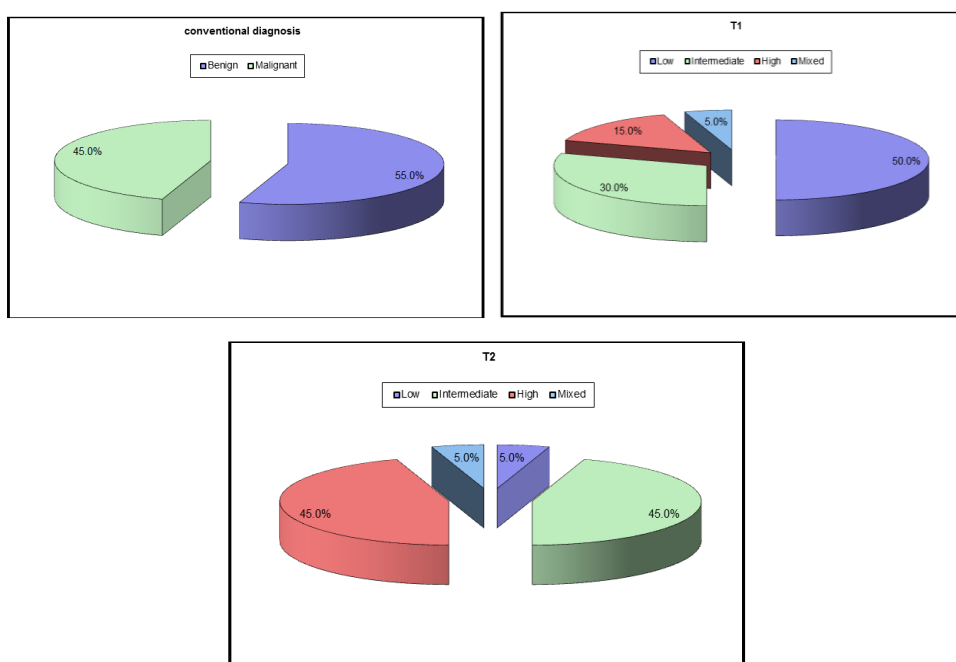


Table (4): Diagnostic accuracy tools of conventional MR features, DWI and mean ADC value and dynamic contrast enhanced MRI in prediction of nature of the cystic ovarian lesion.

Parameter	Accuracy	Sensitivity	Specificity	PPV	NPV	PLR
Conventional MRI features	85.0%	100.0%	78.6%	66.7%	100.0%	4.67
DWI/mean ADC	50.0%	83.3%	35.7%	35.7%	83.3%	1.3

In the 20 studied cases of cystic ovarian lesions the accuracy of the conventional MR features was 85%, 50 % in DWI/mean ADC value

The conventional MR features showed 100% sensitivity, 78.6% specificity with 66.7% positive predictive value (PPV) and 100% negative predictive value (NPV) with positive likelihood ratio (PLR) of 4.67.

The DWI/mean ADC value showed 83.3 % sensitivity, 35.7% specificity with 35.7 % positive predictive value, 83.3 % negative predictive value and with positive likelihood ratio of 1.3.

DISCUSSION

Mp-MR imaging is used to characterize adnexal lesion seen on ultrasound, with an overall diagnostic accuracy of MR for borderline or invasive tumors versus benign ovarian lesions ⁽⁷⁾.

Diffusion-weighted imaging exploits the random motion of water molecules, because water movement in highly packed cells is restricted ⁽⁸⁾.

Twenty cases of cystic ovarian lesions were studied where 14 of them showed benign lesions while 6 cases has pathologically malignant lesions.

Mean age of the studied benign cases was 44.6 years while the mean age among the studied malignant cases was 37.3 years that showed statistically non-significant value (P-value 0.28). However, these observations were not concordant to *Wills & Mathew* ⁽⁹⁾ where benign tumors were found in the reproductive age group (20-40 years) as well as in the perimenopausal group (41-60 years) also most of the malignant ovarian lesions were in the older group (41-70 years). This may be attributed to the small sample size in our study.

Conventional MR features revealed 11 cases are likely to be benign (55%) and 9 cases are likely to be malignant (45%).

Statistically highly significant value between the benign and malignant groups (P- value 0.003) was obtained in our study regarding the presence of solid component in the lesion, which is also stated by *Jarwani et al.* ⁽¹⁰⁾. In contrary, *Sohaib et al.* ⁽¹¹⁾ confirmed that some non-epithelial benign lesions with some solid enhancing elements may be incorrectly classified as malignant.

Regarding the DWI and mean ADC value *Fujii et al.* ⁽¹²⁾ and *Bakir et al.* ⁽¹³⁾ agreed to our study regarding DWI and ADC values because they reported: DWI and ADC value did not differ significantly between benign and malignant lesions with many overlaps between ADC values of both categories (P-value 0.39).

This overlap which was explained by *Hassen et al.* ⁽¹⁴⁾ is due to increased mean ADC values in the malignant lesions and the decreased ADC values in benign lesions as the desmoplastic reaction in stroma may cause increased mean ADC values in malignant tumors. *Nakayama et al.* ⁽¹⁵⁾ also attributed the wide variation in the ADC values to the lesion morphological heterogeneity.

CONCLUSION

Mp-MRI represents a useful method that offers high accuracy in determination the origin and nature of ovarian cysts.

In order to differentiate benign from malignant masses, our study concluded that conventional MR in adjunct to DWI are helpful in differentiation between benign and malignant ovarian lesions, but dynamic contrast enhanced MRI cannot be replaced as it helps in the assessment of vascularity, nature and integrity of the lesions.

Our recommendations for complex cysts are that DWI and DCE MRI be used.

ILLUSTRATIVE CASE

22 year old female patient, presenting with pelvic pain of 5 months duration, increased 1 week ago.

PAUS revealed large right adnexal complex cystic lesion, measuring 5x 6 cm with internal echoes with left adnexal small cysts.

Pelvic MRI reveals:

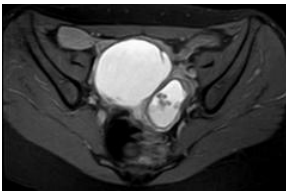


Figure (4): Axial T2WI

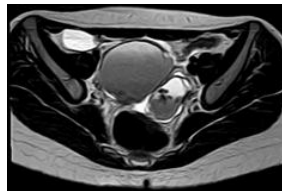


Figure (5): Axial T1WI

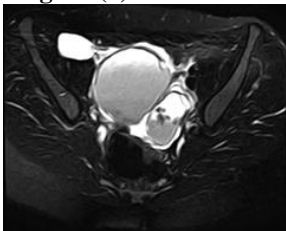


Figure (6): Axial T2WI FS

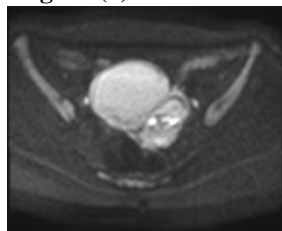

Figure (7): Axial DWI

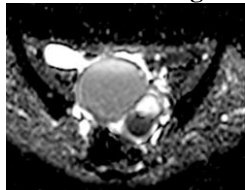

Figure (8): Axial ADC map

Conventional MR description (Fig 4-6):

Right adnexal cystic lesion, displaying high SI in T1WI, low SI in T2 WI (T2 shading) with no suppression of SI in T1 fat suppression sequence denoting hemorrhagic nature of content.

Similar lesion in the left ovary displaying few floating dark spot SI in all sequences denoting old blood component (dark spots).

DWI images (Fig 7-8):

Variable degree of diffusion restriction is noted in different hemorrhagic lesions with corresponding variable ADC values from 0.7 to 1.2 x10-3mm²/sec with mean ADC 0.95 x10-3mm²/sec.

MRI diagnosis (conventional sequences, DWI): Bilateral ovarian benign lesions (endometriomas).

PATHOLOGY: Endometriotic cyst.

REFERENCES

1. **Ginsburg O, Bray F, Coleman MP *et al.* (2017):** The global burden of women's cancers: a grand challenge in global health. *The Lancet*, 389(10071):847-60.
2. **Dogheima OY, Abdel Hamid M, Barakak MS *et al.* (2014):** Role of novel magnetic resonance imaging sequences in characterization of ovarian masses. *The Egyptian Journal of Radiology and Nuclear Medicine*, 1(45): 237-51.
3. **Forstner R, Thomassin-Naggara I, Cunha TM *et al.* (2017):** ESUR recommendations for MR imaging of the sonographically indeterminate adnexal mass: an update. *European radiology*, 27(6):2248-57.
4. **Nougaret S, Vargas HA, Horta M *et al.* (2015):** Ovarian Cancer from Anatomy to Functional Imaging. *Current Radiology Reports*, 3(11):43-8.
5. **Stein EB, Wasnik AP, Sciallis AP *et al.* (2017):** MR Imaging–Pathologic Correlation in Ovarian Cancer. *Magnetic Resonance Imaging Clinics*, 25(3):545-62.
6. **Kurata Y, Kido A, Moribata Y *et al.* (2017):** Diagnostic performance of MR imaging findings and quantitative values in the differentiation of seromucinous borderline tumour from endometriosis-related malignant ovarian tumour. *European radiology*, 27(4):1695-703.

7. **Medeiros L, Freitas L, Rosa D *et al.* (2011):** Accuracy of magnetic resonance imaging in ovarian tumor: a systematic quantitative review. *American journal of obstetrics and gynecology*, 204(1):67-81.
8. **Qayyum A (2009):** Diffusion-weighted imaging in the abdomen and pelvis: concepts and applications. *Radiographics*, 29(6): 1797–810.
9. **Wills V and Mathew R (2016):** A study on clinico- histopathological patterns of ovarian tumors. *Int J Reprod Contracept Obstet Gynecol.*, 5(8):2666-71.
10. **Jarwani P, Babaria S, Suri S *et al.* (2018):** Analysis of distribution and patterns of ovarian lesions at a tertiary care hospital. *Annals of Pathology and Laboratory Medicine*, 5(2):177-83.
11. **Sohaib S, Sahdev A, Trappen PV *et al.* (2003):** Characterization of adnexal mass lesions on MR imaging. *American Journal of Roentgenology*, 180 (5):1297-304.
12. **Fujii S, Kakite S, Nishihara K *et al.* (2008):** Diagnostic accuracy of diffusion-weighted imaging in differentiating benign from malignant ovarian lesions. *J Magn Reson Imaging*, 28(5):1149–56.
13. **Bakir B, Bakan S, Tunaci M *et al.* (2011):** Diffusion-weighted imaging of solid or predominantly solid gynaecological adnexal masses: is it useful in the differential diagnosis? *The British journal of radiology*, 84(1003):600-11.
14. **Hassen K, Ghossain M, Rousset P *et al.* (2012):** Characterization of papillary projections in benign versus borderline and malignant ovarian masses on conventional and color doppler ultrasound. *Am J Roentgenol.*, 196(6):1444–9.
15. **Nakayama T, Yoshimitsu K, Irie H *et al.* (2005):** Diffusion-weighted echo-planar MR imaging and ADC mapping in the differential diagnosis of ovarian cystic masses: usefulness of detecting keratinoid substances in mature cystic teratomas. *J Magn Reson Imaging*, 22: 271- 8.