

Stents Technique for Endovascular Management of Intracranial Aneurysms

Abdulkafy Sharafeldin, Mohammad Hasan, Magdy El-Hawwary, Ahmed El-Shrif,
Mohammed El-Shandawily, Mohammad Al-Bialy

Department of Neurosurgery, Al-Azhar University

Corresponding author: Mohammad Al-Bialy, mohammadelbialy@gmail.com

ABSTRACT

Background: Endovascular detachable coil embolization has become an important method in the management of intracranial aneurysms. However, coil embolization alone may fail to treat some wide-neck aneurysms and other complex anatomy configuration. Herein, we report our experience with and outcome of stent techniques of intracranial aneurysms. **Objective:** The aim of the study was to evaluate the feasibility safety and efficacy of stent usages either conventional or flow diverting stents in endovascular management of intracranial aneurysms. **Patients and Methods:** Between October 2011 to May 2018 a prospective study was done on a series of 17 consecutive patients harboring 17 intracranial aneurysms approached with endovascular therapeutic stent techniques, these 17 aneurysms (5 have history of rupture, 29 % and 12 unruptured, 71%), Angiographic and clinical follow-up was obtained in 17 (100%) patients (mean 21 months, range 0.5 to 84). **Results:** In late follow-up 16 patient (94%) had favorable outcome and 1 patient (6%) had unfavorable outcome, over all Complete occlusion Grade 0 with stent technique was achieved in 10 patients (59%), Grade I in 3 patients (17%), Grade II in 1 patients (6%), Grade III in 1 patient (6%), Grade IV in 1 patient (6%) and Grade V in 1 patient (6%), intraoperative complication was noted in 3 cases (18%) with favorable outcome. **Conclusion:** Endovascular stent-assisted coiling was a feasible, effective and relatively safe technique for the treatment of broad neck and complex configuration intracranial aneurysms. **Key Words:** Intracranial aneurysms, Coiling, endovascular treatment, Intracranial stent, Flow diverter

INTRODUCTION

In early endovascular revolution and technological limitations of endovascular devices, Parent artery preservation, coil herniation and migration, arterial branch occlusion, and higher rates of recanalization have all plagued safe and effective exclusion of wide necked aneurysms (>4 mm neck or dome-to-neck ratio <2) and other geometrically unfavourable anatomy via endovascular means. This make surgical repair the “gold standard” for the treatment of wide-necked cerebral aneurysms⁽¹⁾.

Although use of the balloon remodeling technique⁽²⁾ and use of two- or three dimensional shaped⁽³⁾ and bioactive coils or double-catheter technique⁽⁴⁾ may help to obtain better morphologic results in the treatment of wide-neck aneurysms, insufficient coil packing and/or recurrence is still a major problem⁽³⁻⁵⁾.

Since the advent of the intracranial stent, stent-assisted coil embolization(SACE) of an aneurysm has the capability to facilitate the management of intracranial wide-neck aneurysms to prevent coil protrusion into the parent vessel, which may allow for the safer and denser packing of the aneurysm sac⁽⁵⁻⁷⁾. However, the mid- or long-term effects of SACE of wide neck aneurysms have not been well-evaluated.

The first case of intracranial stenting for treating a brain aneurysm was reported in 1997 by *Higashida et al.* In that occasion, the authors used a balloon expandable cardiac stent in combination

with guglielmi detachable coils to treat a fusiform aneurysm of the vertebrobasilar junction⁽⁸⁾.

The first stent specifically designed for the intracranial area to obtain food and drug administration (FDA) approval was the neuroform TM (boston scientific corporation, natick, usa) in 2002. Outside the USA, especially in Europe the leo™ stent (balt, montmorency, france), the first self-expanding closed cell design stent released in Europe in 2003⁽⁹⁾.

Intracranial stents work as a barrier support the coil mass and enhance dense backing of the aneurysm also serve as scaffolding for neo-endothelization, providing additional reduction of the flow into the aneurysm. Consequently, their use improves intravascular thrombosis and decreases the risk of recanalization⁽⁹⁾.

Although stent-assisted coiling has expanded the treatment possibilities, the technique carries the risk of stent misplacement, thromboembolic events and in-stent stenosis or thrombosis. Furthermore long-term antiplatelet medication is necessary in this subgroup of patients⁽¹⁰⁾.

The aim of the study was to evaluate the feasibility safety and efficacy of stent usages either conventional or flow diverting stents in endovascular management of intracranial aneurysms.

PATIENTS AND METHODS

Patient population: A prospective study was done during the period from October 201 to May 2018 on a series of 17 consecutive patients harboring 17 intracranial aneurysms approached

with endovascular therapeutic stent techniques at Neurosurgery department, Al-Azhar University Hospitals, Cairo. During the period of the study, data were collected and saved in summary sheets case by case. Hospital records and radiology films of the patients were electronically saved. **The study was approved by the Ethics Board of Al-Azhar University.**

Initial clinical status of the patients was assessed according to full clinical history and complete neurological examination. Radiological evaluation was done. CT scan (non enhanced or enhanced or CT angiography) or MRI and MRA, but all patient underwent catheter cerebral angiography for better evaluation of the aneurysm and estimation of the working angles. Initial clinical grading was performed according to GCS and the World Federation of Neurosurgical Societies grade (WFNS). These 17 aneurysms (5 have history of rupture, 29 % and 12 unruptured, 71%) was founded in 10 females (59 %) and 7 (41%) males with age range from 23 to 63 yrs, 7 patient under 40 yrs (41%) and 10 above 40 yrs old (59%).

Medical co-morbidities were found in 5 patients (29%) with 29 aneurysms, all were found hypertensive, no patient was found diabetic.

12 patients (71 %) were found with WFNS grade 0 (intact aneurysm), 5 aneurysms (29%) were in patients with WFNS grade 1.

Procedure: Clopidogrel at a dose of 75 mg/day started and acethyl-salicylic acid (ASA) of 150 mg at least 4 days prior to the procedure. On table 300 mg rapid loading dose of clopidogrel was done for patient with recent history of rupture.

Therapeutic procedures were done under general anesthesia with endotracheal intubation.

Systemic heparinization was used for all therapeutic procedures. An intravenous bolus of 5000 units was initially administered with the introduction of the first embolic device (the first coil or the stent) according to the procedure. Systemic heparinization was maintained by administration of 1000 units of heparin per hour.

Right femoral approach was used. In all cases 6 F sheath system was used and 8 F sheath was used if semi-jailing technique was decided and the two microcatheter was introduced from one sheath.

Type of the materials used in this study was greatly influenced by the availability and experience.

All guiding catheters were connected to a continuous flush system via Y-connector that allows introduction of the interventional devices through the catheter. Flush solution was prepared by adding 1000 U of heparin to a 500 ml bag of normal saline. 10 ml of nimodipine solution (Nimotop™) was added to the first bag.

Types of guiding catheters were used: 1-Envoy TM guide catheter (Cordis; then Codman), 2-Guider (Boston Scientific/ Target), 3-Chaperon (Microvention, Tustin, CA, USA), 4-Fargo (Balt).

Types of guide wire used in this study were as following: 1- Zip wire 150 cm, 0.035 inch (Boston Scientific/ Target). 260 cm wires were used or exchange of diagnostic catheters with guiding catheters, 2- Terumo, 3-Aqwire (ev3, Irvine, CA, USA).

Microcatheters were connected to a flush system in the same manner as mentioned with the guiding catheters. Nimodipine solution was not added here. The following microcatheters were used: 1-Echelon-10 and 14 (ev3), 2-Excel (Boston Scientific/ Target), 3-Excelsior SL 10 (Boston Scientific/ Target), 4-Rebar 18 microcatheter (ev3), 5-headway microcatheter. (Microvention Terumo), 6- XT-26 (Stryker) for the surpass stent, 7-Vasco (Balt) for LEO and SILK stents.

The following wires were used in the study: 1-Transcend-14 (Boston Scientific/ Target), 2-Traxis (Microvention), 3- Synchro, 4-X-pedion (ev3).

The following stents were used: 1-Neuroform (Boston Scientific/ Target), 2-Solitaire (ev3), 3-Pipeline (ev3), 4-Surpass (Stryker), 5-LEO+, LEO baby and silk (Balt), 6- FRED (Microvention).

The following coils were used: 1-GDC-10 and 14 (Boston Scientific/ Target), 2-Axium 3D (ev3), 3-Microplex (Microvention), 4-Helipaque (Micrus Endovascular).

Oral acetyl salicylic acid 150 mg was started in the first postoperative day for all patients. Acetyl salicylic acid was continued for at least one year, clopidogryl 75 mg was also given orally for 3 to 6 months.

The treatment was considered technically feasible if at least one stent could be deployed in optimal place (across the neck of the aneurysm with landing zone of at least 5 mm on each side; otherwise it was categorized as technical failure. Also there were some procedural difficulties changing the original plan to other one.

Clinical outcome assessment: To assess clinical outcome, the Glasgow Outcome Scale (GOS) score was recorded at discharge and at follow-up. Telephone communication was used when considered sufficient.

Radiological outcome assessment: Assessment was done by recording the degree of aneurysm occlusion according to Meyers's classification. Degree of occlusion was recorded in the final control angiography and in angiographic follow up. Stasis was graded according to stasis arm of OKM grading scale.

RESULTS

5 patients have Small aneurysm (29.5%), 4 have Medium size (23.5%), 4 have Large (23.5%) and 4 have Giant (23.5%) aneurysms. 7 patients (41%) have narrow neck while 10 have (59%) wide neck aneurysms. 1 patient (6%) has blister, 11 saccular (64.5%) and 5 nonsaccular (29.5%) aneurysms. 5 aneurysms at the P com, 3 Cavernous, 2 A com, 2 Ophthalmic, 1 A1-A2 junction, 1 MCA, 1 ICA bifurcation, 1 basilar and 1 PCA.

In 13 patients (76.5%) stent technique was the first line of treatment, while in 4 patient (23.5%) was previously embolized with recanalized or remaining part.

18 stents was used, one case have 2 stents(in one session). 1 Surpass, 1 Pipeline, 1 FRED, 1 SILK, 1 SILK and LEO, 3 Neuroform, 3 LEO, 3 Solitaire and 3 LEO baby

Technical feasibility:

Stenting alone was attempted in 8 cases (47%). stenting and coiling was attempted in 9 cases (53%). All stent were deployed in desired position across the neck of the aneurysm. Flow diverter was used in 5 cases (29.5%) and conventional stent in 12 cases (70.5%)

Failure of semi-jailing stent technique was observed in two cases due to complex configuration of aneurysms(p.com blister and A1-A2 acute angle small wide neck aneurysms), failure of stenting and coiling after delayed deployment of one sent (solitaire) with intra-operative MCA stasis in previously coiled aneurysm and marked stasis in the remaining part of the aneurysm, stenting alone and follow of this patient was decided. These 3 cases were not categorized as technical failure.

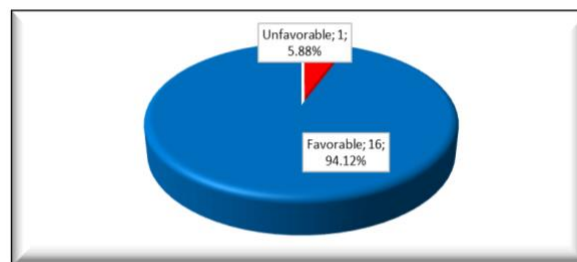


Fig. (1): Percentage of clinical outcome.

Clinical outcome:

In the clinical course of immediate outcome at the end of the procedure all patients, including those with history SAH patients have a favorable outcome with GOS 5 despite intraoperative difficulties and complication.

Clinical follow up duration ranged from 0.75 months to 84 months with mean follow up 21 and standard deviation 23.295. In late follow up 16 patient (94%) had favorable outcome and 1 patient (6%) had unfavorable outcome.

Aneurysms location has statistically significant correlation with clinical outcome ($P = 0.030$). The size (giant) of aneurysm was associated with worse clinical outcome however, it was statistically insignificant ($P = 0.327$), may be due to small number of cases.

Radiological outcome:

Grades of aneurysm occlusion in the final control and follow up angiography of 17 treated aneurysms were presented in table 1.

Immediate angiographic outcome:

Over all Complete occlusion Grade 0 with stent technique was achieved in 8 patients(47%), Grade I in 1 patient (6%), Grade II in 3 patients(17.5%), Grade V in 5 patient(29.5%).

2 aneurysms (50%) of previously coiled with remaining or recanalized part had Grade 0 occlusion, 1 aneurysms (25%) had Grade I occlusion and 1aneurysm (25%) had Grade 2 occlusion.

3 (60%) of small size aneurysms were completely obliterated (Grade 0), while 2 (40%) Grade V were observed. 3 (75%) of medium size aneurysms had Grade 0 occlusion while 1 (25%) had Grade I occlusion. 1 (25%) of large aneurysms had Grade 0 occlusion while 3 (75%) had Grade III occlusion. 1 (25%) of giant aneurysms had Grade 0 occlusion while 3 (75%) had Grade V occlusion.

3 (43%) of narrow neck aneurysms had Grade 0 occlusion, 1(14%) had grade I occlusion, 2 (29%) Grade II occlusion and 1 (14%) had Grade

V occlusion. 5 (50%) of wide neck aneurysms had Grade 0 occlusion, 1(10%) had Grade II occlusion and 4(40%) had grade V.

Grade of stasis was observed in 9 aneurysms not completely occluded in control angiogram Grade II in 2 aneurysms 22% (1 small 11% and 1 large 11%) (1 narrow neck 11% and 1 wide neck 11%). Grade III in 7 aneurysms 78% (1 small 11%, 1 medium 11%, 2 large 22% and 3 giant 33%) (3 narrow neck 33.5% and 4 wide neck 44.5%). however there a relation between grade of stasis with the size and neck of aneurysms and type of stent, it was statistically insignificant.

Table (1): Relation of overall grade of occlusion (immediate and follow up).

Occlusion	Immediate		Follow up		Chi-Square	
	N	%	N	%	X2	P-value
Grade 0	8	47.06	10	58.82	6.889	0.229
Grade I	1	5.88	3	17.65		
Grade II	3	17.65	1	5.88		
Grade III	0	0.00	1	5.88		
Grade IV	0	0.00	1	5.88		
Grade V	5	29.41	1	5.88		
Total	17	100.00	17	100.00		

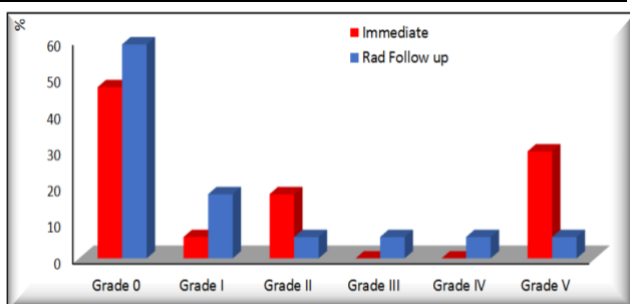


Fig. (2): Percentage of overall grade of occlusion (immediate and follow up).

Follow up angiographic outcome:

Follow-up imaging was obtained in 17 patients (100%). The mean imaging follow-up period was 21.8 months (range 0.5 to 84 months). There was no regrowth detected in the series but either increasing or unchanging in occlusion grade was observed.

Over all Complete occlusion Grade 0 with stent technique was achieved in 10 patients(59%), Grade I in 3 patient (17%), Grade II in 1 patients(6%), Grade III in 1 patient(6%), Grade IV in 1 patient(6%) and Grade V in 1 patient(6%).

Table (2): Percentage procedural difficulties.

Procedural difficulties		
	N	%
No	13	76.47
Delayed deployment	2	11.76
Failed jailing technique	2	11.76
Total	17	100.00

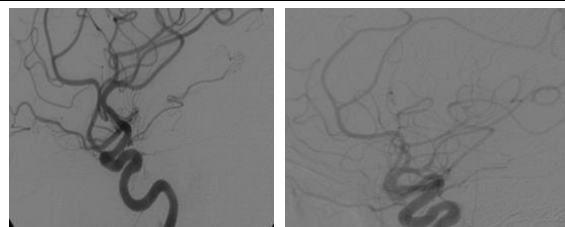


Fig. (3): 37 years old female presented by manifestation of SAH Catheter cerebral angiography (left) was done and shows Lt p.com blister aneurysm. first therapeutic intervention for coiling aborted due to wide neck and instability of microcatheter. (right) DSA lateral view 18 months after deployment of one LEO+ stent show complete occlusion with favorable outcome.

The 8 cases with Grade 0 immediate occlusion remain the same. The case with Grade I immediate occlusion remain the same. One of the 3 cases with Grade II immediate occlusion remain the same, while the others changed to complete, Grade I. one of the 5 case with immediate Grade V occlusion, remain the same while the others changed to complete, Grade I, Grade III and Grade IV.

2 aneurysms (50%) of previously coiled with remaining or recanalized part had Grade 0 occlusion and 2 aneurysms (50%) had Grade I occlusion.

4 (80%) of small size aneurysms were completely obliterated (Grade 0), while 1 (20%) Grade V was observed. 3 (75%) of medium size aneurysms had Grade 0 occlusion while 1 (25%) had Grade I occlusion. 2 (50%) of large aneurysms had Grade 0 occlusion while 1 (25%) had Grade I occlusion and 1 (25%) had Grade II occlusion. 1 (25%) of giant aneurysms had Grade 0, 1 (25%) had Grade I occlusion, 1 (25%) had Grade III occlusion and 1 (25%) had Grade IV occlusion.

4 (57%) of narrow neck aneurysms had Grade 0 occlusion, 2 (29%) had grade I occlusion and 1 (14 %) Grade III occlusion. 6 (60%) of wide neck aneurysms had Grade 0 occlusion, 1(10%) had Grade I occlusion, 1(10%) had Grade II occlusion, 1(10%) had Grade IV occlusion and 1 (10%) had grade V.

Grade of stasis was observed in 7 aneurysms not completely occluded in follow up angiogram Grade I in 1 aneurysms 14% (small size) (wide neck). Grade III in 6 aneurysms 85% (1 medium 14%, 2 large 29% and 3 giant 43%) (3 narrow neck 43% and 3 wide neck 43%).

Procedure-related complications and difficulties:

Despite intraoperative complication and difficulties, a favorable immediate clinical outcome was noted. Unfavorable clinical outcome observed in follow up (6%) has no relation to intraoperative complication and difficulties ($P = 0.633$).

Intraoperative complication was noted in 3 cases (18%), 1 case (6%) carotid cavernous fistula managed by coiling, 1 case (6%) intraoperative rupture managed by rapid coiling and 1 case (6%) stasis was observed in of MCA branches managed by mechanical and anticoagulant. Intraoperative complication has correlation with the type of stent and intraoperative difficulties, however, it was statistically insignificant ($P = 0.451$).

Intraoperative difficulties was noted in 4 cases (23.5%), 2 case delayed deployment of the stent (observed with Pipeline and solitaire which need electrical detachment) and 2 case failed semi-jailing technique (observed in complex vascular anatomy; blister aneurysm and a cute angle parent vessel geometry).

Intraoperative difficulties statistically has correlation with the type of procedure ($P = 0.053$), it also has correlation with the type of stent, however, it was statistically insignificant ($P = 0.570$).

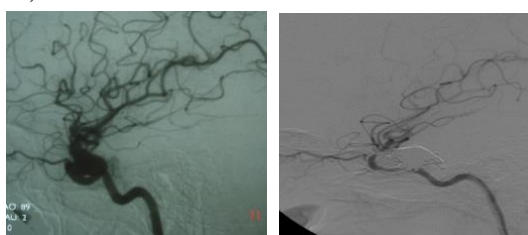


Fig. (4): DSA lateral view (left) ophthalmic segment non saccular aneurysm. (Right) occlusion of aneurysm by pipeline stent note coil mass after management CCF.

DISCUSSION

The rapid development of intracranial stents has revolutionized the management of intracranial aneurysms and has enabled the treatment of many previously untreatable cerebral aneurysms⁽¹¹⁾.

Although coil protrusion into the parent artery may often be prevented with balloon assisted remodelling technique, three dimensional shaped and bioactive coils or double-catheter technique additional support or remodelling of the aneurysm neck is occasionally required⁽¹¹⁾.

However, many limitations and challenges still persist, and stent assisted embolization is far from being a panacea in the treatment of complex intracranial aneurysms. Due to the lack of long-term knowledge on the risks of arterial injury or stenosis after stent deployment, aneurysm recurrence, or even the risk of stent fracture, all intracranial stents should be used very selectively on younger patients with a substantial life expectancy⁽¹²⁾.

The old or retrospective series presented in earlier studies consisted of first generation stents and flow diverting devices at the earliest phase of the learning curve⁽¹⁴⁾.

Aneurysm recurrence of endovascular coiling:

Aneurysm recurrence is relatively common after coil embolization, and the risk of aneurysm reopening is about 20 % in larger studies^(13,14).

However, recurrence rates of up to 33.6 % have been reported, appearing at a mean time of 12.3 months after treatment⁽¹⁵⁾.

The durability of endovascular coil occlusion is thought to depend largely on the initial packing density achieved in the aneurysm sac, but coil compaction and aneurysm recanalization may occur even in aneurysms that appear completely occluded after the initial treatment⁽¹⁶⁾.

Intracranial stents work a barrier support the coil mass and enhance dense backing of the aneurysm, also serve as scaffolding for neo-endothelization, providing additional reduction of the flow into the aneurysm. Consequently, their use improves intrasaccular thrombosis and decreases the risk of recanalization⁽⁹⁾.

In this series 4 of 17 (23%) of cases were treated by stent deployment after re-growth of previously coiled aneurysms with complete or grade I occlusion, or stationary course after stent deployment on follow up.

Antithrombotic medication with stents:

The guidelines for antiplatelet therapy after stent-assisted embolization are based mainly on cardiology experience, and recent cardiology guidelines recommended administration of acetylsalicylic acid indefinitely after coronary

stenting, whereas clopidogrel bisulphate is usually administered for 3-12 months⁽¹⁷⁾.

In intracranial stents, however, aneurysmal factors should also be considered. Incomplete aneurysm occlusion may produce a dead space in combination with the stent, resulting in continual flow disturbance and becoming a long-term embolic source⁽¹¹⁾.

Incomplete stent apposition to parent vessel wall has been shown to be related to short-term and long-term thromboembolic complications as well as vessel thrombosis and occlusion⁽¹⁸⁾.

In this series, all patients were taken double antiplatelet (clopidogrel for 3- 6 months and ASA for invariably), no symptomatic thromboembolic or in stent thrombosis was observed in follow up.

Therefore, the duration of dual antiplatelet therapy should probably be tailored to clinical status, co-morbidities, stent apposition to the parent artery wall and angiographic outcome of each patient.

Technical feasibility of stenting:

Lylyk et al.⁽¹⁹⁾ reported a technical failure rate of 8% due to delivery difficulties in first generation Neuroform stents.

Fiorella et al.⁽²⁰⁾ Encountered technical problems with stent delivery and deployment in only 2 of 53 patients using the Neuroform 2 delivery system.

In this series, Endovascular stent therapy was attempted in 17 procedures; all procedures (100%) were completed with no technical failure observed.

Also technical difficulties were observed in four cases. Failure of semi-jailing stent technique was observed in two cases (with LEO+ and LEO baby stents) due to complex configuration of aneurysms (p.com blister and acute angle A1-A2 small wide neck aneurysms).

Delayed deployment was observed in two cases treated with Solitaire and Pipeline which need electrical detachment.

Clinical results and follow-up:

In this series, the immediate clinical outcome (one week after) was favorable despite intraprocedural complication or difficulties.

Clinical follow up duration of all cases ranged from 0.75 months to 84 months with mean follow up 21. In late follow up 16 patient (94%) had favorable outcome and 1 patient (6%) had unfavorable outcome (GOS 1). This case with giant ICA bifurcation aneurysm treated by flow diverter insertion.

Clinical follow-up was excellent or good outcome (mRS 0-2) in 11 (84.6% = 11/13) patients and two patients achieved a mRS of 3. The only patient with rupture of a treated aneurysm recovered completely to the previous condition and returned to work⁽²⁰⁾.

This good clinical mid-term results of patients who survived after the initial SAH may indicate that endovascular stent application is relatively safe and well tolerable treatment option for otherwise difficult to treat intracranial aneurysms⁽²⁰⁾.

Angiographic results and follow-up:

Pasquale et al.⁽²¹⁾ found in Follow-up imaging recanalization in 25.0% (2/8) of initially completely occluded aneurysms and 50.0% (5/10) of neck-remnants or residual aneurysms resulting in an overall recanalization rate of 38.5%.

Fiorella et al.⁽²⁰⁾ reported 23% of recanalisation in 3-6 month follow-up with 52% showing progressive thrombosis, 25% showed no change.

In this series the follow-up in aneurysms after treatment with stent implantation with a mean of 21 months (range 0.75 to 84 months). There was no regrowth detected but either increasing or unchanging in occlusion grade was observed.

Over all Complete occlusion Grade 0 with stent technique was achieved in 10 patients(59%), Grade I in 3 patient (17%), Grade II in 1 patients(6%), Grade III in 1 patient(6%), Grade IV in 1 patient(6%) and Grade V in 1 patient(6%).

Flow-diverting stents:

The initial results published on endoluminal flow-diverting devices (namely the Pipeline embolization device, PED) were exceedingly promising with complete angiographic occlusion in 94 % of the treated aneurysms with angiographic follow-up at 12 months with no major clinical adverse effects peri-procedurally or during follow-up⁽²²⁾.

However, an increasing number of perforating branch strokes, stent thromboses, and parent artery stenosis at follow-up were reported in subsequent reports⁽²³⁾.

In March 2010, the manufacturer of the Silk flow-diverting stent (Balt Extrusion, Montmorency, France) released an urgent field safety notice advising to use the Silk stent only in adjunct with coil embolization since eight patients treated with a mere Silk stent had died of unexpected aneurysm rupture during short- or mid-term follow-up after the Silk implantation⁽¹¹⁾.

The release of this urgent safety field notice by the stent manufacturer also reflects the incomplete, yet continuously accumulating clinical knowledge of these novel devices.

In this study flow diverter was used in 5 patient 29%, with 100% technical success, no immediate post procedural complication was observed either symptomatic thromboembolism or in stent stenosis or thrombosis. One case with intraprocedural complication (CCF) which coiled immediately with good recovery. angiographic result on follow up; complete occlusion in 2 cases, Grade I in 2 cases and Grade III in one case. No detected late morbidity with one mortality three week after the procedure.

Although flow-diverting stents are associated with undeniable procedural risks, they represent a true advancement in the endovascular treatment of complex cerebral aneurysms and allow many previously untreatable aneurysms to be successfully managed.

Stent-related complications:

Pasquale et al.⁽²¹⁾ found that the rate of transient procedure related neurological deficits was 22.2% (4/18), all of them were due to periprocedural thromboembolism. Nevertheless, there was no permanent procedure related morbidity or mortality.

In the literature morbidity rates range from 4.8 to 25% and mortality rates from 2.1 to 8.9%^(24,25).

The most common adverse events reported were thromboembolic complications confirming the thrombogenicity of stent application⁽²¹⁾.

In our series, the one mortality case (6%) in giant aneurysm after three week follow up due to rapid thrombosis inside the aneurysm with perianeurysmal edema death suddenly occurred.

In thesis series there was no transient or permanent procedure related morbidity despite intraprocedural difficulties and complication.

Intraoperative complication was noted in 3 cases (18%), 1 case (6%) carotid cavernous fistula managed by coiling, 1 case (6%) intraoperative rupture managed by rapid coiling and 1 case (6%) stasis was observed in of MCA branches managed by mechanical suction and anticoagulant. Intraoperative complication has correlation with the type of stent and intraoperative difficulties, however, it was statistically insignificant ($P = 0.451$).

In this series no acute or delayed stent thrombosis or stenosis was observed during a mean

follow up period of 21 months (range 0.75 to 84 months).

In *Pasquale et al.*⁽²¹⁾ series there was no in-stent thrombosis in the early post treatment phase and only one asymptomatic late in-stent occlusion after six months, which showed partial resolution at further follow-up examinations.

In-stent stenosis or thrombosis in the treatment of intracranial aneurysms may be less common than in the treatment for atherosclerotic cerebrovascular disease⁽²¹⁾.

Limitations of this study:

MRI follow up is not available for all cases. Without systematic post-operative MRI studies, it is difficult to know the actual amount of clinically silent microembolic complications associated with different endovascular treatment methods.

The number of cases in this series was relatively few, and follow up period of some case was relatively short.

CONCLUSION

Endovascular stent-assisted coiling is considered a feasible, effective and relatively safe technique for the treatment of broad neck and complex configuration intracranial aneurysms with decreased recanalization rate than coiling alone. The risk of delayed in-stent stenosis or thrombosis seems to be lower compared to stent deployment in atherosclerotic lesions. Endovascular stent techniques of intracranial aneurysms are associated with acceptable rate of procedure-related complications. Continued researches for assessment of the long term follow up results of endovascular stent technique management of intracranial aneurysms are needed. multidisciplinary (surgical and endovascular) team approach allows the successful management of previously untreatable cerebral aneurysms – both now and in the future.

REFERENCES

1. **Lavine S, Meyers P (2007):** Application of New Techniques and Technologies: Stenting for Cerebral Aneurysm by The Congress of Neurological Surgeons, *Clinical Neurosurgery*, 54:64-66.
2. **Moret J, Cognard C, Well A, Castaings L, Rey A (1997):** The remodeling technique in the treatment of wide neck intracranial aneurysms. *Interv Neuroradiol.*, 3: 21-35.

3. **Tan CB, Kwok JCK, Chan KY, Lam HS (2000):** The feasibility of threedimension Guglielmi detachable coil for embolization of wide neck aneurysm. *Interv Neuroradiol.*, 6:53-57.
4. **Shin YS, Kim DI, Lee SI, Chung JI, Yoon PH, Lee K (2000):** The usefulness of the new double-catheter in the treatment of parent artery incorporated wide-necked aneurysm with Guglielmi detachable coils technique noted. *Interv Neuroradiol.*, 6:61-64.
5. **Wanke I, Doerfler A, Schoch B, Stolke D, Forsting M (2003):** Treatment of wide necked intracranial aneurysms with a self-expanding stent system: initial clinical experience. *Am J Neuroradiol.*, 24:1192-1199.
6. **Fiorella D, Albuquerque FC, Deshmukh VR, McDougall CG (2005):** Usefulness of the Neuroform stent for the treatment of cerebral aneurysms: results as initial (3-6-mo) follow-up. *Neurosurgery*, 56:1191-1201.
7. **Luo CB, Wei CJ, Chang FC, Teng MMH, Lirng JF, Chang CY (2003):** Stent assisted embolization of internal carotid artery aneurysms. *J Chin Med Assoc.*, 66:460-466.
8. **Higashida R, Halbach V, Dowd C, Juravsky L, Meagher S (2005):** Initial clinical experience with a new self-expanding nitinol stent for the treatment of intracranial cerebral aneurysms: The Cordis Enterprise stent. *American Journal of Neuroradiology*, 26: 1751-1756.
9. **Maldonado I, Bonafé A (2012):** Stent-Assisted Techniques for Intracranial Aneurysms, InTech corporation, 14: 291-310.
10. **Pasquale M, Amanda W, Jan G, Roland W, Christoph O, Michael R, Gerhard S (2008):** Stent placement in the endovascular treatment of intracranial aneurysms. *Swiss Med Wkly*, 138: 646-654.
11. **Tahminen O (2014):** Stent-assisted Endovascular Therapy of Complex Intracranial Aneurysms University of Eastern Finland, Faculty of Health Sciences, Kuopio Campus Library, (https://www.google.com/url?sa=t&rc=j&q=&esc=s&source=web&cd=1&cad=rja&uact=8&ved=0ahUKEwjY4_nSp7cAhWQ_EVAKHb7I_CawQFggmMAA&url=http%3A%2F%2Fpublications.uef.fi%2Fpub%2Fum_isbn_978-952-61-1643-3%2Fum_isbn_978-952-61-1644-0.pdf&usq=AovVaw_0GZaK8CeGC_MoKkp7q82g3F).
12. **McLaughlin N, McArthur DL, Martin NA (2013):** Use of stent-assisted coil embolization for the treatment of wide-necked aneurysms: A systematic review. *Surg Neurol Int.*, 4:43.
13. **Gonda DD, Khalessi AA, McCutcheon BA, Marcus LP, Noorbakhsh A, Chen CC et al. (2014):** Long-term follow-up of unruptured intracranial aneurysms repaired in California. *J Neurosurg.*, 120(6):1349-1357.
14. **Ferns SP, Sprengers ME, van Rooij WJ, Rinkel GJ, van Rijn JC, Bipat S et al. (2009):** Coiling of intracranial aneurysms: a systematic review on initial occlusion and reopening and retreatment rates. *Stroke*, 40(8):523-529.
15. **Raymond J, Guilbert F, Weill A, Georganos SA, Juravsky L, Lambert A et al. (2003):** Long-term angiographic recurrences after selective endovascular treatment of aneurysms with detachable coils. *Stroke*, 34(6):1398-1403.
16. **Gaba RC, Ansari SA, Roy SS, Marden FA, Viana MA, Malisch TW (2006):** Embolization of intracranial aneurysms with hydrogel-coated coils versus inert platinum coils: effects on packing density, coil length and quantity, procedure performance, cost, length of hospital stay, and durability of therapy. *Stroke*, 37(6):1443-1450.
17. **Brilakis ES, Patel VG, Banerjee S (2013):** Medical management after coronary stent implantation: a review. *JAMA.*, 310(2):189-198.
18. **Heller RS and Malek AM (2011):** Delivery technique plays an important role in determining vessel wall apposition of the Enterprise self-expanding intracranial stent. *J NeuroIntervent Surg.*, 3: 340-343.
19. **Lylyk P, Ferrario A, Pasbon B, Miranda C, Doroszuk G (2005):** Buenos Aires experience with the Neuroform self-expanding stent for the treatment of intracranial aneurysms. *J Neurosurg.*, 102:235-41.
20. **Fiorella D, Albuquerque FC, Deshmukh VR, McDougall CG (2005):** Usefulness of the Neuroform stent for the treatment of cerebral aneurysms: results at initial (3-6-mo) follow-up. *Neurosurgery*, 56:1191-201.

21. **Pasquale M, Amanda W, Jan G, Roland W, Christoph O, Michael R, Gerhard S (2008):** Stent placement in the endovascular treatment of intracranial aneurysms. *SWISS MED WKLY*, 138 (43– 44): 646–654.
22. **Lylyk P, Miranda C, Ceratto R, Ferrario A, Scrivano E, Luna HR et al. (2009):** Curative endovascular reconstruction of cerebral aneurysms with the pipeline embolization device: the Buenos Aires experience. *Neurosurgery*, 64(4):632-42.
23. **Nelson PK, Lylyk P, Szikora I, Wetzel SG, Wanke I, Fiorella D (2011):** The pipeline embolization device for the intracranial treatment of aneurysms trial. *AJNR Am J Neuroradiol.*, 32(1):34-40.
24. **Fiorella D, Albuquerque FC, Woo H, Rasmussen PA, Masaryk TJ, McDougall CG (2006):** Neuroform in-stent stenosis: incidence, natural history, and treatment strategies. *Neurosurgery*, 59:34–42.
25. **Akpek S, Arat A, Morsi H, Klucznick RP, Strother CM, Mawad ME (2005):** Self-expandable stent-assisted coiling of wide-necked intracranial aneurysms: a single-centre experience. *AJNR Am J Neuroradiol.*, 26:1223–31.