

## PUVA-Induced Skin Cancer in Dark-Skin Patient: A Case Report

Ahmed Aljaber<sup>1</sup>, Yousef Binamer<sup>2</sup>

<sup>1</sup>Medical intern, King Saud bin Abdulaziz university for health sciences,  
Riyadh, Saudi Arabia

<sup>2</sup>Department of Dermatology, King Faisal Specialist Hospital & Research Centre, Riyadh 11211,  
Saudi Arabia

Corresponding author: Yousef Binamer, dr.binamer@gmail.com, Department of Dermatology,  
King Faisal Specialist Hospital & Research Centre, Riyadh 11211, Saudi Arabia

### ABSTRACT

Non-melanoma skin cancer is reported to be a cancer with highest prevalence in the world. Different risk factors have been identified, e.g., Genetic factors, skin-type, ethnicity, and iatrogenic. The main iatrogenic factors are radiation and drugs, mainly immunosuppressive medications, and oral psoralen and ultraviolet-A (PUVA). It is known in the literature that exposure to more than 250 sessions of PUVA could be a risk for developing skin cancer. However, it was reported in fair skin patients.

Herein, we report for the first time, a PUVA-induced basal cell cancer in a type-4 skin patient after receiving 400 sessions.

**Keywords:** PUVA; basal cell carcinoma; skin cancer.

### INTRODUCTION

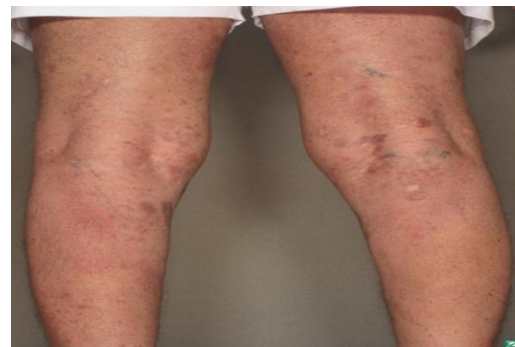PUVA (psoralen and ultraviolet-A) is an old effective therapeutic modality. It has been used in many skin diseases, most commonly eczema, vitiligo, and psoriasis<sup>[1]</sup>. However, it falls out of favor due to side effects. Most of the phototherapy units have shifted into narrow-band ultraviolet light therapy (NB-UVB). One of the reported concerns is the non-melanoma skin cancer (NMSC) after using PUVA therapy<sup>[2]</sup>.

Murase et al<sup>[1]</sup> reported in one study that there is no higher risk after using PUVA among Arabian African and Asian people.

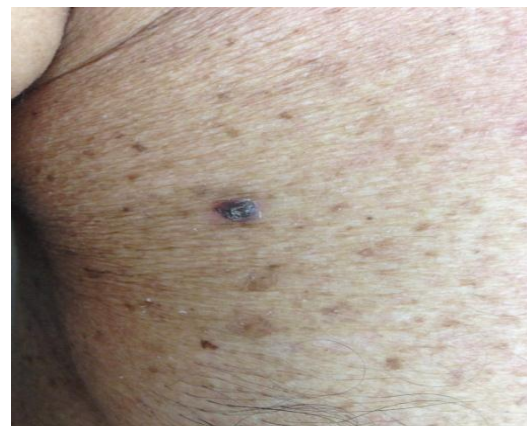
In this report, a case of basal skin cancer in a dark-skin patient after a treatment of 400 sessions of phototherapy for T-cell lymphoma has been studied.

### Case Report

A 76-year-old male, a known patient of T-cell lymphoma 30 years ago, during which he received 400 sessions of oral PUVA and more than 600 sessions of NB-UVB. On physical examination, he has three basal cell carcinomas (BCCs) on trunk with generalized lentigines. The diagnosis was made based on biopsy confirmation. He underwent curettage and dissection and received isotretinoin 20 mg daily for one year. Since then, he developed two more BCCs which was treated with topical 5-fluorouracil cream (Figs. 1,2).



**Figure 1.** Multiple nodules on arms (CTCL) with lentigines on trunk.



**Figure 2.** Multiple lentigines on trunk with basal cell carcinoma.

## DISCUSSION

In 1977, PUVA was considered as an effective therapy for psoriasis <sup>[3]</sup>, and in 1979, Stern and Study documented an increased risk of NMSC after using PUVA for a long period <sup>[4]</sup>.

Since then, more reports documented the carcinogenicity of PUVA in humans. A 30-year cohort study by Stern and Study <sup>[4]</sup>, documented the long-term risk of PUVA and developing basal and squamous skin cancer. The risk was mostly after using more than 150 sessions of PUVA. Developing squamous skin cancer after undergoing long-term session of PUVA has higher risk when compared to basal skin cancer <sup>[4]</sup>. Moreover, Swedish follow-up study reported that cutaneous SCC had higher risk after having sessions of PUVA <sup>[5]</sup>.

Skin cancer is documented with Fitzpatrick skin type 1–3. However, it is unknown and undocumented for type-4 skin population <sup>[6]</sup>. In conclusion, this is the first report of PUVA-induced skin cancer in a dark-skin patient. Therefore, we would like to draw the attention of dermatologists of this possibility in darker skin population.

## CONCLUSION

The risk of PUVA-induced NMSC exists in type-4 skin patients, as it is evident in our patient, and we would recommend applying the same recommendations as in lighter skin patients.

**Conflict of Interest:** None

## REFERENCES

- 1. Murase JE, Lee EE, Koo J(2005):** Effect of ethnicity on the risk of developing nonmelanoma skin cancer following long-term PUVA therapy. *Int J Dermatol* .,44(12):1016–21.
- 2. Lindelöf B, Sigurgeirsson B, Tegner E, Larkö O, Johannesson A, Berne B *et al.*(1991):** PUVA and cancer: a large-scale epidemiological study. *Lancet*, 338(8759):91–3.
- 3. Parrish JA, Fitzpatrick TB, Tanenbaum L, Pathak MA(1974):** Photochemotherapy of psoriasis with oral methoxsalen and longwave ultraviolet light. *N Engl J Med.*, 291(23):1207–11.
- 4. Stern RS, Study PF(2012):** The risk of squamous cell and basal cell cancer associated with psoralen and ultraviolet a therapy: a 30-year prospective study. *J Am Acad Dermatol.*, 66(4):553–62.
- 5. Diepgen TL, Mahler V. (2002):** The epidemiology of skin cancer. *Br J Dermatol*,146(s61):1–6.
- 6. Lindelof B, Sigurgeirsson B, Tegner E, Larko O, Johannesson A, Berne B *et al.* (1999):** PUVA and cancer risk: the Swedish follow-up study. *Br J Dermatol.*, 141(1):108–12.