



Study The Effect of Diffrent Two Materials Used to Secur Locator Attachments on Marginal Bone Loss of Implant Retained Mandibular Overdenture

Ehab M. Abdel Halime⁽¹⁾

Codex : 25/1804

azhardentj@azhar.edu.eg

<http://adjg.journals.ekb.eg>

ABSTRACT

This study was to evaluate the effect of two different types of housing securing materials on bone high changes using Radiographic evaluation by using cone beam CT. of Locator retained mandibular overdenture. All patient received Locator attachments. The patients were divided into two groups according to resilient or hard the securing material.

Radiographic evaluation by using cone beam CT was done for all patients after 12 months. After radiographic evaluation the securing materials were change for each group (The first group was used self-cure acrylic resin for securing the housing of locator. While, the second group used soft liner). The results of the study showed minimal marginal bone loss in soft liner group, at the end of 12 months follow-up period indicating a significant difference between the two groups.

INTRODUCTION

The major problem facing dentistry is that approximately 20% of the adult populations are edentulous. An excessive loss of the residual alveolar ridge makes it difficult to provide prosthesis that meets the needs of these dental patients. To help patients in their quest for a stable and comfortable complete denture, many remedies have been tried; that is, denture adhesives, cushions and soft-liners. These attempts have been met with limited success. Where the alveolar ridge is minimal, procedure offering functional, stable, and retentive complete denture is the implant retained overdenture.⁽¹⁾ Excessive alveolar bone atrophy often confounds a conventional therapy with complete dentures. Implant therapy has found a way to solve the problem through enhanced stability and retention, thus preserve alveolar bone increasing its functionality, leading to improved patient satisfaction and a higher quality of life.⁽²⁾

KEYWORDS

*Secur Locator,
Marginal,
bone loss*

1. Assistant Professor of Removable Prosthodontics, Faculty of Dental Medicine, Al Azhar University, (Asiut Branch)

The success of oral implant treatment relies on the presence and maintenance of bone adjacent to implants. The monitoring of radiographic bone level changes provides valuable insight into the longevity of oral implants. There are no differences in clinical and radiographical state of patients treated with an overdenture on two or four implants during a 5-year evaluation period. ⁽³⁾ Several attachments, such as splinted (bar, clip) or non splinted(ball, magnetic, Locator, and telescopic) attachments, can be used to retain IRMODs to the implants.⁽⁴⁾ The choice of a particular attachment is dependent up on the retention required, jaw anatomy, inter-ridge distance, and patient compliance for recall to perform adequate maintenance. Nonsplinted anchorage system require less space within the prosthesis, provide easier hygiene, and are less technique sensitive than splinted designs.^(5,6) The resilient attachments allowed for a better load distribution between the dental implants and the denture bearing surface.⁽⁷⁾ A relatively recent attachment that becomes increasingly popular is the locator attachment. compared to ball anchors, locator can be used in patients who have limited interarch distance to reduce denture base deformation and fracture thanks to their low have different profil. They also resilient, self-aligning degrees of retention values, and have some built-in angulation compensation. In addition, repair and replacement are simple and easy.⁽⁸⁾ The most Common prosthetic complication reported with the use of the Locator system is loosening of the retentive mechanism.⁽⁹⁾ Plastic deformation, wear, and surface abrasion are all possible causes for the loss of retention. Several factors affecting the retention of Locator attachments have been identified, including repeated insertion-removal cycles of the prosthesis.⁽¹⁰⁾ Self cure acrylic resin material can be used directly for securing attachments in mandibular implant retained overdentures ⁽¹¹⁾, where as heat cure acrylic resin are used indirectly to secure the attachment into the denture base during processing of the overdenture. ⁽¹²⁾Recently resilient denture liners have found increasing favor in several

applications in prosthetic dentistry, including their use with dental implants for retention ⁽¹³⁾.

The purpose of this study will be to evaluate the effect of two different types of housing securing materials on bone hight changes using Radiographic evaluation by using cone beam CT. of Locator retained mandibular overdenture

MATERIAL AND METHODS

Twelve completely edentulous 6 male and 6 female patients were selected in the present study, with ages ranged from 50 to 55 years. They were selected from the out patient clinic of Prosthodontics Department, Faculty of Dental Medicine; Al – Azhar University, Assiut. All patients were selected according to the following criteria: the last extracted tooth was at least 6 months before beginning of the study. Free from any systemic diseases that may affect the prognosis of implant-overdenture and the rate of bone resorption. For each patient, an upper and lower conventional complete dentures were constructed as usual. Bilateral mandibular nerve blocks and local infiltration to the implant sites were given. The surgical procedure was initiated with an intra oral crestal incision between two canines and mucoperiosteal flap were elevated both buccally and lingually to expose the bone. Surgical stent was made and seated on the bone, by using surgical bar depression was made at the definitive position of the implant. Initial bone drilling was started with the pilot drill. Direction indicator was used to verify the direction of the osteotomies. Intermediate drill was then used to expand the osteotomies to the full depth. Paralleling tools were used to parallelism between the two osteotomies. The implants were screwed in clockwise direction into the prepared sites vertically and parallel to each other until it reached the full length. Covering screws were screwed to the fixtures. The mucoperiosteal flaps were sutured for healing. Patients were instructed to take antibiotics to avoid infection. Patients were given 3 months healing period to assure complete implant bone osseointegration.

All patient received Locator attachments. The patients were divided into two groups according to resilient or hard the securing material. Six patient in each groups according to random cross section study. The first group was used soft liner for securing the housing of locator. While, the second group used self-cure acrylic resin.

Radiographic evaluation by using cone beam CT were done for all patients after 12 months.

After radiographic evaluation the securing material were change for each group (The first group was used self-cure acrylic resin for securing the housing of locator. While, the second group used soft liner). And radiographic evaluation after another 12 months.

Radiographic Evaluation:

Cone beam scanning Evaluation:

- a- Cone beam was used for assessment of bone height changes labial, lingual, mesial and distal to both implants.
- b- CBCT Planmeca machine used in this study was characterized by the following: the detector of this machine is composed of CMOS flat panel with isotropic voxel size 133Um. The X-ray tube used to scan the samples possess a current intensity 16 mA, kilovoltage 85 K vp and focal spot size 0.5 mm.
- c- The scanning time was 18 seconds of pulsed exposure resulting in an effective exposure time 3 seconds to scan FOV of 13 cm Height x14.5 cm Width x 14.5cm Depth, FOV adjustment was guided by three laser light beams to centralize the area of interest within the scanning field.
- d- Then the primary reconstruction time for DICOM data was set was 2 minutes.
- e- The patient was placed on the machine and FOV was adjusted guided by laser lines (fig 1).

Linear Measurements

Linear measurements of bone loss around implant were done as follow. On the window of CBCT cross

sectional and sagittal cut was selected in which the margin of the implant was well demarcated.

Using the software a line was drawn on labial, lingual, mesial and distal, from the collar margin of implant to alveolar crest. The lies represent bone loss around the implant. The same procedure using the same the sectional cut was repeated at insertion, 1 year and 2 year.

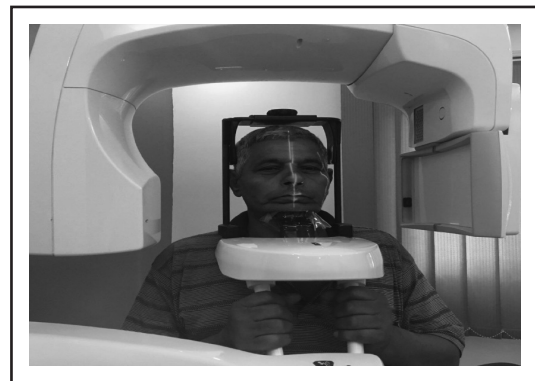


Fig. (1) Cone beam Planmeca machine

RESULT

Table (1) show that the mean marginal bone loss (mm) of soft liner and self cure acrylic resin after one year of loading. There was significant difference in marginal bone loss in soft liner scuring Locator attachments and in self cured securing Locator attachments group after one year of this study.

Table (1) *The mean, standard deviation (SD) values and results of two-way repeated measures ANOVA test for comparison between the two different scuring material after 12 months.*

Surface	Soft liner		Self cure		P-value
	Mean	SD	Mean	SD	
Mesial	3.05	0.29	3.28	0.13	0.174
Distal	3.96	1.06	4.05	1.05	0.035*
Buccal	4.39	0.21	4.54	0.19	0.005*
Lingual	2.50	0.36	2.65	0.36	0.035*
Overall	3.48	0.43	3.63	0.39	0.009*

*: Significant at $P \leq 0.05$

Table (2) The mean, standard deviation (SD) values and results of two-way repeated measures ANOVA test for comparison between the two different securing material after 24 months.

Surface	Soft liner		Self cure		P-value
	Mean	SD	Mean	SD	
Mesial	4.02	0.51	4.38	0.16	0.188
Distal	4.86	1.96	5.07	1.75	0.045*
Buccal	5.19	0.41	5.64	0.29	0.007*
Lingual	3.40	0.46	3.75	0.46	0.045*
Overall	4.28	0.53	4.63	0.48	0.0011*

*: Significant at $P \leq 0.05$

DISCUSSION

The present study indicated that all the patients were satisfied with Locator attachments implant retained overdentures compared to their original conventional dentures. All the patients stated that their ability to chew and eat hard food was better with their implant-retained overdentures. These results are in agreement with previously reported findings.⁽¹⁴⁾ In the present study no implants were lost during the follow up period this is in agreement with reports that loaded osseointegrated root form implants under mandibular overdentures have an implant survival rates of 97% to 100%.⁽¹⁵⁾ The results of marginal bone loss in the hard securing material group coincide with another study.⁽¹⁶⁾ better results were obtained from the soft liner group.

In this study were concluded that resilient liner securing Locator attachment had significantly decreased marginal bone loss during the follow up period compared with self cure acrylic resin when used as a securing material. Several reasons may explain these results: first, soft liner attachments decrease trauma and increase blood supply to peri-implant tissues, and condition these tissues. Second, glazing material seals surface porosity and

roughness of resilient liners, which significantly minimizes candidal and microbial adhesion⁽¹⁷⁾ third, shock-absorbing ability of soft liner reduces the stress applied to the implants which in turn reduces peri-implant bone loss⁽¹⁸⁾ fourth, methylmethacrylate (MMA) which is present in significant amounts in self cure acrylic resins has the potential to elicit irritation, inflammation and allergic response of the oral mucosa.⁽¹⁹⁾

CONCLUSIONS

1. The use of two implants at the canine areas is adequate to retain Locator attachment overdentures.
2. From the clinical point of view, satisfactory results were obtained when Locator attachment of implant was used to retain mandibular overdenture.
3. The soft liner and self cure materials securing Locator attachment of implant retained mandibular over denture showed. Marginal bone loss was significantly higher in the self cured securing material group than the soft liner one.

REFERENCES

1. Branemark P. I.: Osseointegration and its experimental back ground, J. Prosthet Dent, 1983; 50: 399-405
2. Att W., Stappert C.: Implant therapy to improve quality of life, Quintessence Int., 2003; 8 : 573- 81.
3. Vis ser A, Raghoebar G, Meijer H, Batenburg R Vissink A: Mandibular overdentures supported by two or four endosseous implants A 5-7- Edward P., Allen, Stephen C., Bayne, Alan H., Brodine et al: Annual review of selected dental literature, Report of the Committee on Scientific Investigation of the American Academy of Restorative Dentistry, The Journal of Prosthetic Dentistry, 2002; 88: 60-88.
4. Edward P., Allen, Stephen C., Bayne, Alan H., Brodine et al: Annual review of selected dental literature, Report of the Committee on Scientific Investigation of the American Academy of Restorative Dentistry, The Journal of Prosthetic Dentistry, 2002; 88: 60-88.
5. Trakas T, Michalakis K, et al: Attachment systems for implant retained overdenture: aliterature review. Implant Dent 2006, 340-348

6. Alsabeeha NH, Payne AG, Swain MV: Attachment systems for mandibular two-implant overdentures: a review of in vitro investigation on retention and wear features. *Int J Prosthodont* 2009, 22:429-440
7. Daas M, Dubois G, Bonnet A, Lipinski P, and Rignon C: A complete finite element model of a mandibular implant-retained overdenture with two implants: Comparison between rigid and resilient attachment configurations. *Medical Engineering and Physics*. 2008; 30, 218-225.
8. Nguyen CT, Masri R, Driscoll CF, et al : The effect of denture cleansing solution on the retention of pink Locator attachments: an in vitro study. *J Prosthodont* 2010, 19: 226-230
9. Ahuja S, Cagna DR: Classification and management of restorative space in edentulous implant overdenture patients *J Prosthodont* 2011, 105,332-337
10. Rutkunas V, Mizutani H, Takahashi H, et al: Wear simulation effects on overdenture stud attachments. *Dent Mater J* 2011, 30:845-853
11. Corinne T., Michel M., Etienne W., Oliver E. : direct procedure for connecting a mandibular implant retained overdenture with ball attachments, *J Prosthet Dent* 2004; 92:403-
12. Batenburg R.H.K., Raghoebar, G.M. Van Oort, R.P. Heijdenrijk, K. Boering G. (1998): Mandibular overdentures supported by two or four endosteal implants. A prospective, comparative study. *Int. J. Oral Maxillofac. Surg.* 27: 435-439.
13. Kiat-Amnuay, S., Khan, Z.K. & Gettleman, L.: Overdenture retention of four resilient liners over an implant bar. *Journal of Prosthetic Dentistry* 1999; 81: 568-573
14. Tang L, Lund JP, Tache R, Clokie CMI, Feine JS : A within-subject comparison of mandibular long bar and hybrid implant-supported prostheses: Psychometric evaluation and patient preferences. *J Dent Res* 1997; 76: 1675- 1683.
15. Marzola R, Scotti R, Fazi G, Schincaglia GP : Immediate loading of two implants supporting a ball attachment-retained mandibular overdenture: a prospective clinical study. *Clinical Implant Dentistry and Related Research* 2007;9:136- 43.
16. Patsiatzi E., Malden N., Ibbetson R: A radiographic review of bone levels around Calcitek dental implants supporting mandibular overdentures, Preliminary results at 3 to 6 years, *Eur. J. Prosthodont Restor Dent*, 2006; 4: 169- 73.
17. Olan-Rodriguez, L., Minah, G.E. & Driscoll, C.F: Candida albicans colonization of surface sealed interim soft liners. *Journal of Prosthodontics*, 2000; 9: 184-188.
18. Shaygan, F., Khan, Z. & Gettleman, L.: Retention and longevity of resilient denture liners in implant overdentures. *Journal of Dental Research* 1993; 72: 272 (abstract).
19. Giunta, JL, Grauer I, Zanolosky N: Allergic contact stomatitis caused by acrylic resin. *J Prosthet Dent*, 1979; 42:188- 190.