



IMPLANT STABILITY AND MARGINAL BONE LOSS IN MANDIBULAR IMPLANT RETAINED OVERDENTURE CASES: A COMPARATIVE STUDY USING TWO STUD ATTACHMENT SYSTEMS

Yasser A Araby * and Emad MT M Agamy **

ABSTRACT

The present study was designed to compare two stud attachment systems [Locator and Ball / O-Ring attachment] in mandibular overdenture cases retained by two implants in the inter-foraminal area. Twenty completely edentulous male patients received mandibular overdentures retained by two implants were randomly assigned into two groups; Group-I received Locator attachment while Group-II received Ball / O-Ring attachment. A comparison based on implant stability quotient [ISQ] was done using Resonance Frequency Analyzer [Osstell, ISQ] and another comparison was conducted based on the marginal bone loss using cone beam computed tomography [CBCT]. The patients were then scheduled for recall appointments up to two years follow up period starting from the loading time. The statistical analysis of the results reported no significant difference for the marginal bone loss & ISQ values between the two groups at all intervals except the third month implant stability results which showed a significant difference between the two groups with better stability results in the Locator attachment group (at $p < 0.05$). Within the limits of the present study, it may be concluded that both studied attachment systems are successful and useful however the Locator attachment system shows superior initial stability results than the Ball attachments.

KEY WORDS: Implant supported overdenture, locator attachment, implant stability, resonance frequency analysis, marginal bone loss, cone beam computed tomography.

INTRODUCTION

Whilst the majority of patients is reasonably happy with a well made upper complete denture, many are not as satisfied with a lower complete denture. Patients frequently complain of looseness and social embarrassment due to movement of

the prosthesis during function. Implant-retained overdentures are a highly useful treatment modality for many of those patients.¹

According to McGill Consensus Statement on overdentures and more recently in the York Consensus Statement; mandibular two-implant

* BDS, MSc DS, DDS, Lecturer of Prosthetic Dental Sciences. College of Dentistry, Qassim University, KSA

** BDS, MSc DS, PhD, Associate Professor and Head of Prosthetic Dentistry Department, Faculty of Dentistry, Minia University, Egypt

overdentures are suggested as the standard of care for edentulous patients.^{2,3}

Many systems and different designs of attachments are now available for use in implant overdentures including the Ball/O-ring, bar(s)/clip(s), magnets and Locator attachments. Clinical judgment and the individual needs of the patients should be used carefully in the selection of appropriate attachments.⁴

For many years the Ball / O-ring was the most popular stud attachment available to the dental profession to increase the retention of implant complete and partial overdentures as well as conventional overdentures. They possess a number of advantages, including the ease of use and maintenance, low cost, elimination of a superstructure bar, its wide range of movement, and great patient satisfaction. On the other hand O-rings wear over time, gradually lose retention, and must be replaced periodically. Also; it is essential that ball attachments be parallel to each other.⁵

The Locator attachment system was introduced in 2001, as a new system with an improved design combined from the best features of a ball attachment, an ERA attachment, and a cap attachment.⁶ It features a reduced inter-arch requirement, dual retention, rotational pivoting action and the advantage of built-in guide planes providing precise insertion and can also be used in non parallel situations and is available in different colors with different retention values.⁷

Evaluation and assessment are integral parts of post-surgical monitoring of dental implants during healing and for follow-up visits.

Implant stability is a prerequisite for the long-term clinical success of dental implants. Initially, implant stability is provided mechanically by macro-retentions engaging in the bony walls of the implant bed. During healing, this primary stability will be replaced by a biological bonding

of newly formed bone to the implant surface and is then termed secondary stability.⁸ Implant stability measuring using resonant frequency analysis (RFA) is a modern, non-invasive and a relatively precise technique, which provides both information on implant stability in the bone and a reliable guidance to further course of implant therapy.⁹

The use of cone-beam computed tomography (CBCT) has led to a complete paradigm shift in implant dentistry – no other technology has been as influential in combining surgery, diagnostics and prosthetics.¹⁰ CBCT technology allowed preoperative interactive diagnosis of the prospective implant sites as well as objective assessment of the peri-implant bone quantity and quality.^{11,12}

MATERIALS AND METHODS

Patients selection

Twenty completely edentulous male patients, ranging from 45 to 60 years of age [mean age of 57.4 years], were chosen to be included in the study. The inclusion criteria for the selected subjects were: At least one year of edentulism, skeletal class- I Angle arch relationship, sufficient bone quality and quantity that allow placement of the planned two dental implants and the patient's commitment to participating in the follow-up examinations of this study. While the exclusion criteria included; presence of any medical condition affecting osseointegration, any logistic, psychiatric or physical reasons that could affect follow-up, any local pathological condition or bone-grafted jaws or lack of motivation for adequate home care.

Implant planning

Routine medical and dental investigations were performed for each patient. Preoperative radiographic planning of the implant sites was conducted using cone beam computed tomography (CBCT) and a replica of the patient's lower denture (Fig.1). For visualization of the drilled sites during CBCT

scanning, amalgam acrylic resin powder mix 1 to 3 by weight¹³ was utilized to fill 4 mm depth channels at the center of each canine to act as radiopaque object. The orifice of each channel was sealed by a small piece of base plate wax and the radiographic examination was carried out while the patient was wearing the template. The radiographic template was thereafter transformed to a surgical stent.

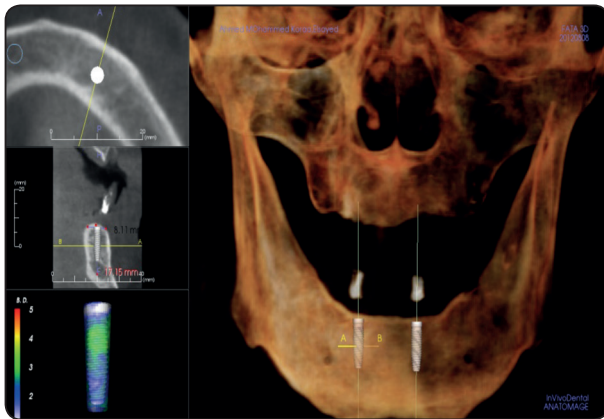


Fig. (1) Checking future implant sites using preoperative CBCT. The amalgam acrylic powder mix is showing opposite to the planned implant sites.

Surgical procedures

Presurgical medications were given to each patient before the surgery and included Amoxicillin 2gm one hour before surgery, then 500mg three times a day for 5 days, and the use of 0.12% chlorhexidine mouth wash before and after the surgery¹⁴. Conventional two-stage surgical approach (fig.2) was followed throughout the whole study, where each patient received two identical root form dental implants (Superline, Dentium Co, Korea) with the same length (12mm) and diameter (3.6 mm) in the interforaminal area of the mandible using a standard successive bone drilling protocol according to the manufacturer's directions with low speed, high torque and double coolant preparation of implant osteotomy sites. Proper postsurgical care, medications and instructions were given to the patients. One week after implant insertion;

the old dentures were relieved at the implant sites and relined with soft lining material (Softliner, Promedica, Germany), and the patients were allowed to use them for the rest of healing period (3 months).

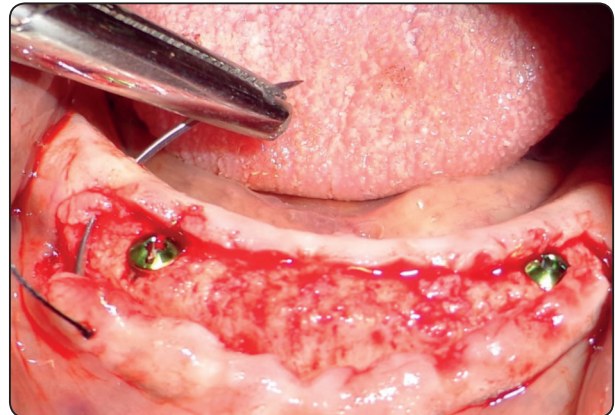


Fig. (2) Conventional Implant surgery and placement of the healing screws

Prosthetic procedures

After the 3 months healing period a new acrylic complete denture was fabricated for each patient using the conventional standardized technique and the patients were randomly assigned into two equal groups (each consists of ten patients) according to the type of attachment used. Group (I), patients were provided with mandibular overdenture retained by Locator attachment system (Positioner, Dentium Co, Korea). Group (II), patients were provided with mandibular overdenture retained by Ball/O-ring attachment system (Dentium Co, Korea). The matrices of the Locator and Ball attachments (Dentium Co, Korea) were incorporated into the dentures with a direct intraoral pick-up procedure using a cold-curing, MMA free, hard relining material for chair side relining in one single session (Hardliner CD, Promedica, Germany) a block out spacer was used to prevent adherence of the acrylic resin to the abutment or the implant (fig.3). The patients were then scheduled for recall appointments

up to two year follow up period starting from the loading time for the resonance frequency analysis (RFA) analysis of implant stability and CBCT measurements of marginal bone loss around the implants.

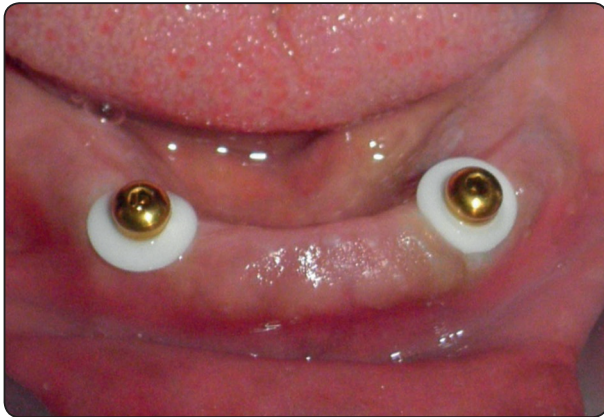

Fig. (3) Locator abutments with blockout spacer at time of loading

RFA analysis

The stability of each fixture was measured as implant stability quotient values [ISQ] with Magnetic Resonance Frequency Analyzer [Osstell ISQ, Göteborg, Sweden] (fig.4) at the time of loading then after 3, 6, 12 and 24 months. A special smart peg was connected to the implant body at 4 - 5 N/cm torque, and measurements were made at 2 - 3 mm away so that the probe tip of the analyzer would point to the small magnet above the smart peg. Measurements were made at two directions, bucco-lingual and mesio-distal directions (fig 5). The measurements were made three times for each direction to ensure reproducibility. The mean of these values was used for statistical analysis.

Radiographic analysis

Cone Beam Computed Tomography [CBCT] images were acquired using the Scanora 3D System (Scanora® 3D, Sordex Co, Finland). The On-Demand software was used which allows the recording

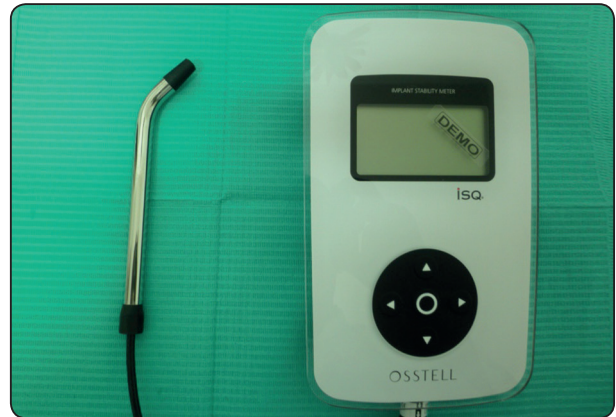

Fig. (4) Osstell ISQ Device

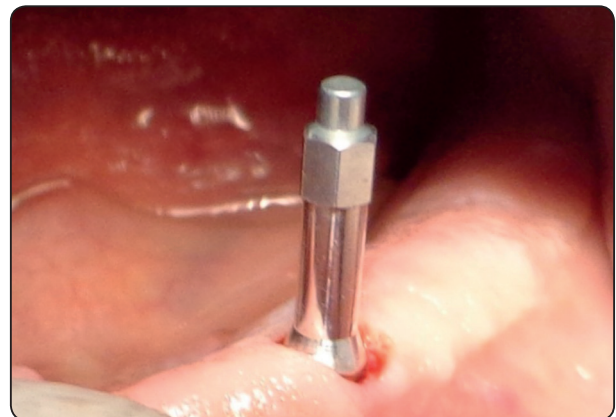

Fig. (5) Smart peg connected to the implant for ISQ measurement

of linear measurements of images. A tangential line was drawn at the apex of the implant perpendicular to the long axis of the implant. The bone height was measured from the apex of the implant to the crest of the alveolar ridge at the time of loading then after 3, 6, 12 and 24 months. The labial and lingual bone heights were measured on the sagittal view screen (fig.6), while the mesial and distal bone heights were measured on the coronal view screen. The mean value of readings of both mesial and distal together and buccal and lingual together was taken, tabulated and statistically compared.

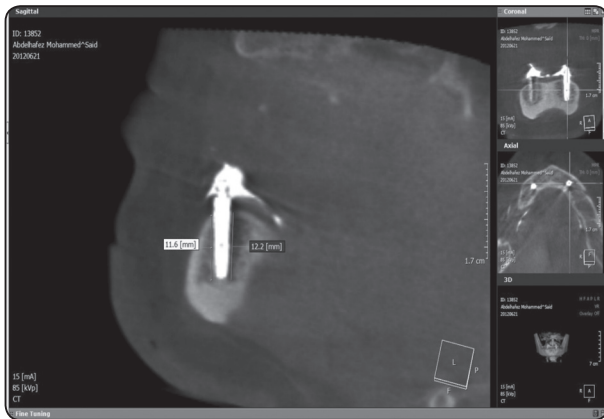

Fig. (6) Measuring bone height as seen in the sagittal section.

Statistical analysis

The collected data were tabulated and analyzed using SPSS 20.0 (Statistical Package for Social Sciences) for Windows. The descriptive analysis of the row data were presented as mean and standard deviation (SD) values. The data were tested for normality using Kolmogorov Smirnov test and the comparison was performed between the two studied groups using independent sample t-test as a parametric test, the statistical significance level was set at $P \leq 0.05$.

RESULTS

At the end of the 24 months follow-up examination, all the 40 implants exhibited clinical and

radiological successful rigid fixation with no signs of peri-implant pathology. Thus, all implants in the present study were considered successfully osseointegrated.

The RFA measurements (Table 1) showed an increase in mean ISQ values in Group (I) throughout the 3 follow up intervals from loading (ISQ=70.25) to the 12th month (ISQ=74.38) after words the change was very minute (24 months ISQ=74.78). On the other hand Group (II) showed a decrease in the ISQ values from the loading (ISQ=69.06) to the 3rd month (ISQ=68.21), followed by an increase throughout the other intervals from the 3rd month to the 12th month (ISQ=73.04) where the values remained essentially the same (24 months ISQ=73.12). However, when comparing both studied groups together, there was a statistically significant difference at the 3rd month follow up ($p = 0.047$), while no statistically significance was found at the other periods of follow up at $p < 0.05$.

The results of the mean marginal bone loss (Table 2) showed a slight increase in the bone loss throughout the evaluation period for both studied groups which was 0.98mm for group (I) and 1.05mm for group (II) at the end of the study. The comparison between the two studied groups showed no significant differences at the different intervals of the follow-up period at $p < 0.05$.

TABLE (1) Mean ISQ Values and Statistical Analysis at Different Intervals

Follow up Interval	Group I	Group II	Statistical Analysis	
	Mean ± SD	Mean ± SD	t	p
Loading	70.25 ± 5.21	69.06 ± 5.11	0.564	0.578
3 rd Month	71.75 ± 4.44	68.21 ± 3.76	2.108	0.047*
6 th Month	73.00 ± 4.02	71.25 ± 3.98	0.960	0.295
12 th Month	74.38 ± 3.93	73.04 ± 3.94	0.830	0.416
24 th Month	74.78 ± 3.22	73.12 ± 3.45	0.670	0.488

*: statistically significant at $p < 0.05$

TABLE (2) Mean Marginal Bone Loss (in mm) from Loading and Statistical Analysis

Follow up Interval	Group I	Group II	Statistical Analysis	
	Mean \pm SD	Mean \pm SD	t	p
3 rd Month	0.36 \pm 0.15	0.35 \pm 0.16	0.164	0.871
6 th Month	0.51 \pm 0.19	0.53 \pm 0.17	0.201	0.842
12 th Month	0.75 \pm 0.22	0.76 \pm 0.24	0.188	0.853
24 th Month	0.98 \pm 0.26	1.05 \pm 0.28	0.222	0.866

*: statistically significant at $p < 0.05$

DISCUSSION

Twenty male patients were selected for this study with their age ranging from 45 to 60 years. Older patients were not chosen as it was found that although endosseous implants are not contraindicated in the elderly, yet success rates might be less than optimal with advancing age.¹⁵ A male sample was selected in this study so that the measurements for amount of bone change would not be contributed to any influential feminine related factors such as hormonal changes.¹⁶

CBCT was selected for preoperative assessment of the implant sites in this study as the traditional radiographs, such as panoramic and periapical films have been found to be of limited diagnostic value owing to their 2-dimensional nature, While CBCT allows the capture of cross-sectional images at lower radiation doses with superior quality of the images and less expenses when compared to the conventional computed tomography (CT).¹⁷

During the construction of the radiographic template, the amalgam acrylic resin powder mix of 1:3 by weight was used as a radio-opaque marker as it have high visibility properties at all areas of scans because it provides distortion free medium with very low costs and simplicity compared with other radio-opaque indicators.¹³

A standardized implant size was used for all patients to eliminate the effect of implant surface area on the integration process as the difference in implant length and or diameter may influence the pressure per unit area in the supporting bone.¹⁸

Regarding the evaluation of the dental implants, Salvi and Lang, 2004 stated that; the parameters routinely used to monitor oral implants during maintenance care should be of high sensitivity and/or specificity, easy to measure and should yield reproducible data.¹⁹

Objective measurement of implant stability is a valuable tool for achieving consistently good results first and foremost because implant stability plays such a significant role in achieving a successful outcome. Various methods have been introduced to measure implant stability; including primitive methods, such as percussion and mobility testing by applying lateral forces with mirror handles, and more recent methods, such as measuring cutting torque resistance, insertion torque values, reverse torque tests, periotest, dental fine tester, and histomorphometric and histologic analysis of the bone-implant interface. All of these have some disadvantages, including questionable accuracy and reliability, lack of repeatability, and an invasive or destructive nature, so they are not practical in a clinical setting.²⁰

The need for a user-friendly, noninvasive, reliable, and clinically applicable technique to measure implant stability led to the development of RFA by Meredith and coworkers in 1996²¹.

A commercially available electronic device, based on RFA, with the trade name Osstell, is widely used for experimental and clinical purposes. This device measures implant stability and quantifies it in ISQ values²². As a diagnostic method, the Osstell instrument enables the clinician to optimize implant healing, prosthetic construction, and surgical protocol because it can provide repeated measurements of implant stability at placement, during healing, and during and after loading, allowing the clinician to detect implant instability and take appropriate steps to remedy it and to rescue an implant prior to failure²³.

The results of our study revealed an increase in the ISQ value of both groups at the end of the follow up period, this is in agreement with several investigations which confirmed that; the ISQ value of a stable osseointegrated implant increases with time, suggesting an increase in the bone-implant contact area²⁴⁻²⁶.

The statistical analysis of the ISQ results between the two studied groups showed a statistically significant difference between the two groups at the 3rd month after loading with better results for the Locator group while no significance difference at the other intervals. This could be attributed to the fact that, Ball/ O-ring system transferred high bending forces to the implants under laterotrusive loads²⁷. Also it might be attributed to the different degree of stiffness of the retentive components of the two systems²⁸. Nevertheless these variations in lateral loads and stiffness of the retentive components seems to be within the degree of tolerance of bone as the ISQ values were not statistically different for the rest of follow up period. It seems wise to assume that the bone deposition around the implants have reached a maximum value between 6 and 12 months

of loading that led to plateau of the readings. An important factor that could led also to these results is the use of CBCT in preoperative evaluation and implant planning. This tool allowed for perfect implant placement with enough bone all-around the implants at the neck. The bone thickness at this area is very crucial regarding implant stability and or bone loss.

Radiographic assessment of marginal bone loss is one of the most used criteria in longitudinal control of dental implant Osseointegration. Generally, periapical radiographs made under standardized conditions can provide useful images of dental implants and the surrounding bone over time and can provide a fairly accurate assessment of the alveolar bone crest and possible marginal bone loss on the proximal aspect of the dental implant. However, the marginal bone on the buccal and lingual/palatal surface of the dental implant, the proximity of the implants to the buccal and lingual/palatal plates, and the possible perforation of the plates cannot be assessed, because of the limitations of 2-D images. These limitations can theoretically be overcome using CBCT, which provides cross-sectional images in the region of the implant and, consequently, a more complete assessment of the dental implant.¹¹ The use of CBCT for post loading evaluation has also eliminated many of the errors resulting from superimpositions from the outer and inner cortical plates.

Regarding the marginal bone level loss, there was a slight increase throughout this study. The accumulated mean marginal bone loss recorded after 24 months was 1.08mm for the Locator group and 1.12mm for the ball attachment group which considered within the accepted limits occurring with osseointegrated implants according to many previous studies²⁹⁻³¹. There was no statistical significant difference between the two groups, this was in accordance with Cehreli et al, 2010 who found in a systematic review and meta-analysis of

the literature that there was no difference in marginal bone loss around implants retaining/supporting mandibular overdentures relative to implant type or attachment designs³².

CONCLUSION

Within the limits of the present study, it may be concluded that; both studied attachment systems are successful and useful. Regarding the marginal bone loss there is no statistical significant difference between the two studied attachment systems, however the Locator attachment system showed superior initial stability results than the Ball attachments.

REFERENCES

- Vasant R, Vasant MK. Retention systems for implant-retained overdentures. *Dent Update*. 2013; Jan-Feb;40(1):28-31.
- Thomason JM, Feine J, Exley C, Moynihan P, Muller F, Naert I, et al. Mandibular two implant-supported overdentures as the first choice standard of care for edentulous patients--the York Consensus Statement. *Br Dent J*. 2009; Aug 22;207(4):185-6.
- Feine JS, Carlsson GE, Awad MA, Chehade A, Duncan WJ, Gizani S, et al. The McGill Consensus Statement on Overdentures. Montreal, Quebec, Canada. May 24-25, 2002; *Int J Prosthodont*. 2002 Jul-Aug;15(4):413-4.
- Evtimovska E, Masri R, Driscoll CF, Romberg E. The change in retentive values of locator attachments and hader clips over time. *J Prosthodont*. 2009; Aug;18(6):479-83.
- Winkler S, Piermatti J, Rothman A, Siamos G. An overview of the O-ring implant overdenture attachment: clinical reports. *J Oral Implantol*. 2002; 28(2):82-6.
- Ahuja S, Cagna DR. Defining available restorative space for implant overdentures. *J Prosthet Dent*. 2010; Aug;104(2):133-6.
- Kleis WK, Kammerer PW, Hartmann S, Al-Nawas B, Wagner W. A comparison of three different attachment systems for mandibular two-implant overdentures: one-year report. *Clin Implant Dent Relat Res*. 2010; Sep;12(3):209-18.
- Huwiler MA, Pjetursson BE, Bosshardt DD, Salvi GE, Lang NP. Resonance frequency analysis in relation to jawbone characteristics and during early healing of implant installation. *Clin Oral Implants Res*. 2007; Jun;18(3):275-80.
- Konstantinoviü V, Ivanjac F, Lazitiü V, Djordjeviü I. Assessment of implant stability by resonant frequency analysis. *Vojnosanit Pregl*. 2015; 72(2): 169-74.
- Schneider D, Marquardt P, Zwahlen M, Jung RE. A systematic review on the accuracy and the clinical outcome of computer-guided template-based implant dentistry. *Clin Oral Implants Res*. 2009; Sep;20 Suppl 4:73-86.
- Angelopoulos C, Aghaloo T. Imaging technology in implant diagnosis. *Dent Clin North Am*. 2011; Jan;55(1):141-58.
- Fuh LJ, Huang HL, Chen CS, Fu KL, Shen YW, Tu MG, et al. Variations in bone density at dental implant sites in different regions of the jawbone. *J Oral Rehabil*. 2010; May 1;37(5):346-51.
- Agamy ET MA. An accurate dual purpose stent for diagnosis and placement of osseointegrated implants with computerized tomography. *Egyptian Dental Journal*. 2009;55:1455-62.
- Mellado-Valero A, Ferrer Garcia JC, Herrera Ballester A, Labaig Rueda C. Effects of diabetes on the osseointegration of dental implants. *Med Oral Patol Oral Cir Bucal*. 2007;12(1):E38-43.
- Porter JA, von Fraunhofer JA. Success or failure of dental implants? A literature review with treatment considerations. *Gen Dent*. 2005; Nov-Dec;53(6):423-32; quiz 33, 46.
- August M, Chung K, Chang Y, Glowacki J. Influence of estrogen status on endosseous implant osseointegration. *J Oral Maxillofac Surg*. 2001; Nov;59(11):1285-9; discussion 90-1.
- Huynh-Ba G, Alexander P, Vierra MJ, Vargas A, Oates TW. Using an existing denture to design a radiographic template for a two-implant mandibular overdenture. *J Prosthet Dent*. 2013; Jan;109(1):53-6.
- Meijer HJ, Kuiper JH, Starmans FJ, Bosman F. Stress distribution around dental implants: influence of superstructure, length of implants, and height of mandible. *J Prosthet Dent*. 1992; Jul;68(1):96-102.
- Salvi GE, Lang NP. Diagnostic parameters for monitoring peri-implant conditions. *Int J Oral Maxillofac Implants*. 2004;19 Suppl:116-27.

20. Meredith N. Assessment of implant stability as a prognostic determinant. *The International journal of prosthodontics*. 1998; Sep-Oct;11(5):491-501.
21. Meredith N, Alleyne D, Cawley P. Quantitative determination of the stability of the implant-tissue interface using resonance frequency analysis. *Clin Oral Implants Res*. 1996; Sep;7(3):261-7.
22. Sennerby L, Meredith N. Implant stability measurements using resonance frequency analysis: biological and biomechanical aspects and clinical implications. *Periodontol* 2000. 2008;47:51-66.
23. Herrero-Climent M, Santos-Garcia R, Jaramillo-Santos R, Romero-Ruiz MM, Fernandez-Palacin A, Lazaro-Calvo P, et al. Assessment of Osstell ISQ's reliability for implant stability measurement: A cross-sectional clinical study. *Med Oral Patol Oral Cir Bucal*. 2013;18(6):e877-82.
24. Friberg B, Sennerby L, Meredith N, Lekholm U. A comparison between cutting torque and resonance frequency measurements of maxillary implants. A 20-month clinical study. *Int J Oral Maxillofac Surg*. 1999; Aug;28(4):297-303.
25. Karakoca-Nemli S, Aydin C, Yilmaz H, Sarisoy S. Stability measurements of craniofacial implants by means of resonance frequency analysis: 1-year clinical pilot study. *Int J Oral Maxillofac Implants*. 2012; Jan-Feb;27(1):187-93.
26. Rasmusson L, Kahnberg KE, Tan A. Effects of implant design and surface on bone regeneration and implant stability: an experimental study in the dog mandible. *Clinical implant dentistry and related research*. 2001;3(1):2-8.
27. Fanuscu MI, Caputo AA. Influence of attachment systems on load transfer of an implant-assisted maxillary overdenture. *J Prosthodont*. 2004; Dec;13(4):214-20.
28. Ibrahim A. Evaluation of low profile attachments for implant-retained mandibular overdentures in restoring cases with limited interarch space. *CDJ*. 2009;25:191-203.
29. Elsayad MA, Elsaieh EA, Khiraallah AS. Marginal bone resorption around immediate and delayed loaded implants supporting a locator-retained mandibular overdenture. A 1-year randomised controlled trial. *J Oral Rehabil*. 2014; 41(8): 608-18.
30. Turkyilmaz I, Tozum TF, Fuhrmann DM, Tumer C. Seven-year follow-up results of TiUnite implants supporting mandibular overdentures: early versus delayed loading. *Clinical implant dentistry and related research*. 2012; May;14 Suppl 1:e83-90.
31. Meijer HJ, Raghoobar GM, Batenburg RH, Visser A, Visink A. Mandibular overdentures supported by two or four endosseous implants: a 10-year clinical trial. *Clin Oral Implants Res*. 2009; Jul;20(7):722-8.
32. Cehreli MC, Karasoy D, Kokat AM, Akca K, Eckert S. A systematic review of marginal bone loss around implants retaining or supporting overdentures. *Int J Oral Maxillofac Implants*. 2010; Mar-Apr;25(2):266-77.