

## Management of Pseudo Tumor Cerebri by Frequent Tapping VS lumboperitoneal Shunt

Ali K. Ali, Maamoun M. Abo Shousha, Mohammed R. Metwally

Department of Neurosurgery, Faculty of Medicine, AL-Azhar University

Corresponding author: Mohammed R. Metwally, Mobile: 01124242660; Email: ahmadmohamad705@gmail.com

### ABSTRACT

**Background:** The syndrome known as pseudotumor cerebri (PTC) is generally thought of as a condition characterized by increased intracranial pressure (ICP) without evidence of dilated ventricles or a mass lesion by imaging, normal cerebrospinal fluid (CSF) content, and papilledema occurring in most cases in young, obese women without any clear explanation. **Aim of the Work:** to highlight the early diagnosis, causes of visual deterioration of idiopathic intracranial hypertension, its pathophysiology will be discussed. Special emphasis will be given for trends in management of this disease especially frequent tapping and lumboperitoneal shunt and comparing results of both techniques. **Patients and Methods:** This prospective and retrospective study was conducted on 20 patients of special criteria confirmed to have pseudotumor cerebri by clinical presentation, radiological findings, fundus and visual field examination. **Results:** The papilledema of PTC was identical with that in patients with other causes of increased ICP. In most of cases it was bilateral symmetrical, however it was asymmetric in 1% of cases. In the frequent tapping patients group, results showed improvement of all symptoms in about 80% of patients. And in 20% of patients there were persistent complaints especially headache and blurred vision. In the lumboperitoneal shunt group, 65% of Cases showed improvement of all symptoms while 35% of cases showed shunt failure and complications.

**Conclusion:** Concerning the category of patients participated in this study, and particularly with whom medical measures were failing, consideration should be given to investigation of the cranial venous outflow tract with a view to some therapeutic intervention if appropriate.

**Key words:** Intracranial pressure, Lumboperitoneal shunt, Papilledema

### INTRODUCTION

Idiopathic intracranial hypertension was known as benign intracranial hypertension as its name implies, a disease of raised intracranial pressure which usually runs a self-limiting course without evidence of hydrocephalus or intracranial masses. Although termed 'benign', this condition can cause blindness due to severe papilloedema<sup>(1)</sup>.

The etiology is generally poorly understood and the exact mechanisms of the raised pressure are not known. The condition is found typically in young, obese women, often with menstrual irregularities or taking an oral contraceptive pill, and an endocrine disturbance has been suggested. However, careful endocrine studies have failed to show significant endocrine abnormalities<sup>(2)</sup>.

Occasionally, the condition is asymptomatic and discovered during a routine ophthalmic examination when papilloedema was found. However, the most common symptom, as well as most often the initial symptom, is headache, which occurs in approximately 90% of cases. The character of the headache is not specific, but it is generally different from previous headaches and is severe<sup>(3)</sup>.

The diagnosis of IIH requires that there be no intracranial or spinal mass, no evidence of hydrocephalus, documented increased ICP, and normal CSF contents. Thus, the diagnosis cannot

and should not be made without neuro imaging, a lumbar puncture (LP) & fundus examination<sup>(4)</sup>.

Medical therapy is most appropriate when the primary problem is headache in the setting of good visual function and when it is the opinion of the physician and the patient that weight loss alone will take too long to render an effect<sup>(5)</sup>.

LP is sometimes useful to relieve increased ICP in patients with IIH. The rationale behind the procedure is uncertain. Repeated LPs are traumatic for the patient and often technically difficult to perform, but they are useful in selected individuals with intermittent exacerbation of symptoms<sup>(6)</sup>.

Surgery is performed when patients initially have severe optic neuropathy or when other forms of treatment have failed to prevent visual loss, known surgery of this condition is lumboperitoneal shunt<sup>(7)</sup>.

### AIM OF THE WORK

This work aimed at giving highlights about the early diagnosis, causes of visual deterioration of idiopathic intracranial hypertension, its pathophysiology was discussed. Special emphasis was given for trends in management of this disease especially frequent tapping and lumboperitoneal shunt and comparing results of both techniques.

## PATIENTS AND METHODS

Prospective and retrospective study was carried out on 20 patients of special criteria confirmed to have pseudotumor cerebri by clinical presentation, radiological findings, fundus and visual field examination. Diagnosis was based mostly on the “modified Dandy criteria” updated by Friedman and Jacobson in 2002 (8).

1 Symptoms of raised intracranial pressure (headache, nausea, vomiting, transient visual obscurations, or papilledema)
2 No localizing signs with the exception of abducens (sixth) nerve palsy
3 The patient is awake and alert
4 Normal CT/MRI findings without evidence of thrombosis
5 LP opening pressure of >25 cmH <sub>2</sub> O and normal biochemical and cytological composition of CSF
6 No other explanation for the raised intracranial pressure

All cases were subjected for ophthalmological consultation both for diagnostic and follow up purposes. Ophthalmological consultation was done especially for fundus examination in all cases and for assessment of the visual field in cases showing deterioration of the field of vision such as patients with chronic papilledema. **The study was approved by the Ethics Board of Al-Azhar University.**

**Inclusion criteria:** Patients at the range of 20-40 years old. Confirmed to have pseudotumor cerebri. Have no associated intracranial pathologies. With accepted visual acuity (not blind) (not hand motion). With no other ophthalmological issues affecting fundus or visual field. Patients with pseudotumor cerebri not underwent any other type of intervention for treatment of the disease such as optic nerve sheath fenestration or venous sinus stenting

**Exclusion criteria:** Patients beyond the range of age of 20-40 years old. Patients having associated intracranial pathology. Patients with severely affected visual acuity (blind), (hand motion). Patients with other ophthalmological issues affecting fundus or visual field. Patients with pseudotumor cerebri who underwent any other type of intervention for treatment of the disease such as optic nerve sheath fenestration or venous sinus stenting.

**Each patient for frequent LP was subjected to:** History taking. Clinical assessment. Pre and post tapping CT scan. MRI brain for exclusion of other intracranial pathologies. MRV brain for assessment of Dural venous sinuses. Pre and post tapping ophthalmological consultation. For fundus examination and visual field assessment if needed. Lumbar puncture for measurement of ICP, for diagnosis and for therapeutic tapping. Regular follow up of clinical presentation, fundus examination and visual field if needed

**Each patient for LP shunt was subjected to:** History taking. Clinical assessment. Pre and post operative CT scan. MRI brain for exclusion of other pathologies. MRV brain for assessment of Dural venous sinuses. Pre and post operative ophthalmological consultation for fundus examination and visual field assessment if needed. Diagnostic lumbar puncture for measurement of ICP. POST operative complications. Regular follow up of clinical presentation, fundus examination and visual field if needed.

## RESULTS

**The presented study showed that** 99% of the patients were in child bearing age. Headache, blurring of vision, diminution of vision, diplopia, pulsatile tinnitus and attacks of amaurosis fugax were the main symptoms of the cases, headache was the prominent symptom present in all cases, blurring of vision present in 85% of the cases, amaurosis fugax in 35% and diplopia in 23%. The papilledema of idiopathic intracranial hypertension (PTC) was identical with that in patients with other causes of increased ICP. In most of cases it was bilateral symmetrical, however it was asymmetric in 1% of cases. **In the group of frequent tapping** all symptoms improved in about 80% of patients. And in 20% of patients there were persistent complaints especially headache and blurred vision. In all patients, there was no relation between the opening pressure and the degree of papilledema. Visual field was not affected in cases of acute papilledema on early management of the disease while in chronic papilledema there was affection in the visual field that usually showed improvement after control of the disease (after not less than 6 months of management). **in the group of lumboperitoneal shunt:** 65% of Cases in this group showed improvement of all symptoms. 35% of cases showed shunt failure and revision.

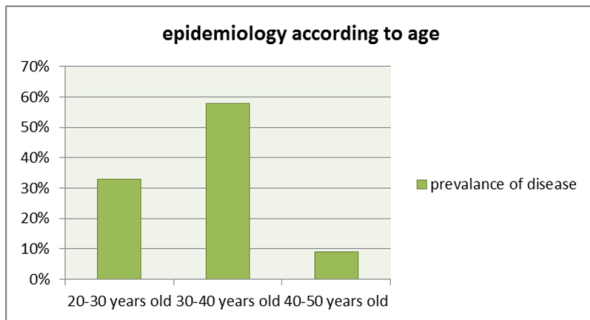


Figure (1): Epidemiology according to age.

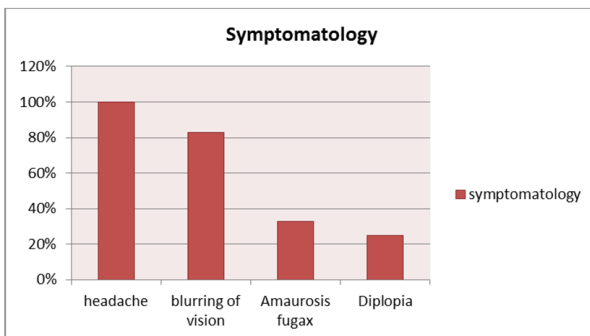


Figure (2): Symptomatology.

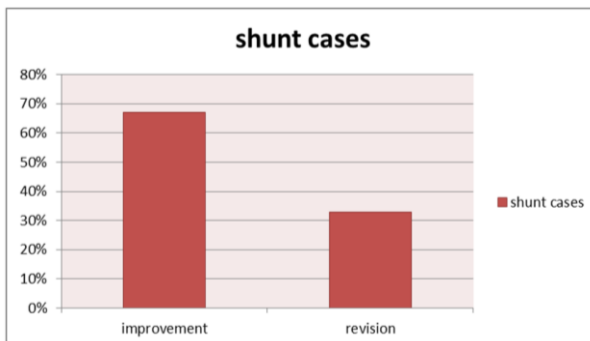


Figure (3): Revision of LP shunt.

## DISCUSSION

The study encompassed 20 patients, half of them managed by lumboperitoneal shunt and the other half managed by frequent lumbar puncture accompanied by specific medications. Most of the patients were in child bearing age.

The most frequent symptom of IIH was headache, occurring in more than 90% of cases<sup>(9)</sup>. In this series, headache was the main symptom present in all cases. It was generalized, worse in the morning, and associated with photophobia in 10% of cases.

Other symptoms included nausea, vomiting, and pulsatile tinnitus (in up to 60% of cases)<sup>(10)</sup>. In

this series, blurring of vision was presented in 85% of the cases, amaurosis fugax in 35%, diplopia in 23% and pulsatile tinnitus in 10 % of cases.

The cardinal sign was papilledema, although, albeit rarely, it might be absent or unilateral<sup>(11)</sup>. In this series, papilledema was identical with that in patients suffer other causes of increased ICP. In 99% of cases it was bilateral symmetrical, however it was asymmetric in 1% of cases.

It seems that symptoms worsen during pregnancy in 50% of patients and usually resolve postpartum<sup>(12)</sup>. In this series, about 1% of cases was pregnant and symptoms appeared in early pregnancy characterized by headache, blurred vision and pulsatile tinnitus.

Neuroimaging studies are usually normal, although, in some cases, they may demonstrate partially empty sella and perioptic CSF distension or small ventricles<sup>(13)</sup>. In this series, all cases were investigated by MRI, CT, and MRV on the brain. With detection of diagnostic signs such as flattened globes, thickened optic nerve sheath or empty sella in 15% cases, while in 85% of the cases usually no abnormalities were detected.

Therapeutic measures should be focused towards pre- serving visual function. Medical treatment includes diuretics (mainly acetazolamide), steroids, and serial lumbar punctures. **De Simone et al.**<sup>(14)</sup> suggested CSF drainage in increments of 20 mL. Symptoms may resolve even after a single lumbar puncture, but, if needed, the puncture can be repeated at intervals spaced over several weeks. Generally, the CSF is drained until the pressure falls to normal levels or below 20 mmHg<sup>(15)</sup>. In this series, Lumbar puncture in all cases done for both diagnostic and follow up purposes while used for therapeutic purpose in half (50%) of the patients.

A low- calorie diet or weight loss program, generally indicated in non-pregnant patients with IIH, may not be the recommendation of choice in the parturient because of the high nutritional requirements of the parturient and the developing fetus<sup>(16)</sup>. In this series, life style modification was used for both cases of frequent CSF tapping and of lumboperitoneal shunt especially by weight reduction and salt restriction except in pregnant patients.

### For group of frequent tapping of CSF

"Repeated LPs are sometimes used in patients with occasional symptom relapses, in

pregnant women, or in the setting of rapidly declining vision to temporarily lower the CSF pressure while planning a more aggressive treatment. However, the procedure may be painful, technically difficult to perform, and cause a low-pressure headache<sup>(17)</sup>. In this series, Volume around **20-30 ml** is drained at a time in each patient. In obese patients, the procedure was technically difficult. Low-pressure headache developed in most of the patients. Although the upright seated position is advantageous in that there is less distortion of spinal anatomy which allows for easier withdrawal of fluid but opening pressures are notoriously unreliable when measured in the seated position. Complications of lumbar puncture such as infection, tonsillar herniation, radiculopathy, and arachnoiditis were not encountered in any of cases.

**Medications used for this group included:**

**Acetazolamide:** We started with 0.5 to 1 g/d of acetazolamide in divided doses and gradually increased the dose until either symptoms and signs regress, side effects become intolerable, or a dose of 3 to 4 g/d is reached. Most patients responded to a dose of 1 to 2 g/d <sup>(18)</sup>. In this series, Acetazolamide: generally begun at a dose of 1 g/day given in divided doses of either 250 mg four times a day or 500-mg Sequels twice a day. Although allergy was a reported side effect of the drug, no cases in the study were found allergic to it. Potassium supplementation was used to avoid hypokalemia induced by acetazolamide

**Diuretics:** Furosemide had also been used to treat IIH, It had been well documented that furosemide can lower ICP. It appears to work by both diuresis and reducing sodium transport into the brain. We initiated with furosemide at a dose of 20 mg orally twice daily and gradually increased the dose, if necessary, to a maximum of 40 mg orally twice daily. Potassium supplementation was given as needed <sup>(19)</sup>. In this series, diuretics were used although they were not effective as acetazolamide and hypokalemia also was avoided by oral potassium supplementation.

**Topiramate:** Topiramate had also been used to treat IIH because it has carbonic anhydrase activity and weight loss commonly occurs. In studies to date, it appears comparable to acetazolamide <sup>(20)</sup>.

**Steroids:** Corticosteroids were not advocated for routine or long- term management of IIH. They were useful as an adjunctive treatment in patients with rapid deterioration while arranging a surgical procedure <sup>(21)</sup>. In this series, they were avoided in most of cases although they lower ICP acutely this was to avoid rebound increase in ICP after their withdrawal.

Patients in this group showed improvement of all symptoms in about 80% of patients. And in 20% of patients there were persistent complaints especially headache, blurred vision and progressive visual deterioration in all patients, there was no relation between the opening pressure and the degree of papilledema. Although visual acuity and color perception were generally preserved in papilledema unless it enters a chronic and atrophic stage visual fields and contrast sensitivity may be abnormal earlier <sup>(22)</sup>. In this series, Visual field was not affected in cases of acute papilledema on rapid management of the disease while in chronic papilledema there was affection in the visual field that usually showed improvement after control of the disease (after not less than 6 months of management).

**For group of lumbo-peritoneal shunt:**

"The revision rate for lumboperi- toneal shunts ranged from 38% to 64%, with an overall revision rate of 52% "<sup>(23)</sup>. In this series, 65% of Cases showed improvement of all symptoms, while 35% of cases showed shunt failure, and revision.

**CONCLUSION**

Idiopathic intracranial hypertension is not a single disease entity but rather a complex syndrome of variable presentations. According to its clinical presentation, it may be acute, sub acute, or chronic, and depending on the opening lumbar CSF pressure, it could be mild, moderate, severe, or fulminant. Surgery is often indicated for patients with failed medical treatment or medications intolerance, manometric predictors for surgical decision may include severe and fulminant opening CSF pressures as well as poor manometric response to repeated lumbar taps. Lumbo-peritoneal shunt is easy and effective for treating intractable headaches and visual impairment associated with IIH. Its usefulness can be optimized by appropriate patient selection and meticulous technical placement of the shunt guided by rigorous protocols for shunt procedures.

**REFERENCES**

1. **Friedman DI, Jacobson DM (2004):** Idiopathic intracranial hypertension. State of art. *J Neuro. Ophthalmol.* 24:138–145.
2. **Ball AK, Clarke CE (2006):** Idiopathic intracranial hypertension. *Lancet Neurol.* 5:433-442.
3. **Fung LW and Ganesan V (2004):** Arteriovenous malformations presenting with papilloedema. *Developmental medicine and child neurology*, 46(9):626-7.
4. **Schirmer CM, Hedges TR (2007):** Mechanisms of visual loss in papilledema, *Neurosurg Focus*, 23(5):E5.
5. **Çelebisoy N, Gökçay F, Sirin H *et al.* (2007):** Treatment of idiopathic intracranial hypertension: topiramate vs acetazolamide, an open-label study. *Acta Neurol Scand.*, 116:322-327.
6. **Garton JHL (2004):** Cerebrospinal fluid diversion procedures. *J Neuroophthalmol.*, 24:146-155.
7. **Friedman DI, Jacobson DM (2009):** Diagnostic criteria for idiopathic intracranial hypertension. *Neurology*, 59: 1492-5.
8. **Smith JL (1985):** Whence pseudotumor cerebri? *J Clin Neuro- ophthalmol.*, 5:55–56.
9. **Wall M (1990):** The headache profile of idiopathic intracranial hyper- tension. *Cephalalgia*, 10: 331-5.
10. **Giuseffi V, Wall M, Siegel PZ, Rojas PB (1991):** Symptoms and disease associations in idiopathic intracranial hypertension (pseudotumor cerebri): a case-control study. *Neurology*, 41: 239-44.
11. **Sher NA, Wirtschafter J, Shapiro SK, See C, Shapiro I (1983):** Unilateral papilledema in ‘benign’ intracranial hypertension (pseudotumor cerebri). *JAMA.*, 250: 2346-7.
12. **Bagga R, Jain V, Das CP *et al.* (2005):** Choice of therapy, mode of delivery in idiopathic intracranial hypertension during pregnancy. *MedGenMed.*, 7: 42.
13. **Brodsky MC, Vaphiades M (1998):** Magnetic resonance imaging in pseudotumor cerebri. *Ophthalmology*, 105: 1686-93.
14. **De Simone R, Ranieri A, Bonavita V (2010):** Advancement in idiopathic intracranial hypertension pathogenesis: focus on sinus venous stenosis. *Neurol Sci.*, 31(1): S33-9.
15. **Lee SW, Gates P, Morris P, Whan A, Riddington L (2009):** Idiopathic intracranial hypertension; immediate resolution of venous sinus “obstruction” after reducing cerebrospinal fluid pressure to 10cmH<sub>2</sub>O. *J Clin. Neurosci.*, 16: 1690-2.
16. **Huna-Baron R, Kupersmith MJ (2002):** Idiopathic intracranial hyper- tension in pregnancy. *J Neurol.*, 249: 1078-81.
17. **Corbett JJ, Thompson HS (1989):** The rational management of idiopathic intracranial hypertension. *Arch Neurol.*, 46:1049–51
18. **Tomsak RL, Niffenegger AS, Remler BF (1988):** Treatment of pseudotumor cerebri with Diamox (acetazolamide). *J Clin Neuro- ophthalmol.*, 8:93–98.
19. **Pollay M, Fullenwider C, Roberts PA, Stevens FA (1983):** Effect of mannitol and furosemide on blood-brain osmotic gradient and intracranial pressure. *J Neurosurg.*, 59:945–950.
20. **Celebisoy N, Gokcay F, Sirin H, Akyurekli O (2007):** Treatment of idiopathic intracranial hypertension: topiramate vs acetazolamide, an open-label study. *Acta Neurol Scand.*, 116:322–327.
21. **Liu GT, Glaser JS, Schatz NJ(1994):** High-dose methylprednisolone and acetazolamide for visual loss in pseudotumor cerebri. *Am J Oph- thalmol.*, 118:88–96.
22. **Rowe FJ, Sarkies NJ (1988):** Assessment of visual function in idiopathic intracranial hypertension: a prospective study. *Eye*, 12:111–8
23. **Eggenberger ER, Miller NR, Vitale S (1996):** Lumboperitoneal shunt for the treatment of pseudotumor cerebri. *Neurology*, 46:1524–30.