

Case report

Upper eyelid cutaneous leishmaniasis: exceptional and challenging location

Salem Bouomrani ^{1,2*}, Safa Trabelsi ¹

1- Department of Internal medicine, Military Hospital of Gabes, Gabes 6000, Tunisia.

2- Sfax Faculty of Medicine, University of Sfax, Sfax 3029, Tunisia.

CASE REPORT INFO

Case Report history:

Received 24 May 2020

Received in revised form 29 June 2020

Accepted 30 June 2020

Keywords:

Eyelid

Cutaneous leishmaniasis

Leishmaniasis

Eye.

ABSTRACT

Cutaneous leishmaniasis (CL) is one of the most endemic and neglected diseases worldwide, still representing an important public health problem. Its clinical presentations are very polymorphic and sometimes very difficult to diagnose. Among the variants described as “atypical” or “unusual”, eyelids CL is exceptional with a prevalence estimated at only 0.27-0.72% in large series. In most cases, eyelids leishmaniasis is skin-limited disease, but can exceptionally cause serious ocular complications and may lead to blindness.

We present an original case of isolated upper left eyelid CL in a 28-years-old Tunisian man. As rare as it is, this atypical clinical presentation of CL deserves to be well known by clinicians and discussed in front of any palpebral lesion which does not prove itself, in patient living or returning from a country endemic for this infection.

Introduction

Cutaneous leishmaniasis (CL) is a cosmopolitan parasitic infection [1-4]. However, it remains among the most neglected diseases and represents a real public health problem in several countries of the world [2,4], although its incidence is estimated at two million cases annually [2].

The most common features of CL are nodular, nodulo-ulcerative, and ulcero-crusted lesions [1-6]. However, the clinical presentation of this parasitosis is characterized by a large polymorphism (atypical shape or unusual site) [1,2,6] with so-called “atypical” and “unusual” forms [2,6,7].

The following forms of unusual/atypical CL have been described: lupoid, sporotricoid, eczematiform, verrucous, dry, zosteriform,

erysipeloid, psoriasiform, pseudotumoral, discoid lupus erythematosus-like, eyelids, squamous cell carcinoma-like, erythematous volcanic ulcer, paronychia, chancriform, and annular forms [2,6,7]. These forms are very challenging for clinicians, particularly those in the first line and in nonendemic areas [2].

Among these atypical/unusual presentations of CL, eyelids involvement is exceptional [8-10], and very difficult to diagnose in current medical practice [10].

We present an original case of isolated upper left eyelid CL in a 28-years-old Tunisian man.

Case report

A 28-years-old Tunisian man, without pathological medical history, was referred to our

DOI: 10.21608/MID.2020.99581

* Corresponding author: Salem Bouomrani

E-mail address: salembouomrani@yahoo.fr

department for nodular lesion of the upper left eyelid evolving for a month and non-responding to topical antibiotics.

Somatic examination noted isolated, nodular, crusted, 2 cm × 1 cm in diameter, and painless skin lesion located in upper left eyelid (**Figure 1&2**) without involvement of anterior eye structures (**Figure 3**). No other lesions or abnormalities were noted.

The basic biological tests were within normal limits: total blood count, erythrocyte sedimentation rate, C-reactive protein, fast glycaemia, creatinine, calcemia, serum ionogram, transaminases, muscle enzymes, uric acid, lipid parameters, thyroid hormones, and serum protein electrophoresis.

May Grunwald Giemsa-stained examination of a slit-skin smear taken from the palpebral lesion confirmed the diagnosis of CL by objectifying numerous Leishman bodies. Polymerase chain reaction from the lesion was positive for *L. major*.

Treated with intramuscular meglumine antimoniate at the dose of 60 mg/kg/day for 15 days, the evolution was favorable with complete disappearance of the lesion. No recurrence has been noted for four years.

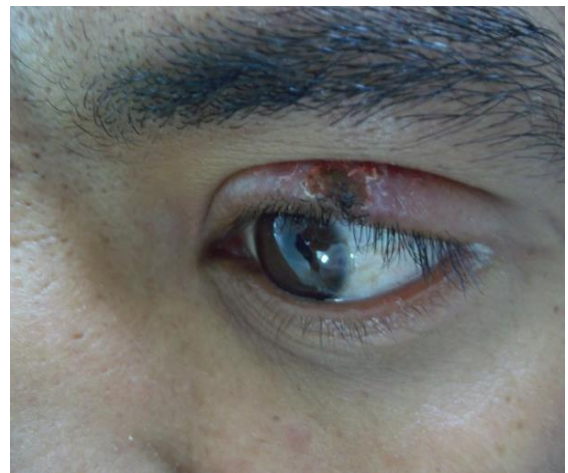
Figure 1. Isolated nodular and crusted lesion of the left upper lid.

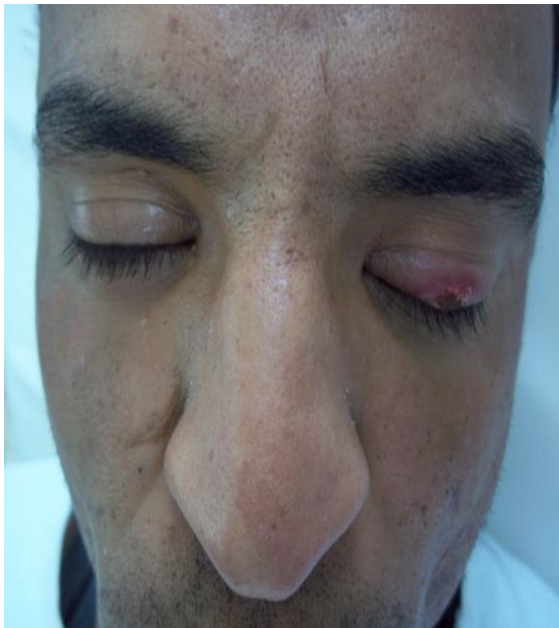

Figure 2. Erythematous and nodular lesion of the upper lid with central crust

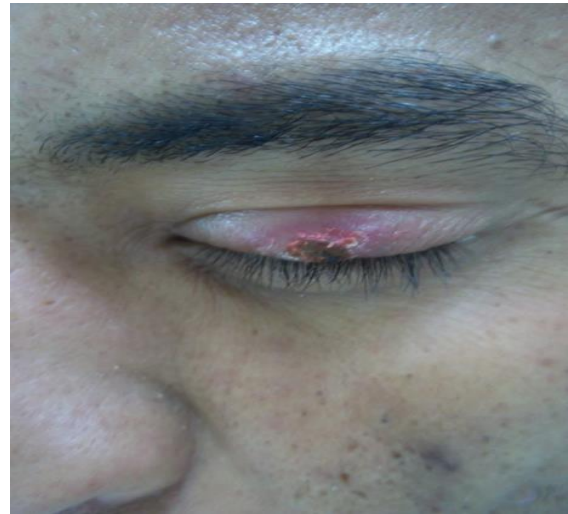

Figure 3. Cutaneous leishmaniasis of the left upper lid without involvement of the anterior segment of the eye.



Discussion:

Eyelids leishmaniasis is an exceptional and unusual clinical presentation of CL [8-10], often reported as sporadic clinical cases [11-16].

In large series of CL, its prevalence is estimated at 0.27-0.72% (only two cases in **Bari et al.** series of 718 patients with CL (0.27% of all CL and 4.9% of atypical CL) [7], and only 8 cases in **Afghani et al.** series of 925 patients with CL (0.72% of all CL and 4% of CL of the face) [17]. No case was found in **Raja et al.** series of 1709 patients with CL including 37 cases of very unusual lesions [18].

The rarity of this localization is mainly explained by the frequent movements of the eyelids which prevent the vector from biting and infecting the skin in this region [9,10].

The pathologic patterns of eyelids CL include superficial ulcerative lesion, nodulo-ulcerative lesion, nodular lesion, ulcero-crusted lesion, and plaque-like lesion [8-18], and clinically it may mimic chalazion, chronic granulomatous blepharitis, or infundibular cyst [8-11]. Rarely other aspects such as ulcerous, cancer-like, and phagedenic forms may be observed [10].

The lesion is typically unique, and the lateral canthus seems to be the most frequently affected part of the eyelids [8-10].

The palpebral LC can be uni- or bi-lateral [10,13], involve the upper or lower eyelids [8-10], isolated or associate with other sites of CL [8]. In most cases, eyelids leishmaniasis is skin-limited disease [10,17], but exceptionally infection can extend and involve other structures of the eye with serious ocular complications: conjunctivitis, keratitis, and uveitis [10,19], and may lead to blindness [10,16].

The differential diagnosis of eyelids CL can discuss chalazion, sarcoidosis, syphilis, tuberculosis (lupus vulgaris), histoplasmosis, dacryocystitis, epitheliomas, basal cell carcinoma, and eczema [8-17].

The treatment of eyelids CL is based on systemic (intramuscular) or local (intralesional injections) meglumine antimoniate, with a classically favorable recovery [8,10,13].

Conclusion

As rare as it is, this atypical clinical presentation of CL deserves to be well known by clinicians, particularly those in first line and exercising in endemic areas. The diagnosis of eyelid CL deserves to be discussed in front of any palpebral lesion which does not prove itself, in any patient living or returning from a country endemic for this infection.

This improved knowledge is the only guarantor of early diagnosis and appropriate management, in order to avoid serious complications and blindness.

Conflicts of interest: none

Financial disclosure: none

References

- 1-Mokni M. Cutaneous leishmaniasis. *Ann Dermatol Venereol* 2019; 146(3): 232-246.
- 2-Meireles CB, Maia LC, Soares GC, Teodoro IPP, Gadelha MDSV, da Silva CGL, et al.

Atypical presentations of cutaneous leishmaniasis: A systematic review. *Acta Trop* 2017; 172: 240-254.

- 3-Burnett MW. Cutaneous leishmaniasis. *J Spec Oper Med* 2015; 15(1): 128-129.
- 4-Hengge UR, Marini A. Cutaneous leishmaniasis. *Hautarzt* 2008; 59(8): 627-632.
- 5-Galluzzo CW, Eperon G, Mauris A, Chappuis F. Leishmaniose cutanée de l'Ancien Monde [Old World cutaneous leishmaniasis]. *Rev Med Suisse* 2013; 9(385): 990-995.
- 6-Remadi L, Haouas N, Chaara D, Slama D, Chargui N, Dabghi R, et al. Clinical Presentation of Cutaneous Leishmaniasis caused by *Leishmania major*. *Dermatology* 2016; 232(6): 752-759.
- 7-Bari A, Rahman SB. Many faces of cutaneous leishmaniasis. *Indian J Dermatol Venereol Leprol* 2008; 74: 23-7.
- 8-Hanafi Y, Oubaaz A. Leishmaniasis of the Eyelid Masquerading as a Chalazion: Case Report. *J Fr Ophtalmol* 2018; 41(1): e31-e33.
- 9-Ayatollahi J, Ayatollahi A, Shahcheraghi SH. Cutaneous leishmaniasis of the eyelid: a case report. *Case Rep Infect Dis* 2013; 2013: 214297.
- 10-Yaghoobi R, Maraghi S, Bagherani N, Raffei A. Cutaneous leishmaniasis of the lid: a report of nine cases. *Korean J Ophthalmol* 2010; 24(1): 40-43.
- 11-Veraldi S, Bottini S, Currò N, Gianotti R. Leishmaniasis of the eyelid mimicking an infundibular cyst and review of the literature on ocular leishmaniasis. *Int J Infect Dis* 2010; 14(Suppl 3): e230-e232.
- 12-Vinetz JM, Soong L. *Leishmania mexicana* infection of the eyelid in a traveler to Belize. *Braz J Infect Dis* 2007; 11(1): 149-152.

- 13-**Jafari AK, Akhyani M, Valikhani M, Ghodsi ZS, Barikbin B, Toosi S.** Bilateral cutaneous leishmaniasis of upper eyelids: a case report. *Dermatol Online J* 2006; 12(1): 20.
- 14-**Mencia-Gutiérrez E, Gutiérrez-Díaz E, Rodríguez-Peralto JL, Monsalve-Córdova J.** Old World eyelid cutaneous leishmaniasis: a case report. *Dermatol Online J* 2005; 11(3): 29.
- 15-**Sadeghian G, Nilfroushzadeh MA, Moradi SH, Hanjani SH.** Ocular leishmaniasis: a case report. *Dermatol Online J* 2005; 11(2): 19.
- 16-**Doroodgar M, Doroodgar M, Doroodgar A.** Eyelid Cutaneous Leishmaniasis: A Case Report. *Iran J Public Health* 2017; 46(2): 261-264.
- 17-**Afghani T, Mansoor H, Kiani SA, Mirza MA.** Prevalence of eyelid lesions in cutaneous leishmaniasis in Pakistan. *Community Eye Health* 2015; 28(91): S01-S3.
- 18-**Raja KM, Khan AA, Hameed A, Rahman SB.** Unusual clinical variants of cutaneous leishmaniasis in Pakistan. *Br J Dermatol* 1998; 139(1): 111-113.
- 19-**Bouomrani S, Farah A, Ayadi N, Béji M.** Bilateral chronic and granulomatous total uveitis following cutaneous leishmaniasis. *Med Mal Infect* 2011; 41(6): 344-5.

Bouomrani S, Trabelsi S. Upper eyelid cutaneous leishmaniasis: exceptional and challenging location. *Microbes Infect Dis* 2021; 2(4): 819-822.